



# World Journal of Laparoscopic Surgery

*An Official Publication of the World Association of Laparoscopic Surgeons, UK*

*Editors-in-Chief*

**RK Mishra (India)**

**Jiri PJ Fronek (UK)**



**WJOLS**

Also available online at  
[www.jaypeejournals.com](http://www.jaypeejournals.com)  
[www.wjols.com](http://www.wjols.com)

Access Online Resources



For more details, visit  
[www.wjols.com](http://www.wjols.com)

*Bibliographic Listings:*

ProQuest, Scopus, Journals Factor,  
EBSCO, Genamics JournalSeek, Emcare, HINARI, Embase,  
J Gate, Google Scholar, Ulrich, CiteFactor, SIS,  
OAJI, MIAR, SIF, COSMOS, ESJI, SJIF, SJR, IJIF, ICI



**JAYPEE** Jaypee Journals

In the forthcoming issue of the *World Journal of Laparoscopic Surgery*, we delve into a spectrum of groundbreaking studies and case reports that advance the frontiers of minimal access surgery (MAS). This editorial aims to highlight the pivotal findings and innovative techniques presented in this issue, underscoring their significance in enhancing surgical practices and patient outcomes across the globe.

The issue kicks off with a compelling study by Rekha Khyalappa and colleagues on the “Effectiveness of Simulation Training for Minimal Access Surgery in PG Students,” which underscores the critical role of simulation-based training in enhancing the skill set of postgraduate students in minimal access surgery (MAS). This study not only reaffirms the value of simulation in surgical education but also sets a benchmark for curriculum development in surgical training programs.

Jyotirmaya Nayak and his team’s work on “Laparoscopic Inguinal Hernia Repair for Children” marks a significant stride in pediatric surgery, presenting laparoscopy as a definitive approach for inguinal hernia repairs in children. Their experience from a tertiary care center provides invaluable insights into the procedural advancements and patient care strategies that are setting new standards in pediatric minimal access surgery.

Shamsul Bari’s study on the “Laparoscopic Management of Hepatic Hydatid Cyst” offers a comprehensive analysis of the technique’s efficacy and safety, based on experiences from a single institute. This work not only contributes to the growing body of evidence supporting laparoscopic management of complex hepatic conditions but also emphasizes the need for specialized training and expertise in such intricate procedures.

The debate on the necessity of prophylactic abdominal drainage postlaparoscopic colectomy for colon cancer is addressed in a meticulous propensity score-matched analysis by Le Huy Luu and colleagues. Their findings challenge conventional surgical practices and pave the way for evidence-based postoperative care strategies, minimizing patient discomfort and enhancing recovery.

Innovation in surgical techniques is exemplified by Patrick Okechukwu Igwe’s “Nebulizer Underwater Sealed Chest Tube Drain Assembly,” a novel approach that promises to revolutionize irrigation techniques in laparoscopy and endoscopy procedures. This innovation not only exemplifies the inventive spirit of the surgical community but also highlights the continuous pursuit of improving surgical outcomes and patient safety.

The issue also features a randomized controlled trial by Sachin Jain and his team on “Port-site Infiltration and Extraperitoneal Instillation of Ropivacaine in Totally Extraperitoneal Hernia Repair,” which provides evidence-based insights into pain management techniques that significantly enhance patient comfort and recovery.

A comparative study on “Laparoscopic vs Open Colorectal Surgeries in Urgent Surgical Situations” by Loay M Gertallah and colleagues provides critical data on the efficiency, safety, and outcomes of laparoscopic interventions in emergency settings, further solidifying the role of MAS in acute care scenarios.

The issue is enriched with a special research article by Syed Ali Haider and his team, offering a “Laparoscopic Surgery Practice in the Era of COVID-19: The Pakistani Perspective.” This timely piece reflects on the challenges and adaptations in MAS practices amidst the global pandemic, providing valuable lessons and resilience strategies for the surgical community worldwide.

Complementing the research articles are intriguing case reports, including rare presentations such as co-existent Classical Maydl’s and Amyand’s Hernias, complications postlaparoscopic total gastrectomy, Waltman Walter syndrome as a rare postcholecystectomy presentation, and the management of an abnormally located benign nerve sheath tumor laparoscopically. Each case report not only adds to the surgical literature with unique clinical scenarios but also emphasizes the critical role of MAS in diagnosing and managing rare and complex conditions.

This issue of the *World Journal of Laparoscopic Surgery* presents a tapestry of research that collectively advances our understanding, skills, and outcomes in minimal access surgery. It serves as a testament to the relentless pursuit of excellence in the surgical field, fostering a culture of innovation, education, and patient-centered care. We invite our readers to explore these articles in detail, as they offer valuable insights and inspiration for both current practice and future research in laparoscopic surgery.



**RK Mishra**  
Editor-in-Chief, WJOLS  
Chairman  
World Laparoscopy Hospital  
Gurugram, Haryana, India

# Effectiveness of Simulation Training for Minimal Access Surgery (MAS) in PG Students

Rekha Khyalappa<sup>1</sup>, Vaibhav Vimalnath Mudhale<sup>2</sup>, Suraj Dige<sup>3</sup>, Shubham Gupta<sup>4</sup>

Received on: 12 June 2023; Accepted on: 07 July 2023; Published on: 14 February 2024

## ABSTRACT

The use of simulation-based medical education and learning is one of the most crucial phases in curriculum development. A synthetic depiction of a real-world procedure used to accomplish educational objectives through hands-on learning is referred to as simulation. Any educational activity that uses simulation aids to mimic clinical circumstances is referred to as simulation-based medical education. Instead of studying like an apprentice, medical simulation enables the purposeful practice of clinical skills acquisition. Real patients can be substituted using simulation technologies. A trainee does not have to worry about hurting the patient in order to make errors and grow from them. Simulators come in a variety of forms and classifications, and their prices vary based on how closely they mimic reality, or "fidelity". The cost of simulation-based learning is high. But when used correctly, it's economical. It has been discovered that medical simulation improves clinical competency for both undergraduate and graduate students. It has also been discovered to have several benefits, including raising medical providers' competency levels, which can lower medical expenses and increase patient safety. This narrative review article's goal is to emphasize the value of simulation as a cutting-edge teaching strategy for graduate and undergraduate students.

**Keywords:** Clinical skills, Diagnostic laparoscopy, Laparoscopic, Medical education, Medical simulation, Surgery, Surgical Procedure, Simulators.

*World Journal of Laparoscopic Surgery* (2024): 10.5005/jp-journals-10033-1585

## INTRODUCTION

One of the medical specialties where expertise is crucial is general surgery. Laparoscopy surgery is now considered a fundamental skill. However, due to their greater complexity than open surgery, laparoscopic techniques are harder to learn. Additionally, more and more novel techniques are emerging. We are now able to train in a secure and controlled environment thanks to simulation, which is emerging as a complementary tool for the development of surgical skills. There is apprehension about practicing on actual patients, which takes time and can result in greater issues. Additionally, there is a greater demand for skill coordination, which calls for more repetition and practice. If we could begin training our Residents in our simulation lab early, it would boost their self-confidence and allow them to acquire superior abilities. Laparoscopic simulation-based training can therefore be more beneficial than training with actual patients. Today, simulators are frequently used in medical and surgical training.

Rapid modifications have been made to medical education worldwide in response to all of the present challenges.<sup>1,2</sup> Many factors contributed to these advances, such as changing population needs and the many scientific and technical advancements brought about by the evidence-based body of medical knowledge. Innovative approaches must be used since medical education is evolving and new educational paradigms are being established.<sup>3</sup> It has been demonstrated that a virtual reality simulator can enhance initial laparoscopic and minimally invasive surgery abilities as well as advanced suturing skills at the initial stage. Performance has been evaluated using pre-post training exams. These incidents are mostly related to medical education, which has to use the best teaching resources to transform inexperienced doctors. Pre- and post-training assessments have been used to assess performance. These phenomena are mostly related to medical education, which

<sup>1-4</sup>Department of Surgery, Dr DY Patil Medical College, Hospital and Research Institute, Kolhapur, Maharashtra, India

**Corresponding Author:** Vaibhav Vimalnath Mudhale, Department of Surgery, Dr. D. Y. Patil Medical College, Hospital and Research Institute, Kolhapur, Maharashtra, India, Phone: +91 9403465365, e-mail: dr.vaibhavmudhale.nursinghome@gmail.com

**How to cite this article:** Khyalappa R, Mudhale VV, Dige S, *et al.* Effectiveness of Simulation Training for Minimal Access Surgery (MAS) in PG Students. *World J Lap Surg* 2024;17(1):1-4.

**Source of support:** Nil

**Conflict of interest:** None

has to use the best teaching techniques to turn novice students into qualified experts. These constant disputes have made new and creative approaches to teaching, learning, and evaluation possible. Simulation facilitates risk-free learning in difficult, crucial, or uncommon circumstances and supports multidisciplinary and team-based learning strategies in the medical field. Furthermore, simulation can be useful in outcome evaluation and accreditation. Virtual reality refers to the computer simulation of various skills encountered in real life. The trainee reacts in a scenario with realistic elements that can be changed and adjusted as needed.

Simulation enables appropriate instruction and consistent evaluation of the skills needed to deal with an ever-shifting environment through supervised experiences in safe environments. We outlined the history and background of the clinical simulation in this paper, as well as described the present state of the art in this field and suggested future approaches. With patient care and public health as its ultimate goals, this study hopes to mold the next generation of health educators and professionals.

## The Past and Present of Simulation

Because imitation is ubiquitous in nature, simulation predates the existence of man. Jean Baudrillard argues that imitation has the potential to supplant reality. The first full-body simulator (called "Ms. Chase") was used at Hartford Hospital in 1911 to teach nursing skills.<sup>4,5</sup> In aviation instruction, the look of simulation is critical. During World War II, hundreds of pilots were trained with great success using the "Link Trainer" flying simulator.<sup>6</sup> These days, simulation is a key tool used by the aviation industry to train its employees and support the creation of strict safety regulations.<sup>7</sup> A simulator is more successful in practicing specific piloting maneuvers, and "no one could imagine using an aircraft to train today." Observing the procedures employed to decrease errors in aviation can reveal new alternatives for reducing medical errors in health.<sup>8</sup> Since the mid-twentieth century, various simulators for medical education have been developed, including the Resusci AnneTM, SimOneTM, NoelleTM, and SimManTM, which have enhanced the quality of simulated scenarios and also made them more realistic.

There are simulation centers across the globe, including simulated healthcare setups or virtual hospitals, that have similar equipment as real hospitals. This permits the requalification of professionals who are currently working with patients as well as the training of students. Along these lines, simulation has been considered as one of the fundamental aspects utilized in CME (Continuing Medical Education), with the goal of maintaining and improving previously learned abilities in situations comparable to those seen in real-world settings.<sup>9</sup> Being able to acquire "knowing," "knowing how to do," and "knowing how to be" abilities makes this methodology significantly superior to other approaches.<sup>10</sup>

It is possible to create safe, reproducible, standardized, regulated, and predictable simulation settings. Practise skills needed for rare scenarios, such as managing cardio-respiratory arrests, is made possible by the simulation. Moreover, the simulation situations may be run again until the desired degree of training is attained. When presented with a similar circumstance in clinical practice, this facilitates effective performance. It is feasible to train to a high degree by doing a skill repeatedly and receiving appropriate feedback. Simulations are not perfect and may not accurately represent reality. As a result, it is important to create a "fiction contract" and communicate with and guide the student so that this "lack of reality" does not affect future performance. Scenarios should be reviewed on a regular basis to ensure that they are still relevant.

The simulation creates realistic environments. Because powerful emotions are involved in psychologically safe and effective feedback situations, which together support long-term learning, this modality facilitates multimodal learning. This improves educational system efficiency in terms of costs and training time. Although the link between the two is not entirely clear, engaging emotions may help with long-term learning.<sup>11</sup> When compared to other methods of skill acquisition, emotional learning is more effective.<sup>12</sup> Modern simulation techniques come in a variety of forms, from part simulator training for specialized skills to immersive environments employing techniques like virtual reality, surgical simulation, and standardized patients to learn numerous and complicated abilities.<sup>13</sup> Gurusamy et al. have published an intriguing systematic review.

Hence, the study was undertaken to train first and second-year postgraduate students in laparoscopic skills so as to improve hand-eye coordination, train them for basic laparoscopic procedures like endo suturing, and give early exposure to basic/advanced laparoscopic procedures.

## METHODOLOGY

It was a cross-sectional study conducted at the Simulation lab of Dr DY Patil Medical College Hospital and Research Institute, which included all 20 Medical Residents from the General Surgery Department of the college. A Simulation-based module was used to teach and assess the use of early basic laparoscopic training for the duration of 1 year (2021–2022). The focus of this module was to make them aware of all the laparoscopic instruments and take care of them and train the residents in basic laparoscopic procedures such as camera navigation, clip application, cutting, and needle driving.

Three training sessions, each one month apart was conducted for all students focusing on simulation-based laparoscopic training, their progress was assessed in each session by training Faculty, and at the end of the training, the final assessment was done by a neutral laparoscopic-trained faculty other than the trainer on set parameters. Regular feedback from faculty and students was taken.

Laparoscopic training was done on Cae Healthcare LapVR including training sessions planning, hands-on education station, simulation-based training and assessment. The mode of Data collection was through a Standard performance sheet from the lab, DOPS, Feedback from faculty and students, and data was tabulated using paired-t test.

## OBSERVATIONS

Laparoscopic surgery training using virtual reality simulations gives the option of training without using actual patients. In addition to encouraging team-based and interdisciplinary learning approaches in the field of healthcare, simulation offers a way to learn without taking any risks in complex, important, or uncommon circumstances. Furthermore, accreditation and outcome evaluation are two areas where simulation can be very helpful. Virtual reality is the term used to describe the computer-based simulation of various real-world abilities. In a scenario that has elements that could be altered and adjusted to achieve the desired degree of performance, the trainee responds. As a result, virtual reality simulators offer a promising method for complicated laparoscopic surgery instruction. However, since the virtual reality simulation training involves time and money investment, its efficacy as a teaching method needs to be demonstrated. Residents, new surgeons, and surgeons with different levels of experience must learn the principles, get training in both basic and advanced laparoscopic procedures, or receive training in unusual scenarios in the context of minimally invasive surgery, a field that is still developing.

As a result, various levels of human behavior should be examined to determine the efficacy of virtual reality simulation training. Three stages of human behavior are identified by Rasmussen's model: knowledge-based, rule-based, and skills-based behavior.<sup>14</sup>

Skills-based behavior is concerned with actions by surgeons that happen automatically, such as moving the tools as a result of the fulcrum effect. A behavior dependent on skill is suturing. At this stage, box trainers or virtual reality simulators can be used for training. Task execution governed by rules or processes is considered rule-based behavior. The operation protocol, which specifies the procedure to be followed, is an example of a job at this level. For instance, prior to dividing the cystic duct and cystic artery during laparoscopic surgery, they must first be isolated



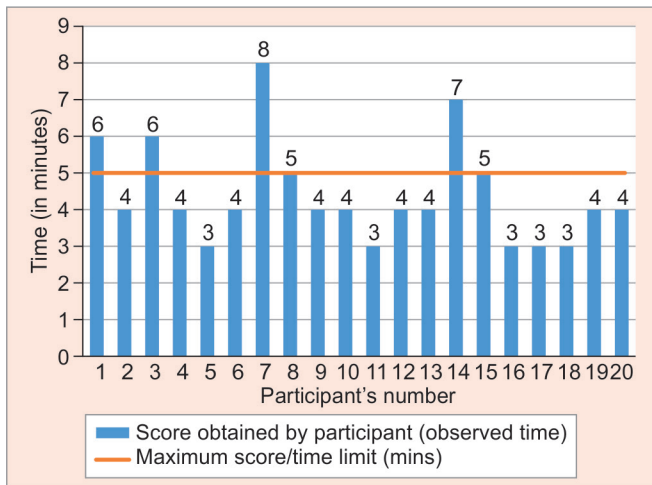


Fig. 1: Time for camera navigation

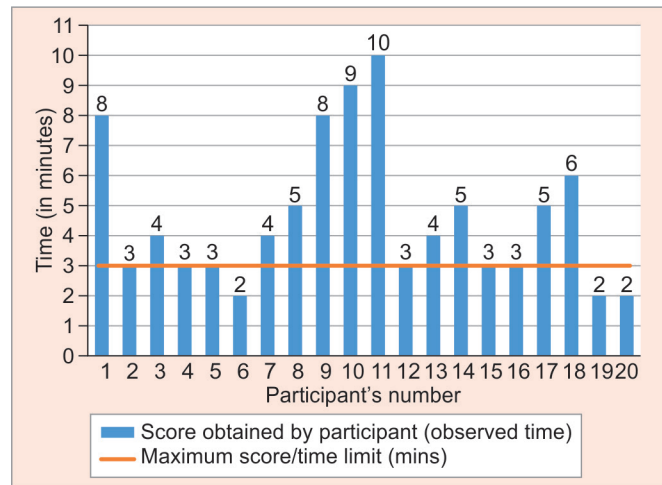


Fig. 2: Time for clip application

and recognized. Knowledge-based behavior addresses unfamiliar circumstances for which there are no established standards, such as internal bleeding and tissue damage.<sup>14</sup>

When it comes to surgical trainees with little to no prior experience, Gurusamy et al. interesting systematic review from three years ago looked at whether virtual reality simulator training can substitute or supplement traditional laparoscopic training. About 22 studies including 622 participants compared the use of virtual reality simulators with other training methods, including video trainers, no training, standard laparoscopic instruction, and other virtual reality training approaches. The authors came to the conclusion that video trainer training is at least as successful as virtual reality simulation training in terms of enhancing conventional surgical training.<sup>15</sup>

Hare calculated value of test statistic  $T$  ( $T = 1.93$ ) is greater than the table value of  $T$  at a 5% level of significance and 19 degrees of freedom (Table  $T = 1.73$ ). As a result, we find that there has been a considerable improvement in camera navigation skill ( $p$ -value = 0.03) and reject the null hypothesis ( $H_0$ ) and accept the alternative hypothesis ( $H_1$ ) (Fig. 1).

Hare calculated value of test statistic  $T$  ( $T = 2.96$ ) is greater than the table value of  $T$  at a 5% level of significance and 19 degrees of freedom (Table  $T = 1.73$ ). After rejecting the null hypothesis ( $H_0$ ) and accepting the alternative hypothesis ( $H_1$ ), we can thus infer that the clip application skill has significantly improved ( $p$ -value = 0.00) (Fig. 2).

Hare calculated value of test statistic  $T$  ( $T = 1.75$ ) is greater than the table value of  $T$  at a 5% level of significance and 19 degrees of freedom (Table  $T = 1.73$ ). After rejecting the null hypothesis ( $H_0$ ) and accepting the alternative hypothesis ( $H_1$ ), we may thus infer that cutting skill has significantly improved ( $p$ -value = 0.04) (Fig. 3).

Hare calculated value of test statistic  $T$  ( $T = 1.93$ ) is greater than the table value of  $T$  at a 5% level of significance and 19 degrees of freedom (Table  $T = 1.73$ ). Hence we reject the null hypothesis ( $H_0$ ) and accept alternative hypothesis ( $H_1$ ) and conclude that there is significant enhancement in needle suturing skill ( $p$ -value = 0.04) (Fig. 4).

From the Chi-square test conducted on the analyzed data in Table 1, the maximum time limit to complete the task was 5 minutes for the camera navigation procedure with a mean being 4.4 and a standard deviation is 1.39 with a corresponding  $p$ -value

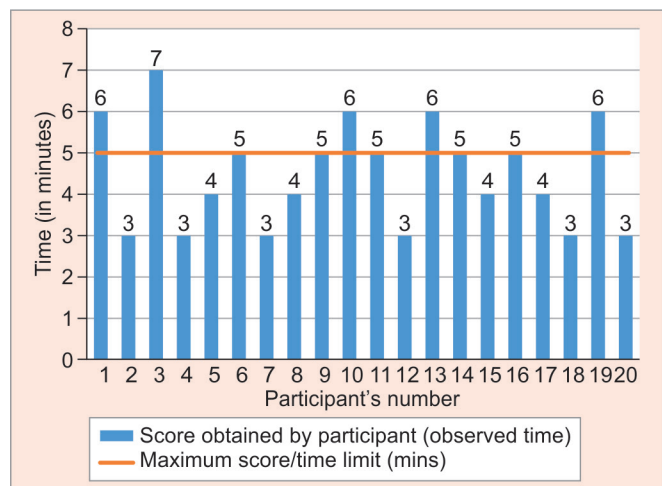


Fig. 3: Time for cutting

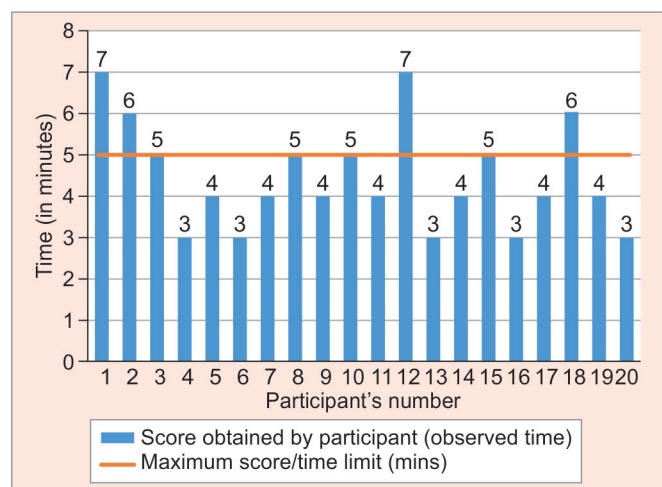


Fig. 4: Time for needle suturing

of 0.03 showing the significance of the pro-cure and concluding the effectiveness of the simulation-based training to the resident

**Table 1:** Chi-square test

<i>Time (in minutes) for</i>	<i>Mean</i>	<i>SD</i>	<i>Calculated value of T</i>	<i>Table value of T</i>	<i>p-value</i>	<i>Decision</i>
Camera navigation	4.4	1.39	1.93	1.73	0.03	Significant
Clip application	4.6	2.41	2.96	1.73	0.00	Significant
Cutting	4.5	1.28	1.75	1.73	0.04	Significant
Needle suturing	4.45	1.28	1.93	1.73	0.04	Significant

doctors. The maximum time was 3 minutes for the clip application procedure; for which the mean value was found to be 4.6 with the standard deviation being 2.41 and  $p$ -value obtained was 0.00, which again showed the effectiveness of training the respective procedure.

The time limit given for 5 minutes for cutting procedure was 5 minutes and the mean obtained was 4.5, standard deviation calculated was 1.28, and the effectiveness of this technique was found to be significant with  $p$ -value being 0.04 respectively. The last procedure was needle suturing skills for which the given time was 5 minutes respectively, the calculated mean and standard value for the given procedure were 4.45–1.28 respectively and the effectiveness of this skill was also found out to be significant with the  $p$ -value being 0.04.

Thus, we may conclude that virtual reality models constitute a new paradigm in surgical education and that it is essential that postgraduate general surgery students learn the principles of laparoscopic surgery using these simulations. Future research should, however, concentrate on the following areas: How virtual reality simulation training affects performance during complex laparoscopic procedures; how it influences knowledge-based behavior; how it affects patient outcomes; how standardizing virtual reality simulation training is necessary; and whether using it in conjunction with other training techniques can have synergistic effects.

## CONCLUSION

Laparoscopic surgical training using simulation has many benefits, including being a risk-free environment for the patient; providing novice training in a variety of cases with high complexity; providing instant feedback on the training tasks; being ethically acceptable because the training is not carried out on real patients; being useful in identifying the right people who will develop into technically competent surgeons; and being helpful for credentialing.

Due to the rising demand for advanced laparoscopic complicated surgery with an adaptation of innovative techniques, the clinical training curriculum for surgeons should include laparoscopic VR simulators through an integrated evidence-based, simulation-based education program.

## ACKNOWLEDGMENT

The author would like to thank all the professors, guides, and heads of the departments for giving their valuable guidance during his research. Also, would like to thank all the faculty members of Seth GSMC KEM Nodal Centre, Mumbai for their guidance and support throughout the project. We would also like to thank skill lab team, friends and family for their constant encouragement and support during the research period.

## Data Availability

The dataset generated during the current study is available in with Dr. Rekha Khyalappa (repository). The dataset generated during the research is not publicly available. However, it can be made available from the corresponding author on reasonable request.

## REFERENCES

- Norrell K, Marasigan J, Bogener J. New paradigms in post-graduate surgical education. *Mo Med* 2017;114(4):278–282. PMID: 30228611.
- Daneman D, Benatar S. Dynamic tensions following new pedagogy in undergraduate medical education. *Acad Med* 2019;94(12):1873–1877. DOI: 10.1097/ACM.0000000000002795.
- Mehta NB, Hull AL, Young JB, et al. Just imagine. *Acad Med* 2013;88(10):1418–1423. DOI: 10.1097/ACM.0b013e3182a36a07.
- Nickerson M, Pollard M. Mrs. Chase and her descendants: A historical view of simulation. *Creat Nurs* 2010;16(3):101–105. DOI: 10.1891/1078-4535.16.3.101.
- Aebersold M. Simulation-based learning: No longer a novelty in undergraduate education. *OJIN* 2018;23(2):1–1. DOI: 10.3912/OJIN.Vol23No02PPT39.
- ASME International. The link flight trainer. A historic mechanical engineering landmark. Roberson Museum and Science Center, Binghamton, NY; 2020. p. 20.
- Kohn L, Corrigan J, Molla D (Eds). *To Error Is Human: Building a Safer Health System*. Committee on Health Care in America. Institute of Medicine, Washington, DC: National Academy Press; 2000.
- Imach S, Eppich W, Zech A, et al. Applying principles from aviation safety investigations to root cause analysis of a critical incident during a simulated emergency. *Simul Healthc* 2020;15(3):193–198. DOI: 10.1097/SIH.0000000000000457.
- Khanduja PK, Bould MD, Naik VN, et al. The role of simulation in continuing medical education for acute care physicians: A systematic review. *Crit Care Med* 2015;43(1):186–193. DOI: 10.1097/CCM.0000000000000672.
- Cook DA, Hatala R, Brydges R, et al. Technology-enhanced simulation for health professions education: A systematic review and meta-analysis. *JAMA* 2011;306(9):978–988. DOI: 10.1001/jama.2011.1234.
- Tyng CM, Amin HU, Saad MN, et al. The influences of emotion on learning and memory. *Front Psychol* 2017;8:1454. DOI: 10.3389/fpsyg.2017.01454.
- Steadman RH, Coates WC, Huang YM, et al. Simulation-based training is superior to problem-based learning for the acquisition of critical assessment and management skills. *Crit Care Med* 2006;34(1):151–157. DOI: 10.1097/01.CCM.0000190619.42013.94.
- Sainsbury B, Lacki M, Shahait M, et al. Evaluation of a virtual reality percutaneous nephrolithotomy (PCNL) surgical simulator. *Front Robotics AI* 2020;6:145. DOI: 10.3389/frobt.2019.00145.
- Wentink M, Stassen LP, Alwayn I, et al. Rasmussen's model of human behavior in laparoscopy training. *Surg Endosc* 2003;17(8):1241–1246. DOI: 10.1007/s00464-002-9140-z.
- Gurusamy KS, Aggarwal R, Palanivelu L, et al. Virtual reality training for surgical trainees in laparoscopic surgery. *Cochrane Database Syst Rev* 2009;(1):CD006575. DOI: 10.1002/14651858.CD006575.pub2.

# Laparoscopic Inguinal Hernia Repair for Children is the Final Frontier: Experience from a Tertiary Care Center

Jyotirmaya Nayak<sup>1</sup>, Ashish Kumar Behera<sup>2</sup>, Rupashree Sahoo<sup>3</sup>

Received on: 20 August 2023; Accepted on: 15 September 2023; Published on: 14 February 2024

## ABSTRACT

**Background:** Pregnancy-induced hypertension (PIH) has been conventionally managed by open surgery and herniotomy which is the standard of care. But in the era of minimal access surgery, laparoscopic surgery for pediatric inguinal hernia has emerged as an alternative and is being routinely performed at many centers. Laparoscopic herniotomy is a safe and feasible option for pediatric inguinal hernia in present times. It has shown results similar to well-performed conventional herniotomy procedure with respect to marked reduction in operative time, and postoperative complications, postoperative pain, postoperative hospital stay, low rate of recurrence, no testicular atrophy, no iatrogenic ascent of testis, no postoperative hydrocele formation and excellent cosmesis. It provides a superior tool to diagnose contralateral patency of processus vaginalis (CPPV) or rare hernias that can be managed in the same session with minimal dissection, lesser postoperative complications, and better cosmesis thus favoring its wider adoption among surgeons globally in management of pediatric inguinal hernia.

**Method:** Data for all elective cases of PIH who underwent initial laparoscopic herniotomy repair in routine operation theater at our tertiary care center, during the period from 1st March 2010 to 1st March 2023 have been collected.

**Results:** A total of 53 laparoscopic inguinal herniotomies were performed on 50 patients. The median age of patients at the date of operation was 6.2 years. Of all patients, 47 cases were unilateral and 3 were bilateral inguinal hernias (IHs).

**Conclusion:** Laparoscopic inguinal herniotomy is a technically easier and safer technique than conventional open methods as there is no need for dissection of vas deferens and vessels. Laparoscopic herniotomy allows for the excellent visualization of cord structures and their proper safeguarding during the procedure. Simultaneous identification of CPPV in cases of unilateral IH and its repair reduces the risk of metachronous hernia as well. Less postoperative pain, early recovery, and better cosmesis make laparoscopic surgery the final frontier in the management of PIH, thus cementing its role as a viable and probably a better alternative to conventional repair.

**Keywords:** Herniotomy, Inguinal hernia, Laparoscopic.

*World Journal of Laparoscopic Surgery* (2024): 10.5005/jp-journals-10033-1600

## INTRODUCTION

The occurrence of inguinal hernia (IH) is a common surgical condition seen in infants and children, with prevalence rates varying from 1 to 4% in full-term neonates and reaching as high as 30% in preterm neonates.<sup>1-3</sup> Approximately 33% of IHs manifest before to 6 months of life, with males exhibiting an incidence rate almost 5–10 times higher than that of girls.<sup>1</sup> Contrary to expectations, the incidence of right-sided IHs is higher compared to left-sided hernias, even if bilateral hernias are present in 15–20% of children.<sup>1,4</sup> Inguinal hernia repair is a commonly performed surgical procedure that is now favored by doctors owing to its widespread occurrence.

Presently, there is ongoing research and development focused on a variety of treatments and techniques for the correction of hernias in infants and children. The current method of therapy for pediatric inguinal hernia involves the use of open surgery and herniotomy.<sup>5</sup> Nevertheless, in the era of restricted access surgery, laparoscopic surgery for pregnancy-induced hypertension (PIH) has emerged as a feasible alternative and is now routinely performed in several healthcare facilities worldwide. The use of laparoscopic ilio-pubic tract repair has been observed as a potential treatment option for cases of recurrence subsequent to laparoscopic ring closure.<sup>6</sup>

In the last 20 years, laparoscopy has gained significant recognition as both a diagnostic tool and a feasible treatment approach for managing IHs in young individuals.<sup>7</sup>

The technique of purse-string suture closure of the internal inguinal ring using sutures was first documented in a publication

<sup>1-3</sup>Department of Surgery, Srirama Chandra Bhanja Medical College and Hospital, Cuttack, Odisha, India

**Corresponding Author:** Jyotirmaya Nayak, Department of Surgery, Srirama Chandra Bhanja Medical College and Hospital, Cuttack, Odisha, India, Phone: +91 9438037714, e-mail: drjmnayak@gmail.com

**How to cite this article:** Nayak J, Behera AK, Sahoo R. Laparoscopic Inguinal Hernia Repair for Children is the Final Frontier: Experience from a Tertiary Care Center. *World J Lap Surg* 2024;17(1):5–8.

**Source of support:** Nil

**Conflict of interest:** None

in 1993. Subsequently, other modifications and alternatives to the therapeutic approach have been proposed, all aimed at the objective of excising the patent processus vaginalis in cases with IH.<sup>5</sup>

Laparoscopic herniotomy has emerged as a viable and secure therapeutic approach for the management of pediatric inguinal hernia. The results obtained are comparable to those achieved by proficient implementation of conventional herniotomy procedures. Advocates of the laparoscopic technique for hernia repair assert comparable efficacy to the open approach, accompanied by several supplementary advantages. These include notable reductions in operative duration, complications, pain, and hospitalization, as well as a low incidence of hernia recurrence, absence of testicular atrophy, iatrogenic ascent of the testis, and hydrocele formation.<sup>8</sup> Furthermore, the laparoscopic approach yields favorable cosmetic

outcomes. According to the cited source, laparoscopic surgery facilitates the identification of direct hernias. The utilization of this tool in the diagnosis of contralateral patency of the processus vaginalis (CPPV) or uncommon hernias, which can be effectively treated in a single session with minimal dissection, reduced complications, and improved cosmetic outcomes, has positioned it as a highly effective method for surgeons globally when managing pediatric inguinal hernia. In this study, we provide a retrospective review of our experience using laparoscopic herniotomy in pediatric patients at a tertiary care hospital.

## AIM AND OBJECTIVE OF THE STUDY

### Primary Objective

To perform a retrospective observational study on the prospectively collected data of pediatric patients who underwent laparoscopic IH repair (herniotomy) in the Department of general surgery, S.C.B. Medical College and Hospital between 1st March 2010 and 1st March 2023.

**Study type:** Retrospective observational study.

**Time period of study:** 1st March 2010 to 1st March 2023.

**Place of study:** Post Graduate Department of General Surgery, S.C.B. Medical College, Cuttack, Odisha, India.

**Sample size:** 50.

### Patient Selection

We retrospectively reviewed our elective surgery registry for all elective cases of PIH who underwent initial laparoscopic herniotomy repair in routine operation theater at our tertiary care center between 1st March 2010 and 1st March 2023 as per standard 3 port technique.

### Data Collection

Data on all laparoscopic herniotomies performed as elective cases in the routine operation theatre of S.C.B. Medical College and Hospital, Cuttack, from March 1, 2010 to March 1, 2023, were collected for this retrospective observational study.

Age, gender, body weight, associated co, site (unilateral or bilateral), duration of symptoms, history of any previous abdominal/surgery, findings on ultrasound of bilateral inguinoscrotal region, total duration of surgery (from placement of first port to taking last suture), operative findings, all operative events or complications, and total duration of hospital stay were all included in the data.

## METHOD

From March 1, 2010 to March 1, 2023, 50 patients with IH underwent laparoscopic herniotomy (LH) at our facility (46 men and 4 females). Parents were told about the many sorts of surgeries available and were offered laparoscopic surgery for their kid if they so wished. Under general anesthesia, all laparoscopic operations were conducted with the patient supine. For all patients, a pneumoperitoneum of 6–10 mm Hg was produced using Hasson's method via the first implanted infra umbilical trocar. (Fig. 1) The peritoneal cavity was visualized using a 5-mm telescopic camera. 3 or 2-mm triangulation tools were employed to close the inner inguinal ring. The deep inguinal rings on both sides were visualized after the ports were placed, and the inguinal hernia was detected. The sac was meticulously dissected from the chord structures (Fig. 2). Using a standard open surgery needle holder, a 3-0 suture

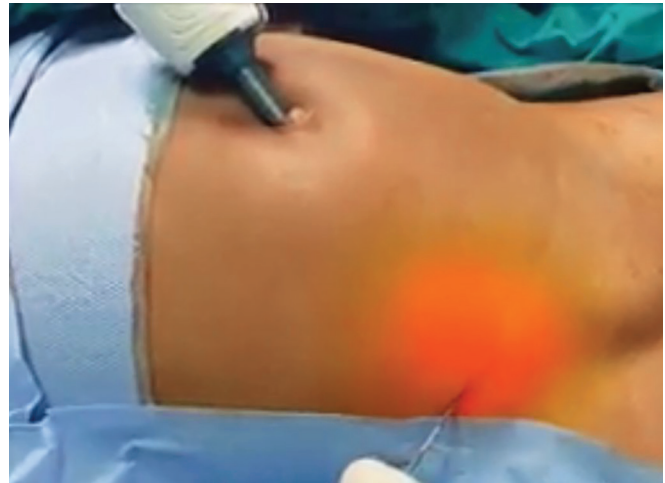

Fig. 1: Umbilical port placement

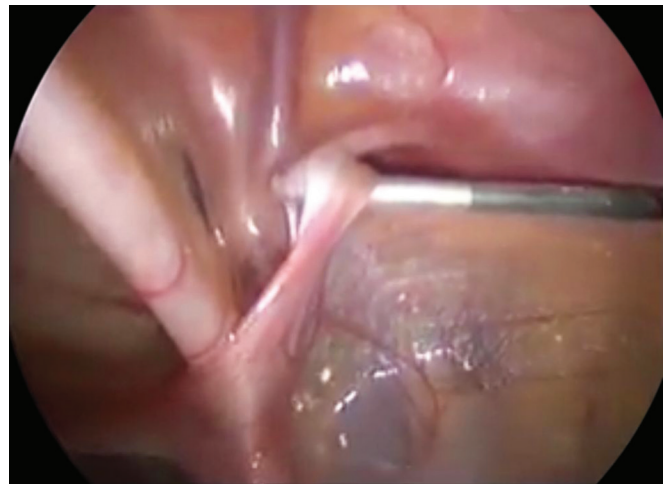

Fig. 2: Sac dissection

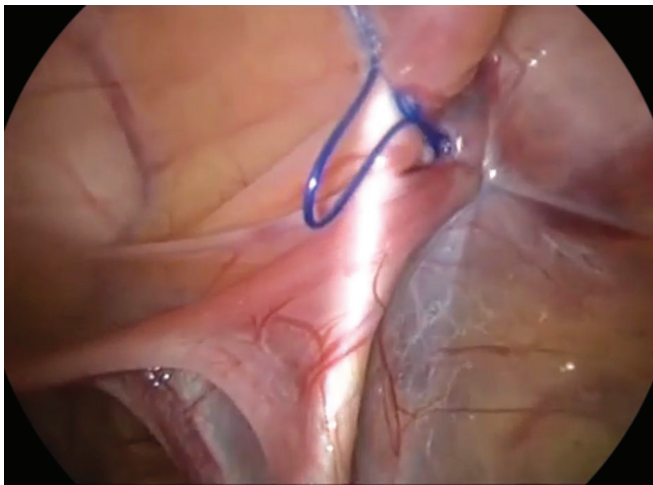
was cut to 8–12 cm and put straight through the abdominal wall adjacent to the internal inguinal ring. A purse string suture was used to seal the sac at the internal inguinal ring (Fig. 3). After the surgery was finished, we withdrew the two 5-mm operating ports and subsequently the umbilical camera port. The interventions were carried out in a 1-day surgical context using the following postoperative analgesic scheme: paracetamol 15 mg/kg iv, which was then repeated every 6 hours.

We utilized the Face, Legs, Activity, Cry (FLACC) scale to measure pain in children under the age of three. Children above the age of three were evaluated for pain duration using the Wong-Baker scale. Pain evaluation was completed at the end of the operating room, 2 hours, 6 hours, and at the end of the hospital stay. Outpatient department visits were scheduled 1 week, 3 months, and 6 months following the procedure.

## RESULTS

In all, 53 laparoscopic procedures were done on 50 patients. At the time of the procedure, the median age of the patients was 6.2 years. There were 47 unilateral and 3 bilateral IHs among all patients. The median surgical periods for unilateral and bilateral





**Fig. 3:** Ligation of sac

laparoscopic herniotomies were 76 and 118 minutes, respectively. The average operational time for unilateral repair was 3415.3 minutes, and 49.59.4 minutes for bilateral surgery. In 50 patients, a diagnosis of unilateral IH was made. In three of these patients (6%), laparoscopy showed a patent internal inguinal ring. Pain management was good in all patients. In 53 laparoscopic herniotomies, there were no recurrences. There were no further postoperative problems such as hydrocele, iatrogenic, testicular atrophy, or wound infection.

## DISCUSSION

The surgical correction of IHs is a commonly performed surgery in pediatric patients. The increased use of laparoscopic inguinal hernia repair may be attributed to the advancements made in the examination of the asymptomatic contralateral side since its introduction in the 1990s.<sup>4</sup> The advantages of this method include improved cosmetic outcomes, faster recovery times, less reliance on oral pain medications, enhanced visualization of anatomical structures, and the ability to identify and repair a contralateral patent processus vaginalis. Conversely, medical professionals who advocate for traditional open surgery express significant opposition against laparoscopic herniotomy, citing concerns over the augmented costs and duration associated with this particular approach. The rectification of the contralateral defect was performed concurrently during the surgical procedure, hence mitigating the potential occurrence of herniation in the future. The risk of injury to the vas deferens and blood arteries is significantly elevated in male infants who are less than 1 year old, since these anatomical structures are quite small and a delicate hernia sac is tightly attached to them. No postoperative complications, such as hydrocele, iatrogenic injury, testicular atrophy, or wound infection, were seen in any of the surgeries performed at our hospital.

All therapies were conducted inside a singular day of surgical procedures, using an identical postoperative analgesic approach. The laparoscopic technique, in contrast to the traditional approach, is a transperitoneal surgical procedure that has inherent risks. However, when managed by skilled professionals, these risks are substantially mitigated.

The preferred approach for repairing IHs in pediatric patients has traditionally been the open procedure, including the high ligation of the patent processus vaginalis.<sup>9</sup> This technique has

shown a good success rate and a low incidence of complications. In this study, we aim to investigate the effects of a new drug on patients with a nevertheless, the laparoscopic approach has emerged as a potential option because of its ability to address the limits and dangers involved with the aforementioned therapy. To start, it is important to note that herniotomy has inherent dangers, including iatrogenic complications, testicular shrinkage, and potential injuries to the vas deferens or artery. The prevalence of complete atrophy, for instance, may reach levels as significant as 0.3–3%. In this study, we aim to investigate the effects of a specific treatment on a particular population. While the aforementioned dangers are not limited only to the open procedure, they exhibit a significant occurrence rate of 2.7% after open hernia surgery, in contrast to the rate of 0.9% seen in laparoscopic hernia repair. Furthermore, it should be noted that open herniotomy procedures do not provide the opportunity to examine the contralateral internal inguinal ring for the presence of a hernia or patent processus vaginalis. It is worth mentioning that these conditions may be seen in about 56% of infants and children up to 2 years old, as well as in 40% of children older than 2 years, during the surgical intervention. Specifically in order to mitigate these concerns, several surgeons choose to do contralateral inguinal exploration as part of the open repair procedure, especially in babies between the ages of 1 and 2 years. Alternatively, some surgeons choose to conduct diagnostic laparoscopy via an umbilical incision or directly into the open hernia sac. According to a meta-analysis, the inclusion of laparoscopic inspection of the contralateral inguinal ring resulted in a little increase of 6 minutes in surgical duration. However, this procedure demonstrated a high level of sensitivity (99.4%) and specificity (99.5%) in detecting a patent processus vaginalis.<sup>10</sup>

Minimally invasive surgery has emerged as a viable and effective option for pediatric surgical treatment across a diverse spectrum of disorders and procedures, ensuring both safety and success. Laparoscopy is said to provide several advantages compared to open surgery, such as improved visualization, expedited recovery, reduced hospital stay, decreased painkiller use, diminished complications, and enhanced cosmetic outcomes. Laparoscopy has the additional benefit of facilitating straightforward viewing and assessment of the contralateral inguinal ring during the surgical correction of IHs.<sup>1,11</sup> Several new laparoscopic methods have been developed for the treatment of pediatric inguinal hernia, taking use of the numerous advantages associated with this approach.

The primary objective of various laparoscopic herniotomy techniques is to excise the patent processus vaginalis. The first technique described by Esposito and Montupet used the use of a purse-string suture to close the peritoneum at the internal inguinal ring. In 1998, Schier introduced a comparable methodology<sup>12</sup> which included the use of a series of sutures in the form of either “N” or “Z” across the internal inguinal ring. In 1999, Esposito introduced a modification in which the peritoneum located laterally to the internal inguinal ring was incised before to the placement of the purse-string suture.<sup>1,12,13</sup> Becmeur et al. subsequently proposed a technique that replicated each stage of the traditional open operation, including the excision of a portion of the patent processus vaginalis.<sup>14</sup> In the year 2011, Wheeler et al. conducted a study wherein they recorded the procedure of creating a peritoneal incision around the internal inguinal ring, followed by its closure using a purse-string suture.<sup>15</sup> Various techniques have been reported in the literature for the management of hernia sac during surgery. These techniques include the use of specialized awls or needles to

facilitate suture transfer across the hernia sac, as well as methods such as hydro dissection and the use of microincisions for ligating the sac. The success rates of these approaches exhibit variability contingent upon the laparoscopic skills and surgical expertise of the practitioner, yet demonstrating comparability to the open approach with success rates ranging from 95 to 100%.<sup>9,16</sup>

Despite the acknowledged benefits, shown equivalence to open surgery, and increasing use by juvenile general surgeons, the integration of laparoscopic herniotomy into the repertoire of pediatric surgeons has been met with caution.

## CONCLUSION

When performed in babies and children to repair an indirect hernia (i.e., patent processus vaginalis), laparoscopic herniotomy is both safe and successful. It is a safer procedure than the traditional open method since there is no need for vas deferens and vascular dissection. It enables great visualization of chord structures as well as their optimal protection throughout the treatment. In situations of unilateral IH, simultaneous diagnosis of patent processus vaginalis and treatment minimizes the likelihood of metachronous hernia.<sup>13</sup> There were no intraoperative problems. Despite its low use rate among pediatric surgeons to date, laparoscopic hernia repair is a well-established option to open surgery, particularly when double IHS are present or there is worry for a potential patent processus vaginalis. Less discomfort, faster recovery, and improved outcomes make it the ultimate frontier in the treatment of pediatric inguinal hernia, solidifying its position as a viable and likely superior option to traditional repair.

## ORCID

Jyotirmaya Nayak  <https://orcid.org/0000-0003-0452-3522>

## REFERENCES

1. Van Batavia JP, Tong C, Chu DI, et al. Laparoscopic inguinal hernia repair by modified peritoneal leaflet closure: Description and initial results in children. *J Pediatr Urol* 2018;14(3):272.e1–272.e6. DOI: 10.1016/j.jpuro.2018.02.015.
2. Esposito C, Escolino M, Turrà F, et al. Current concepts in the management of inguinal hernia and hydrocele in pediatric patients in Laparoscopic Era. *Semin Pediatr Surg* 2016;25(4):232–240. DOI: 10.1053/j.sempedsurg.2016.05.006.
3. Ein SH, Njere I, Ein A. Six thousand three hundred sixty-one pediatric inguinal hernias: A 35-year review. *J Pediatr Surg* 2006;41(5):980–986. DOI: 10.1016/j.jpedsurg.2006.01.020.
4. Shcheben'kov MV. The advantages of laparoscopic inguinal herniorrhaphy in children. *Vestn Khir Im II Grek* 1997;156(1):94–96. PMID: 9163206.
5. Palanivelu C. Laparoscopic pediatric hernia repair. In: *Operative Manual of Laparoscopic Hernia Surgery*. Coimbatore, India: Gem Foundation; 2004; pp. 195–205.
6. Schier F. Laparoscopic surgery of inguinal hernias in children—Initial experience. *J Pediatr Surg* 2000;35(9):1331–1335. DOI: 10.1053/jpsu.2000.9326.
7. Schier F. Direct inguinal hernia in children: The laparoscopic aspect. *J Pediatr Surg* 2000;16(8):562–564. DOI: 10.1007/s003830000431.
8. Davies DA, Rideout DA, Clarke SA. The International Pediatric Endosurgery Group Evidence-based guideline on minimal access approaches to the operative management of inguinal hernia in children. *J Laparoendosc Adv Surg Tech A* 2020;30(2):221–227. DOI: 10.1089/lap.2016.0453.
9. Alzahem A. Laparoscopic versus open inguinal herniotomy in infants and children: A meta-analysis. *Pediatr Surg Int* 2011;27(6):605–612. DOI: 10.1007/s00383-010-2840-x.
10. Mahmood B, Christoffersen M, Miserez M, et al. Laparoscopic or open paediatric inguinal hernia repair—A systematic review. *Dan Med J* 2020;67:A12190725. PMID: 32734885.
11. Schier F, Montupet P, Esposito C. Laparoscopic inguinal herniorrhaphy in children: A three-center experience with 933 repairs. *J Pediatr Surg* 2002;37(3):395–397. DOI: 10.1053/jpsu.2002.30842.
12. Arregui ME, Navarrete J, Davis CJ, et al. Laparoscopic inguinal herniorrhaphy—Techniques and controversies. *Surg Clin North Am* 1993;73(3):513–527. DOI: 10.1016/s0039-6109(16)46034-2.
13. Esposito C, Montupet P. Laparoscopic treatment of recurrent inguinal hernia in children. *Pediatr Surg Int* 1998;14(3):182–184. DOI: 10.1007/s003830050481.
14. Becmeur F, Philippe P, Lemandat-Schultz A, et al. A continuous series of 96 laparoscopic inguinal hernia repairs in children by a new technique. *Surg Endosc* 2004;18(12):1738–1741. DOI: 10.1007/s00464-004-9008-5.
15. Wheeler AA, Matz ST, Schmidt S, et al. Laparoscopic inguinal hernia repair in children with transperitoneal division of the hernia sac and proximal purse string closure of peritoneum: Our modified new approach. *Eur J Pediatr Surg* 2011;21(6):381–385. DOI: 10.1055/s-0031-1291181.
16. Miltenburg DM, Nuchtern JG, Jaksic T, et al. Laparoscopic evaluation of the pediatric inguinal hernia – A meta-analysis. *J Pediatr Surg* 1998;33(6):874–879. DOI: [https://doi.org/10.1016/S0022-3468\(98\)90664-9](https://doi.org/10.1016/S0022-3468(98)90664-9).

# Laparoscopic Management of Hepatic Hydatid Cyst: A Single Institute Based Experience

Shamsul Bari<sup>10</sup>

Received on: 21 September 2022; Accepted on: 20 February 2023; Published on: 14 February 2024

## ABSTRACT

**Background:** Various modalities of treatment for hydatid cyst of liver include drug therapy, conventional open surgery and laparoscopic surgery. Laparoscopic approach is preferred in view of its minimal invasiveness, short hospital stay, early recovery, and lesser wound-related complications.

**Aims and objectives:** To study the safety and feasibility of laparoscopic surgery in hydatid disease of liver in selected patients.

**Materials and methods:** The study entitled, "laparoscopic management of hepatic hydatid cyst—A single institute-based experience" was conducted in the Department of General and Minimal Invasive Surgery SKIMS Medical College Bemina, Srinagar, Kashmir, India from November 2019 to August 2021 with a further follow-up for a period of 1 year from September 2021 to August 2022 and the total number of patient studied was 35. Cysts located in segment 3, 4, 5, 6, and 8, with no evidence of calcifications or infection or major biliary communication were included in the study. Cyst located in segment 1, 2, and 7, cyst located near vascular hilum, deep seated cyst, recurrent cysts, and ruptured hydatid cyst were excluded from the study.

**Results:** The study included 35 patients which included 17 males and 18 females. Twenty eight (80%) patients had a single univesicular cyst located in right lobe of liver, while as three patients had a cyst in right lobe as well as left lobe. Four patient had two cysts in the right lobe. Deroofing of the cyst with evacuation of contents was done in 23 (65.71%) patients while as partial pericystectomy was done in 12 (34.28%) patients. External tube drainage was done in 19 (54.28%) patients while as omentopexy was done in 16 (45.71%) patients. The average operative time was 89.80 minutes (60–120 minutes). Postoperative biliary leak was seen in three patients, which ceased spontaneously within 7–10 days in two patients. One patient needed ERCP with sphincterotomy. Time for return to work was 8.10 days (6–12 days). One of the patients had recurrence after 18 months.

**Conclusion:** Laparoscopic hydatid surgery is safe and feasible in selected patients. The main advantage being the lower postoperative morbidity, shorter hospital stay, early return to routine work and low recurrence rate.

**Keywords:** Advanced laparoscopic surgery, Diagnostic laparoscopy, Direct trocar entry.

*World Journal of Laparoscopic Surgery* (2024): 10.5005/jp-journals-10033-1594

## INTRODUCTION

Hydatidosis is a zoonotic disease having a worldwide distribution. The disease in humans is caused by larval stage of *Echinococcus granulosus* or *Echinococcus multilocularis*. The life cycle of the disease includes dog as the definitive host and the grass grazing animals as the intermediate hosts. Man is the accidental host and gets infected by utilizing vegetables, fruits and drinking water polluted by eggs passed along with the feces by these dogs. Humans may also get infected by handling of pet dogs. Surgery is the treatment of choice and is presently the most effective treatment for hydatid disease.<sup>1,2</sup> Despite so much of progress and advancement, there is still no consensus as for as the extent of surgical procedure is concerned. Minimally invasive procedures such as laparoscopy and percutaneous aspiration is being attempted in selected patients.

The objective of treatment of hydatid disease should be complete eradication of the parasite and reducing any recurrence in future.<sup>2–4</sup> The appropriate modality of the treatment of hydatid disease is determined by several factors such as overall health of the patient, location, size, and number of the cysts and whether the cyst is complicated or not. Presently, there are three main modalities of treatment for hydatid cyst of liver which include chemotherapy, conventional surgery, and minimally invasive procedures.<sup>5</sup>

Department of Surgery, SKIMS Medical College and Hospital, Srinagar, Jammu and Kashmir, India

**Corresponding Author:** Shamsul Bari, Department of Surgery, SKIMS Medical College and Hospital, Srinagar, Jammu and Kashmir, India, Phone: +91 9419753596, e-mail: shamsulbari@rediffmail.com

**How to cite this article:** Bari S. Laparoscopic Management of Hepatic Hydatid Cyst: A Single Institute Based Experience. *World J Lap Surg* 2024;17(1):9–13.

**Source of support:** Nil

**Conflict of interest:** None

Minimally invasive procedures include PAIR (percutaneous aspiration, injection, and respiration) technique, modified catheterization technique and Laparoscopic approach. Advantages of laparoscopy include that it is minimally invasive and thorough examination of the entire peritoneal and cyst cavity is possible. The other advantages of laparoscopy include shorter hospital stay, less wound-related complications, and early recovery.<sup>6</sup> However it is less feasible in complicated cysts such as ruptured cysts, cysts with major biliary communication, deep-seated cysts, cysts located in difficult locations, and cysts located close to vascular hilum. Aim of conducting this study was to determine the safety and feasibility of laparoscopic surgery in hydatid disease of liver.



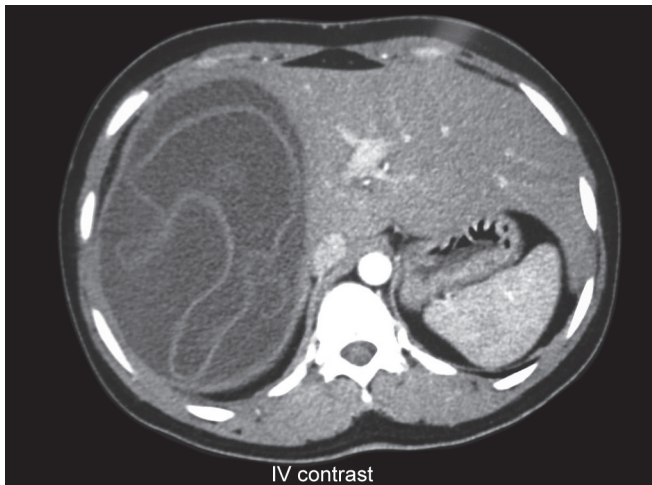


Fig. 1: The CT image showing unilocular cyst in right lobe

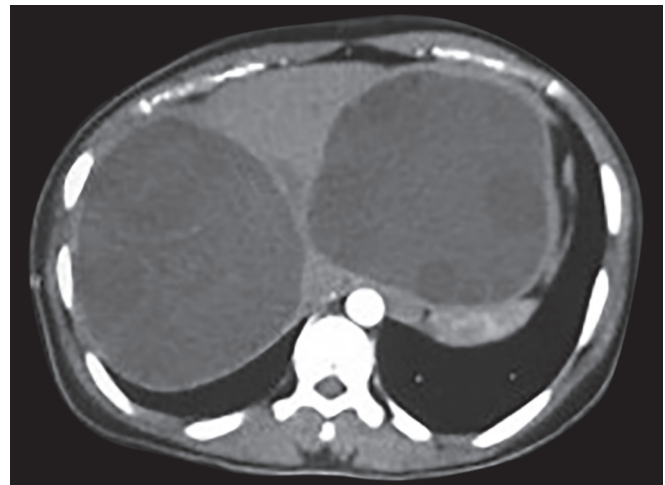

Fig. 2: The CT image showing cyst in right lobe and left lobe

## MATERIALS AND METHODS

The study entitled, "laparoscopic management of hepatic hydatid cyst—A single institute-based experience" was conducted in the Department of General and Minimal invasive surgery SKIMS, Medical College Bemina, Srinagar, Kashmir, India from November 2019 to August 2021 with a further follow up for a period of 1 year from September 2021 to August 2022. Ethical clearance from the Institutional Ethical Committee was sought before initiating the study. It was a prospective observational study and included 35 patients admitted with a USG and CT documented hepatic hydatid disease. The patients with cyst located in segment 1, 2, and 7 of liver, cyst located near vascular hilum, deep-seated cyst, recurrent cysts, ruptured cyst, infected cysts, calcified cysts, cysts with major biliary communication, and patients who has the history of multiple upper abdominal surgeries were excluded from the study. All the patients were put on preoperative albendazole therapy for a period of 4 weeks, in the dose of 10 mg/kg body weight which was continued postoperatively for a period of 3 months.

### Preoperative Assessment

Detailed history and thorough physical examination were carried out in all the patients. In addition to it, various baseline investigations, ultrasonography, computed tomography (Figs 1 and 2) and serological examination was done in all the patients. An informed consent was taken from all the patients before the procedure.

### Surgical Technique

All the procedures were performed under general anesthesia. After placing the patients in reverse Trendelenburg's position, Veress needle was introduced via supra-umbilical incision to create the Pneumoperitoneum. Carbon-dioxide gas was used to insufflate the abdominal cavity and intra-abdominal pressure of 12 mm Hg was set. After the Pneumoperitoneum was created, same supra-umbilical incision was used for introducing a 10 mm trocar for the telescope. Once the telescope was introduced, diagnostic peritoneoscopy was done and whole of the peritoneal cavity was examined. After this, a 10 mm port (working port) was introduced in the right hypochondrium into the peritoneal cavity to the right of the falciparum ligament 5 cm below the subcostal margin under direct vision. This was followed by insertion of a 5 mm trocar, a 5 cm

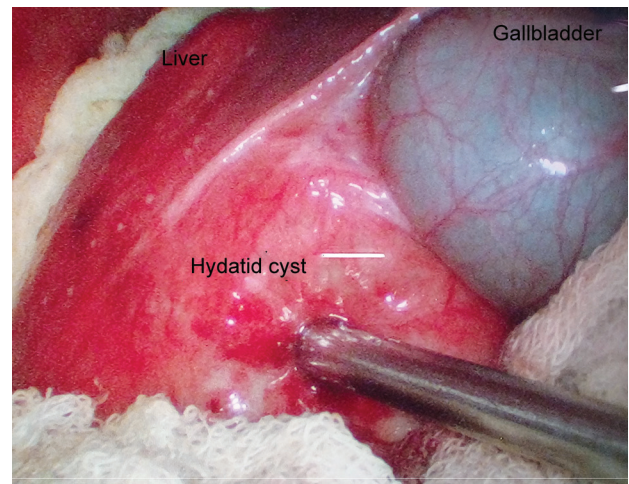
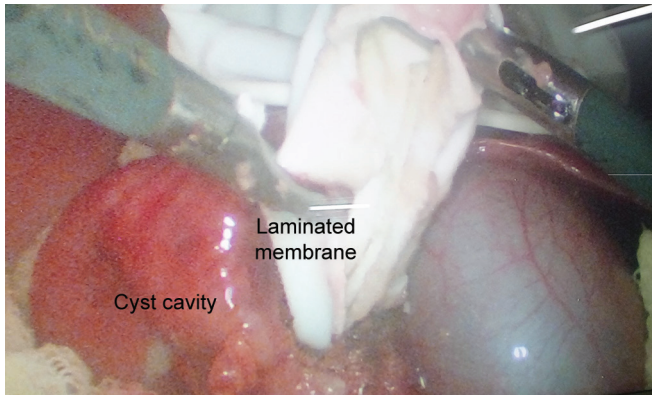


Fig. 3: Intraoperative picture during laparoscopy with a suction tip inside the cavity

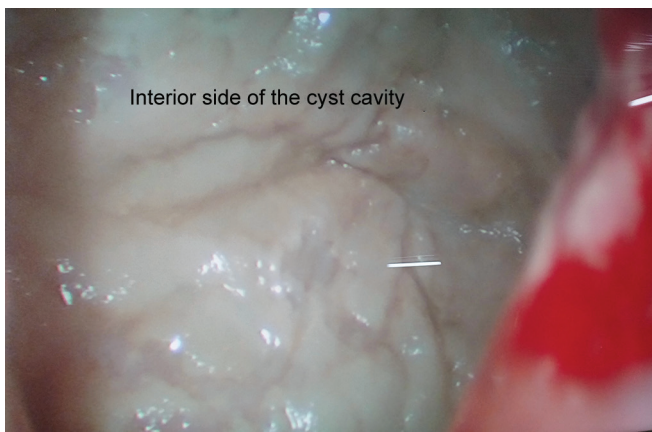
below the right costal margin in the mid clavicular line. In patients with a cyst in right lobe, another 5 mm right subcostal trocar was placed in the anterior axillary line. While as in patients with a cyst in left lobe, one 5 mm trocar was placed in the left subcostal, a right subcostal area in the midclavicular line on both the sides, while as the port in the anterior axillary line was not needed.

Surgical procedure was initiated by inspection of whole abdominal cavity to confirm the findings. The cyst in the liver was identified and falciform ligament divided for better exposure. Two or three gauze packs soaked in cetrimide solutions were used to isolate the cyst from rest of the abdominal contents. An aspiration needle was introduced into the cyst and around 50% of the fluid was aspirated from the cyst cavity (Fig. 3). The color of the aspirated fluid was observed to rule out any bilious nature of the fluid. Once the bilious nature of the aspirated fluid was ruled out, an equal amount of cetrimide 0.5% was injected into cyst as a scolical agent and kept inside the cavity for 10–15 minutes, followed by the suction of the cavity. Once all the fluid was sucked out from the cyst, deroofting of the cyst cavity was done and all the contents of the cyst taken out carefully without causing any spillage. Laminated membrane (Fig. 4) and other contents of the cavity were placed in the sterile bag and





**Fig. 4:** Laminated membrane being delivered from the cyst during laparoscopy



**Fig. 5:** Inner side of the cyst cavity as seen with a laparoscope placed inside the cavity after evacuation of the contents

then delivered out. This was followed by introduction of camera into cyst cavity to rule out presence of any cysto-biliary communication and any daughter cysts (Fig. 5). In patients with no cystobiliary communication, scolicalid agent was again instilled into the cavity to sterilize it. If any cystobiliary communication was found, it was sutured using Vicryl 2-0. In patients with exophytic cyst, excision of the redundant cyst wall was done (partial pericystectomy) using harmonic as an energy source. External tube drainage of residual cavity was done in 23 patients while as omentopexy was done in 12 patients. In all patients, a tube drain was placed in the sub-hepatic area followed by the closure of port sites.

### Postoperative Care

Intravenous fluids were given to all the patients during first 12 hours followed by liquid orals. All the patients were put on intravenous third generation cephalosporins and intramuscular injection of diclofenac for a period of 3 days followed by oral antibiotics for a period of 5 days. Patients were advised to take oral analgesics as and when needed. Patients were monitored for any Jaundice and the color and quantity of fluid in the drain during the postoperative period. All the patients were put on albendazole therapy from the second postoperative day. The tube drain was removed once the drain was less than 50 mL per 24 hours and non-bilious in color, which was usually by 3rd or 4th postoperative. However, in two patients who continued with bilious drainage, the drains were

**Table 1:** Clinical presentation of patients

Chief complaints	No. of patients (n = 35)	Percentage
Abdominal pain	16	45%
Abdominal mass	04	11.42%
Abdominal mass + pain	04	11.42%
Asymptomatic	11	31%

**Table 2:** Characteristics of liver cysts

Type of cyst	No. of patients	Percentage (%)
Univesicular	24	68.57%
Multivesicular	11	31.42%
Number of cysts		
One cyst	32	91.42%
Two cysts	3	8.57%
Three cysts	0	0%
Site of cysts		
Right lobe	28	80%
Left lobe	4	11.42%
Both lobes	3	8.57%

removed between 7 and 10 days. While as in one patient bilious drain where the drainage continued beyond 2 weeks had to be subjected for ERCP with sphincterotomy, followed by the removal of drain by 3 weeks.

### Statistical Analysis

Statistical Package for Social Sciences (SPSS) version 20 was used for tabulating, coding, and analyzing the data. The data were first entered into a MS Excel sheet and were later converted into SPSS data for analysis. The results were expressed as percentages or mean (SD).

## RESULTS AND OBSERVATIONS

During this period of study, 37 patients with hydatid cyst of liver were planned for laparoscopic management in our hospital. In view of difficult approach, we had to convert two patients to open surgery and were not included in the study. The age of our study patients varied from 16 to 60 years with a mean age of 40.27 years. The number of male patients was 17 males while as number of females was 18. In this study, abdominal pain was seen in 45% and abdominal mass in 11.42% patients (Table 1). Out of 35 patients, a single unilocular cyst in the right lobe was seen in 28 (80%) patients. A cyst in both the right lobe and left lobe was seen in three patients. On the other hand, four of our study patients had two cysts in the right lobe (Table 2).

Deroofing of the cyst with extraction of contents was done in 23 (65.71%) patients, while as partial pericystectomy was done in 12 (34.28%) patients. Cysto-biliary communication was seen in 2 (5.71%) patients which was closed using Vicryl suture 2-0. The residual cavity was managed with external tube drainage in 19 (54.28%) patients while as omentopexy was done in 16 (45.71%) patients (Table 3). The mean operative time in this study was 89.80 minutes (65–120 minutes) (Table 3). Biliary fistula was the most frequent complication in the postoperative period and was seen in three patients, which ceased spontaneously after 7–10 days in two

**Table 3:** Intraoperative and postoperative study parameters

Parameter	Number of cases	Percentage
Type of surgery		
Deroofting with evacuation of contents	23	65.71%
Partial pericystectomy	12	34.28%
Management of residual cyst cavity		
External tube drainage	19	54.28%
Omentopexy	16	45.71%
Cysto-biliary communication	02	5.71%
Postoperative biliary leak	03	8.57%
Surgical site infections	Nil	00
Anaphylaxis	Nil	00
Recurrence	01	2.85%
Mean operative time	89.80 ± 6.08	–
Mean hospital stay	3.40 ± 1.63	–
Return to work (days)	8.10 ± 1.83	–
Mean ± SD		

patients. One patient needed ERCP with sphincterotomy to control the biliary fistula. In this study, the average hospital duration was 3.40 days (2–6 days), while as the average time taken to resume routine activities was 8.10 days (6–12 days). One of the patients had recurrence after 18 months and is being treated conservatively.

## DISCUSSION

Surgery is the treatment of choice for hydatid disease of liver.<sup>2,3</sup> In the initial stages, laparoscopic approach was not used for the management of hydatid disease in view of the higher risk of intraperitoneal spillage as compared to open approach. However, recent studies have shown that with laparoscopy, actual risk of dissemination and short-term recurrence are much less as compared to open surgery. As far as laparoscopy in hydatid surgery is concerned, it has got various advantages including lesser morbidity, lesser stay in hospital, faster return to work, and better cosmesis.<sup>6–8</sup>

In our study, 48.57% patients were males and 51.42% females and the mean age of the patients was 40.27 years which is in concordance with other studies.<sup>6–9</sup> Abdominal pain was the commonest complaint as seen in 45% patients followed by abdominal mass in 11.42% patients. This is again in accordance to the results of Ul-Bari et al.<sup>10</sup> and Fadel et al.<sup>11</sup> In our study, 80% of the patients had a cyst in right lobe, 11.42% patients had cyst in left lobe while as remaining patients had bi-lobar involvement, which is in agreement to the results of other studies.<sup>9–11</sup> In our study, 92% patients had a single cyst, while as the remaining patients had more than one cyst involving both the right and left lobe. On the other hand, in a study conducted by Fadel et al.<sup>11</sup> 96% patients had a single cyst, while as remaining 4% had a multi-centric lesion. Postoperative biliary fistula was noted in 8.57% patients, which is in agreement to the results of other studies.<sup>9,12</sup> In the present study, the mean operative time in laparoscopic group was 89.80 minutes. Many other studies had comparable results.<sup>9–11</sup> On the other hand, in two separate studies conducted by Fadel et al.<sup>11</sup> and Yağmur et al.<sup>13</sup> a respective mean operative time of 78.2 and 90 minutes (range, 60–190) was reported. Another study conducted recently

reported that operative time had a mean value of 66 minutes, with a range between 66 and 160 minutes.<sup>12</sup>

In this study, two (5.71%) patients had to be converted to open approach. In one case, it was because of difficult access and in another case, it was because of inability to suture a major cystobiliary communication. In a study conducted by Fadel et al.<sup>11</sup> conversion to the open approach was performed in only one (4%) case owing to surgical bleeding. While as in a study conducted by Yağmur et al.,<sup>13</sup> conversion to the open approach was performed in 6.81% of cases because of restricted access.

In our study, cystobiliary communication was seen in two (5.71%) patients, which was closed using a Vicryl suture 2-0. Rooh-ul-Muqim et al.<sup>9</sup> and Fadel et al.<sup>11</sup> have reported a cystobiliary communication in 8% patients. As per the available evidence the cystobiliary communication has been reported in 5–30% cases and use of scolicalid agents in such patients may damage the biliary tree and result into a sclerosing cholangitis. That is why injection of scolicalid agent into the unopened cyst is not recommended by most of the clinicians. In the current study, postoperative biliary leak was seen in three patients, which stopped spontaneously after 7–10 days in two patients. However, one patient needed ERCP and sphincterotomy. Rooh-ul-Muqim et al.<sup>9</sup> documented postoperative biliary leak in four (10%) patients out of 40 patients. Yağmur et al.<sup>13</sup> reported postoperative leak in seven (15.91%) patients out of 44 cases, of which five cases were conservatively managed, whereas the remaining two cases required ERCP. Other authors have reported a higher incidence of postoperative biliary fistula rate of 36.7%.<sup>12</sup> Several studies have also reported other complications such as port-site infection and port-site hernia in 7.69 and 3.84%, respectively.<sup>14,15</sup> However, these complications were not encountered in the current study.

The mean stay in hospital in the present study was 3.40 days which was in agreement with results of several studies.<sup>5,14–17</sup> In our study, patients resumed their routine work in 8.10 days. This was because of the minimal invasive approach of laparoscopic which is in accordance to the results of other studies.<sup>16,17</sup> Over a follow up period of more than 18 months a low recurrence rate of 2.85% was seen due to preoperative and postoperative use of albendazole in all patients. On the other hand, several studies<sup>18,19</sup> have reported no recurrence in patients treated with Albendazole. Similarly, Nooghabi et al.<sup>20</sup> have also reported no recurrence after laparoscopic management of these patients with a mean follow-up period of 17.86 months. Tai et al.<sup>21</sup> reported only one (2.27%) case of recurrence, after they have followed cases for a median of 25 months.

## Limitations

Since the large surgical packs are not used in laparoscopic hydatid surgery, there will always be a theoretical risk of increased dissemination of disease as compared to open surgery. All the necessary precautions need to be taken to decrease the dissemination of disease which includes using high pressure suction devices, repeated aspiration, and irrigation of cyst several times before evacuation of solid contents, very careful and smooth evacuation of membranes and daughter cysts and using endobags if available for evacuation of contents of cyst.

## CONCLUSION

Based on the results of our study, we conclude that selective use of laparoscopic approach in hydatid disease is safe and

feasible modality of management as it is associated with lesser postoperative morbidity, lesser hospital stay, low mortality, quick return to routine activities, and less recurrence. All the necessary measures should be followed during extraction of laminated membrane and daughter cyst to avoid any dissemination of the disease including the use of endobags.

## ORCID

Shamsul Bari  <http://orcid.org/0000-0002-5245-5440>

## REFERENCES

1. Arif SH, UI-bari S, Wani NA, et al. Albendazole as an adjuvant to the standard surgical management of hydatid cyst liver. *Int J Surg* 2008;6(6):448–451. DOI: 10.1016/j.ijsu.2008.08.003.
2. Franchi C, Di Vico B, Teggi A. Long-term evaluation of patients with hydatosis treated with benzimidazole carbamates. *Clin Infect Dis* 1999;29(2):304–309. DOI: 10.1086/520205.
3. Chautems R, Buhler L, Gold B. Long term results after complete or incomplete surgical resection of liver hydatid disease. *Swiss Med Wkly* 2003;133(17–18):258–262. DOI: 10.4414/smw.2003.10168.
4. Avgerinos ED, Pavlakis E, Stathouloupoulos A, et al. Clinical presentation and surgical management of liver hydatosis: Our 20 years experience. *HPB* 2006;8:189–193. DOI: 10.1080/13651820500539495.
5. Christian KK, Pitt HA. Hepatic Abscess cystic disease of liver. In: Zinner MJ, Ashley SW, (eds). *Mangots Abdominal Operations*. 11th ed. Newyork: McGraw Hill 2007; pp. 757–781.
6. Ertem M, Karahasanoglu T, Yavuz N. Laparoscopically treated liver hydatid cysts. *Arch Surg* 2002;137(10):1170–1173. DOI: 10.1001/archsurg.137.10.1170.
7. Balik AA, Başoğlu M, Celebi F, et al. Surgical treatment of hydatid disease of liver – Review of 304 cases. *Arch Surg* 1999;134(2):166–169. DOI: 10.1001/archsurg.134.2.166.
8. Rihani HR, El-Nabulsi BA, Aziz A, et al. Laparoscopic approach to liver hydatid cyst. *JRMS* 2005;12(2):69–71. DOI: 10.4274/atfm.galenos.2022.44366.
9. Rooh-ul-Muqim, Kamran K, Khalil J, et al. Laparoscopic treatment of hepatic hydatid cyst. *J Coll Physicians Surg Pak* 2011;21(8):468–471. PMID: 21798132.
10. Ul-Bari S, Arif SH, Malik AA, et al. Role of albendazole in the management of hydatid cyst liver. *Saudi J Gastroenterol* 2011;17(5):343–347. DOI: 10.4103/1319-3767.84493.
11. Fadel BA, Abdelgawaad MS, Soliman AA, et al. Laparoscopic management of liver hydatid cyst: An early center experience of consecutive 25 cases. *Egypt J Surg* 2021;40(3):2021. DOI: 10.1016/j.lers.2023-04.002.
12. Yağmur Y, Akbulut S, Gümüş S, et al. Laparoscopic management of hydatid cyst of the liver. *S Afr J Surg* 2016;54:14–17. PMID: 28240462.
13. Bhadreshwara KA et al. Comparative study of laparoscopic versus open surgery. *IAIM* 2015;2(1):30–35. DOI: 10.5114/wiitm.2022.115225.
14. Baskaran V, Patnaik PK. Feasibility and safety of laparoscopic management of hydatid disease of liver. *JSL* 2004;8(4):359–363. PMID: 15554281.
15. Bilge A, Sozuer EM. Diagnosis and surgical treatment of hepatic hydatid disease. *HPB Surg* 1994;8:77–81. DOI: <https://doi.org/10.1155/1994/95701>.
16. Zaharie F, Bartos D, Mocan L, et al. Open or laparoscopic treatment for hydatid disease of the liver? A 10-year single-institution experience. *Surg Endosc* 2013;27(6):2110–2116. DOI: 10.1007/s00464-012-2719-0.
17. Busić Z, Cupurdija K, Servis D, et al. Surgical treatment of liver Echinococcosis – Open or laparoscopic surgery? *Coll Antropol* 2012;36(4):1363–1366. PMID: 23390834.
18. Al-Shareef Z, Hamour OA, Al-Shlash S, et al. Laparoscopic treatment of hepatic hydatid cysts with a liposuction. *JSL* 2002;6(4):327–330. PMID: 12500831.
19. Gupta N, Oza V, Mahida H, et al. Comparative study between laparoscopic versus open deroofting in 30 cases of liver hydatid cyst. *Int J Sci Res* 2014;3(9):382–386. DOI: 10.36106/IJSR.
20. Nooghabi AJ, Bahar MM, Asadi M, et al. Evaluation and comparison of the early outcomes of open and laparoscopic surgery of liver hydatid cyst. *Surg Laparosc Endosc Percutan Tech* 2015;25(5):403–407. DOI: 10.1097/SLE.0000000000000199.
21. Tai QW, Tuxun T, Zhang JH, et al. The role of laparoscopy in the management of liver hydatid cyst: A single-center experience and world review of the literature. *Surg Laparosc Endosc Percutan Tech* 2013; 23(2):171–175. DOI: 10.1097/SLE.0b013e31828a0b78.

# Is Prophylactic Abdominal Drainage Necessary after Laparoscopic Colectomy for Colon Cancer? A Propensity Score-matched Analysis

Le Huy Luu<sup>1</sup>, Tran Van Hoi<sup>2</sup>, Nguyen Van Hai<sup>3</sup>, Nguyen Anh Dung<sup>4</sup>, Nguyen Lam Vuong<sup>5</sup>, Do Dinh Cong<sup>6</sup>

Received on: 29 September 2022; Accepted on: 27 October 2023; Published on: 14 February 2024

## ABSTRACT

**Aim:** In 2018, the Enhanced Recovery after Surgery (ERAS) Society recommended against routine drainage after colorectal surgery. However, the evidence is relatively old and few studies were performed in low-to-middle income country (LMIC) setting. This study aimed to compare outcomes of laparoscopic colectomy with and without prophylactic drainage for colon cancer.

**Methods:** A retrospective study was performed from 2018 to 2021 with patients who underwent laparoscopic colectomy with D3 lymphadenectomy for colon cancer. The use of prophylactic drainage was depended on routine practice of surgeons. Outcomes were postoperative complications and postoperative hospital length of stay. The drain and no-drain groups were compared using propensity score-matched (PSM) analysis.

**Results:** The study included 143 patients (59 in the drain group and 84 in the no-drain group). The PSM resulted in 94 patients (47 in each group). Median age was 62 years. The most frequent was right hemicolectomy (33.6%), followed by left hemicolectomy (32.2%), sigmoid colectomy (21%), extended right hemicolectomy (9.8%), transverse hemicolectomy (2.1%), and total colectomy (1.4%). Postoperative hospital stay was significantly shorter in the no-drain group (median of 5 vs 6 days). The no-drain group also had lower rate of complications (23.8 vs 30.5% and 23.4 vs 34% before and after matching, respectively) and less severe complications based on Clavien-Dindo classification, but the difference was not significant.

**Conclusion:** Laparoscopic colectomy without prophylactic drainage is safe in the treatment of colon cancer. This approach can shorten postoperative hospital stay and should be applied even in the LMIC setting.

**Keywords:** Colectomy, Laparoscopic surgery, Routine drainage.

*World Journal of Laparoscopic Surgery* (2024): 10.5005/jp-journals-10033-1596

## INTRODUCTION

In 2018, the Enhanced Recovery after Surgery (ERAS) Society's guidelines recommended that pelvic and peritoneal drains should not be used routinely in perioperative care in colorectal surgery.<sup>1</sup> However, with routine practices of many surgeons in a long period, prophylactic drainage after colectomy is not easily abandoned, particularly in low-to-middle income country (LMIC) setting. Prophylactic abdominal drains after colectomy have been used to early detect potential complications including bleeding and anastomotic leakage, and prevent fluid accumulation. On the contrary, routine drainage can cause some disadvantages such as increased serous secretion, increased risk of intra-abdominal infection, bowel obstruction, and prolonged hospital length of stay.<sup>2-5</sup> There were a number of studies on the safety and effectiveness of prophylactic drainage after elective colorectal surgery and most of them showed similar complication rate between groups with and without routine drainage.<sup>2,3,5-7</sup> Most authors agreed that prophylactic drains had no effect on clinical outcomes in elective colorectal surgery. Nevertheless, the majority of these studies were performed in upper-middle- or high-income countries, which healthcare facilities are better than in LMICs. Whether no prophylactic drainage after colectomy is safe in LMIC setting is still questioned. Also, the ERAS Society's recommendation was based on relatively old evidences, which most of the studies were performed around 20 years ago.<sup>2,7</sup> Meanwhile, there have been changes in colectomy, for example, the wide application of minimally invasive surgery, more radical surgery such as complete

<sup>1-3,6</sup>Department of General Surgery, Faculty of Medicine, University of Medicine and Pharmacy at Ho Chi Minh City, Ho Chi Minh City, Vietnam

<sup>4</sup>Department of General Surgery, Nhan Dan Gia Dinh Hospital, Ho Chi Minh City, Vietnam

<sup>5</sup>Department of Medical Statistics and Informatics, Faculty of Public Health, University of Medicine and Pharmacy at Ho Chi Minh City, Ho Chi Minh City, Vietnam

**Corresponding Author:** Nguyen Lam Vuong, Department of Medical Statistics and Informatics, Faculty of Public Health, University of Medicine and Pharmacy at Ho Chi Minh City, Ho Chi Minh City, Vietnam, Phone: +84 2838558411, e-mail: [nguyenlamvuong@ump.edu.vn](mailto:nguyenlamvuong@ump.edu.vn)

**How to cite this article:** Luu LH, Hoi TV, Hai NV, et al. Is Prophylactic Abdominal Drainage Necessary after Laparoscopic Colectomy for Colon Cancer? A Propensity Score-matched Analysis. *World J Lap Surg* 2024;17(1):14-19.

**Source of support:** Nil

**Conflict of interest:** None

mesocolic excision and extended lymph node dissection (D3 lymphadenectomy), stapled anastomosis, and the use of new instruments in the surgery. Updated studies on whether the use of routine drainage is necessary after colorectal anastomosis are needed.

In our hospital, we started to apply the ERAS guidelines without routine drainage for colectomy since 2018 and the results are promising. Hence, this study aimed to compare outcomes of



patients who underwent laparoscopic colectomy with and without prophylactic abdominal drainage in the treatment of colon cancer.

## METHODS

### Study Design and Patients

This is a retrospective study performed at Gia Dinh People's Hospital, a referral teaching hospital in Ho Chi Minh City, Vietnam. The study was approved by the ethics committees of the hospital (No. 35/NDGD-HDDD on 22 April 2021) and University of Medicine and Pharmacy at Ho Chi Minh City (No. 114/HDDD-DHYD on 17 February 2021). All patients who underwent laparoscopic colectomy for the treatment of colon cancer from January 2018 to June 2021 were selected and divided into two groups: one with prophylactic drainage after surgery (drain group) and the other without prophylactic drainage (no-drain group). We excluded patients with the conversion to open surgery. Informed consent was waived since all data were retrospective collected.

The use of prophylactic drainage after surgery was decided by the operating surgeon and this was mainly depended on the routine practice of the surgeons rather than any clinical criterion. Patients in both groups were treated with the same protocol for preoperative preparation, intraoperative approach (except for prophylactic drainage after surgery), and postoperative evaluation. Preoperative bowel preparation was done or not depending on the operating surgeons. All patients underwent laparoscopic or laparoscopy-assisted colectomy with hand-sewn or stapled anastomosis. The colectomy along with D3 lymphadenectomy was performed in accordance with the Japanese Society's guidelines for Cancer of the Colon and Rectum.<sup>8</sup> In the drain group, 28F natural latex rubber tubes without vacuum devices (passive drains) were used to place near the anastomosis. The drains were removed when the output was less than 20 mL per day and the color of the output fluid was normal (light pink or light yellow). Antimicrobial prophylaxis was administered for all patients in both groups.

### Patient's Assessment

Patient's characteristics were collected using the hospital medical records, including preoperative variables [age, sex, body mass index (BMI), comorbidities, history of abdominal surgery, American Society of Anesthesiologists (ASA) score, hemoglobin, and serum albumin], intraoperative variables (surgical method, operating time, combined surgery, the amount of blood loss, anastomosis technique, and the number of drains), and pathological findings [tumor's location and stage according to the American Joint Committee Cancer (AJCC) tumor/node/metastasis (TNM) classification and staging system]. Outcomes of interest were postoperative complications (abdominal fluid collection, abscess, bleeding, anastomotic leakage, bowel obstruction, surgical site infection, and other organ complications), length of postoperative hospital stay, and time to flatus and oral feeding. All complications were recorded within 30 days after surgery and were evaluated using the Clavien-Dindo classification.<sup>9</sup>

### Statistical Analysis

Data were summarized by each group using median and interquartile range (IQR) for continuous variables and count and percentage for categorical variables. The comparison between the two groups was performed using Mann-Whitney-*U* test and Fisher's exact test for continuous and categorical variables, respectively. We used propensity score-matched (PSM) analysis to adjust for

differences in baseline and operating characteristics between the two groups. The propensity score was developed from a logistic regression model with covariates age, sex, BMI, ASA score, TNM stage, the type of surgery (elective or emergency), type of colon resection, and preoperative bowel preparation. Matched cases were selected at a ratio of 1:1 using the nearest neighbor method with a caliper of 0.1. We used the statistical software R version 4.1.0 to analyze the data and the "MatchIt" package for the PSM analysis.<sup>10</sup>

## RESULTS

A total of 143 patients with colon cancer underwent laparoscopic colectomy from January 2018 to June 2021 were included in the study: 59 patients with prophylactic drainage and 84 patients without prophylactic drainage after the surgery. The PSM strategy resulted in 94 patients (47 patients in each group). The characteristics of the patients and tumors were more balanced between the two groups after matching (Tables 1 and 2).

Median age was 62 years in both groups before matching and 62 and 64 years in the drain and no-drain groups after matching, respectively. Female was predominant in both groups after matching. Before matching, the most frequent comorbidities were hypertension (54.2 and 46.4% in the drain and no-drain groups before matching), followed by diabetes (20.3 and 20.2%) and coronary artery disease (22 and 16.7%); there were 13 patients (22%) in the drain group and 17 patients (20.2%) in the no-drain group with previous laparotomy or laparoscopic surgery. Comorbidities were balanced between groups after matching (Table 1).

In our study, the tumors located in all sections of the colon. Before matching, the most frequent were the sigmoid colon (25.4 and 20.2% in the drain and no-drain groups, respectively), followed by the descending colon (22 and 17.9%) and left colic flexure (15.3 and 7.1%). According to the TNM staging system, most of the patients were graded as stage III postoperatively (57.6 and 71.4% in the drain and no-drain groups before matching). After matching, tumor's location and stage were balanced between groups (Table 2).

Preoperative bowel preparation was performed in 18.6 and 10.7% of the patients in the drain and no-drain groups before matching. The operating time was similar in the two groups (median was 210 and 198 minutes before matching and 205 and 198 minutes after matching in the drain and no-drain groups, respectively). Before matching, the most frequent types of colectomy were right hemicolectomy (48 patients, 33.6%), followed by left hemicolectomy (46 patients, 32.2%). Median intraoperative blood loss was 50 mL in both groups and 11 patients (five in the drain group and six in the no-drain group) required blood transfusion. Most operative characteristics were balanced between groups after matching (Table 3). The median (IQR) time of drainage in the drain group was 5 (4.2; 6) days.

There were no significant differences in time to oral feeding, time of analgesics use, and time to flatus between the two groups in both the analyses before and after matching. Postoperative hospital length of stay, however, was significantly shorter in the no-drain group compared to the drain group in both the unmatched and matched cohorts (median of 5 vs 6 days). The drain group had higher rate of postoperative complications and more severe complications based on Clavien-Dindo classification in both the analyses before and after matching; however, the difference did not reach statistical significance. The most frequent complication was fluid accumulation but all required medical treatment only. Other complications were uncommon (Table 4).

**Table 1:** Patient's characteristics

	Unmatched cohort			Matched cohort		
	Drain (N = 59)	No-drain (N = 84)	p-value	Drain (N = 47)	No-drain (N = 47)	p-value
Age (year), median (IQR)	62.0 (49.5–70.5)	62.0 (51.0–70.2)	0.886	62.0 (51.0–71.0)	64.0 (57.0–72.5)	0.449
Sex female, n (%)	36 (61.0)	43 (51.2)	0.306	30 (63.8)	28 (59.6)	0.832
BMI (kg/m <sup>2</sup> ), median (IQR)	23.2 (21.2–25.0)	22.4 (19.6–24.7)	0.070	22.9 (20.5–24.6)	22.7 (19.6–25.0)	0.689
ASA, n (%)			0.271			0.828
I	5 (8.5)	10 (11.9)		5 (10.6)	4 (8.5)	
II	33 (55.9)	34 (40.5)		24 (51.1)	22 (46.8)	
III	21 (35.6)	39 (46.4)		18 (38.3)	21 (44.7)	
IV	0 (0)	1 (1.2)		0 (0)	0 (0)	
Hypertension, n (%)	32 (54.2)	39 (46.4)	0.398	26 (55.3)	25 (53.2)	1
Diabetes, n (%)	12 (20.3)	17 (20.2)	1	10 (21.3)	10 (21.3)	1
Coronary artery disease, n (%)	13 (22.0)	14 (16.7)	0.516	11 (23.4)	8 (17.0)	0.608
Previous stroke, n (%)	2 (3.4)	6 (7.1)	0.470	2 (4.3)	3 (6.4)	1
Chronic lung disease, n (%)	3 (5.1)	4 (4.8)	1	3 (6.4)	2 (4.3)	1
Heart failure, n (%)	0 (0)	3 (3.6)	0.268	0 (0)	3 (6.4)	0.242
History of pulmonary tuberculosis, n (%)	2 (3.4)	1 (1.2)	0.569	2 (4.3)	0 (0)	0.495
Chronic liver disease, n (%)	0 (0)	2 (2.4)	0.512	0 (0)	0 (0)	–
Chronic kidney disease, n (%)	0 (0)	1 (1.2)	1	0 (0)	0 (0)	–
Previous laparotomy/laparoscopic surgery, n (%)	13 (22.0)	17 (20.2)	0.837	11 (23.4)	11 (23.4)	1
Hemoglobin (gm/L), median (IQR)	122 (107–134)	118 (102–133)	0.574	123 (108–134)	118 (105–128)	0.296
Albumin (gm/L), median (IQR)	40.0 (38.0–42.8)	39.0 (36.0–42.0)	0.192	40.0 (38.0–42.0)	39.5 (37.0–41.8)	0.538

ASA, American Society of Anesthesiologists; BMI, body mass index; IQR, interquartile range

**Table 2:** Tumor's characteristics

	Unmatched cohort			Matched cohort		
	Drain (N = 59)	No-drain (N = 84)	p-value	Drain (N = 47)	No-drain (N = 47)	p-value
Tumor location, n (%)			0.199			0.637
Cecum	5 (8.5)	4 (4.8)		5 (10.6)	3 (6.4)	
Ascending colon	5 (8.5)	18 (21.4)		4 (8.5)	5 (10.6)	
Right colic flexure	4 (6.8)	15 (17.9)		4 (8.5)	9 (19.1)	
Transverse colon (1/3 right)	4 (6.8)	6 (7.1)		4 (8.5)	4 (8.5)	
Transverse colon (1/3 middle)	1 (1.7)	2 (2.4)		0 (0)	1 (2.1)	
Transverse colon (1/3 left)	1 (1.7)	1 (1.2)		1 (2.1)	0 (0)	
Left colic flexure	9 (15.3)	6 (7.1)		6 (12.8)	3 (6.4)	
Descending colon	13 (22.0)	15 (17.9)		9 (19.1)	11 (23.4)	
Sigmoid colon	15 (25.4)	17 (20.2)		14 (29.8)	11 (23.4)	
Cecum + Sigmoid colon	1 (1.7)	0 (0)		0 (0)	0 (0)	
Cecum + Left colic flexure	1 (1.7)	0 (0)		0 (0)	0 (0)	
T stage, n (%)			0.014			0.906
Tis	3 (5.1)	3 (3.6)		1 (2.1)	1 (2.1)	
T1	2 (3.4)	1 (1.2)		1 (2.1)	1 (2.1)	
T2	14 (23.7)	5 (6.0)		7 (14.9)	4 (8.5)	
T3	14 (23.7)	23 (27.4)		14 (29.8)	14 (29.8)	
T4a	26 (44.1)	52 (61.9)		24 (51.1)	27 (57.4)	
N stage, n (%)			0.659			0.760
0	39 (66.1)	55 (65.5)		28 (59.6)	29 (61.7)	
1a	7 (11.9)	11 (13.1)		6 (12.8)	5 (10.6)	
1b	7 (11.9)	11 (13.1)		7 (14.9)	8 (17.0)	

(Contd...)

**Table 2:** (Contd...)

	Unmatched cohort			Matched cohort		
	Drain (N = 59)	No-drain (N = 84)	p-value	Drain (N = 47)	No-drain (N = 47)	p-value
1c	3 (5.1)	2 (2.4)	0.063	3 (6.4)	1 (2.1)	1
2a	0 (0)	3 (3.6)		0 (0)	2 (4.3)	
2b	3 (5.1)	2 (2.4)		3 (6.4)	2 (4.3)	
TNM stage, n (%)						
Stage 0	3 (5.1)	3 (3.6)		1 (2.1)	1 (2.1)	
Stage I	13 (22.0)	6 (7.1)		5 (10.6)	5 (10.6)	
Stage II	9 (15.3)	15 (17.9)		9 (19.1)	10 (21.3)	
Stage III	34 (57.6)	60 (71.4)		32 (68.1)	31 (66.0)	

**Table 3:** Operative characteristics

	Unmatched cohort			Matched cohort		
	Drain (N = 59)	No-drain (N = 84)	p-value	Drain (N = 47)	No-drain (N = 47)	p-value
Preoperative bowel preparation, n (%)	11 (18.6)	9 (10.7)	0.223	8 (17.0)	7 (14.9)	1
Type of surgery, n (%)			0.629			1
Elective	52 (88.1)	71 (84.5)		41 (87.2)	42 (89.4)	
Emergency	7 (11.9)	13 (15.5)		6 (12.8)	5 (10.6)	
Operating time (min), median (IQR)	210 (180–230)	198 (170–230)	0.157	200 (180–220)	200 (170–225)	0.560
Type of colon resection, n (%)			0.068			0.916
Right hemicolectomy	13 (22.0)	35 (41.7)		13 (27.7)	16 (34.0)	
Extended right hemicolectomy	5 (8.5)	9 (10.7)		4 (8.5)	5 (10.6)	
Transverse hemicolectomy	2 (3.4)	1 (1.2)		1 (2.1)	1 (2.1)	
Left hemicolectomy	23 (39.0)	23 (27.4)		16 (34.0)	15 (31.9)	
Sigmoid colectomy	14 (23.7)	16 (19.0)		13 (27.7)	10 (21.3)	
Total colectomy	2 (3.4)	0 (0)		0 (0)	0 (0)	
Dissection instrument, n (%)			0.073			0.158
LigaSure scalpel	8 (13.6)	4 (4.8)		7 (14.9)	2 (4.3)	
Harmonic scalpel	51 (86.4)	80 (95.2)		40 (85.1)	45 (95.7)	
Blood loss (mL), median (IQR)	50 (50–100)	50 (20–100)	0.009	50 (50–100)	50 (20–100)	0.091
Anastomosis performing, n (%)			1			0.677
Stapled	54 (91.5)	77 (91.7)		43 (91.5)	45 (95.7)	
Handsewn	5 (8.5)	7 (8.3)		4 (8.5)	2 (4.3)	
Intra- or extracorporeal anastomosis, n (%)			<0.001			<0.001
Intracorporeal	20 (33.9)	73 (86.9)		16 (34.0)	43 (91.5)	
Extracorporeal	39 (66.1)	11 (13.1)		31 (66.0)	4 (8.5)	
Anastomosis technique, n (%)			1			0.617
Side-to-side	56 (94.9)	80 (95.2)		44 (93.6)	46 (97.9)	
Side-to-end	0 (0)	0 (0)		0 (0)	0 (0)	
End-to-end	3 (5.1)	4 (4.8)		3 (6.4)	1 (2.1)	
Blood transfusion, n (%)	5 (8.5)	6 (7.1)	0.761	3 (6.4)	2 (4.3)	1

IQR, interquartile range

## DISCUSSION

Our study revealed the safety and effectiveness of laparoscopic colectomy without prophylactic drainage after surgery for colon cancer in a LMIC setting. Compared to laparoscopic colectomy with prophylactic drainage, the approach without prophylactic drainage yielded similar safety results when considering the prevention of postoperative complications. The rate of anastomotic leak, bleeding, abdominal abscess, and reoperation due to complications

was low and balanced between the two groups. With respect to the effectiveness, the two groups were not significantly different in the time to flatus, time to oral feeding and time of analgesics use, but the approach without prophylactic drainage significantly shortened the length of postoperative hospital stay.

Prophylactic drainage is expected to provide some benefits. The first is to remove collected fluid after surgery, which is thought to reduce the risk of intra-abdominal infection.<sup>11,12</sup> The second is to

**Table 4:** Study outcomes

	Unmatched cohort			Matched cohort		
	Drain (N = 59)	No-drain (N = 84)	p-value	Drain (N = 47)	No-drain (N = 47)	p-value
Time to oral feeding (days), median (IQR)	3.0 (3.0–4.0)	3.0 (2.0–4.0)	0.108	3.0 (3.04.0)	3.0 (2.0–4.0)	0.087
Time of analgesics use (days), median (IQR)	4.0 (3.0–5.0)	4.0 (3.0–5.0)	0.210	4.0 (3.5–5.0)	4.0 (3.0–5.0)	0.302
Time to flatus (days), median (IQR)	3.0 (2.0–3.0)	3.0 (2.0–3.0)	0.658	3.0 (2.0–3.0)	3.0 (2.0–3.0)	0.229
Postoperative hospital stay (days), median (IQR)	6.0 (6.0–7.0)	5.0 (4.8–6.0)	<0.001	6.0 (6.0–7.5)	5.0 (5.0–6.0)	<0.001
Any complication, n (%)	18 (30.5)	20 (23.8)	0.443	16 (34.0)	11 (23.4)	0.362
Clavien-Dindo classification, n (%)			0.336			0.071
Grade I	8 (44.4)	14 (70.0)		7 (43.8)	10 (90.9)	
Grade II	6 (33.3)	4 (20.0)		6 (37.5)	1 (9.1)	
Grade III	3 (16.7)	2 (10.0)		2 (12.5)	0 (0)	
Grade IV	0 (0)	0 (0)		0 (0)	0 (0)	
Grade V	1 (5.6)	0 (0)		1 (6.2)	0 (0)	
Intra-abdominal fluid accumulation, n (%)	9 (15.3)	10 (11.9)	0.621	8 (17.0)	8 (17.0)	1
Surgical site infection, n (%)	4 (6.8)	7 (8.3)	1	4 (8.5)	4 (8.5)	1
Pulmonary complication, n (%)	3 (5.1)	3 (3.6)	0.691	3 (6.4)	1 (2.1)	0.617
Bowel obstruction, n (%)	3 (5.1)	0 (0)	0.068	2 (4.3)	0 (0)	0.495
Anastomotic leak, n (%)	1 (1.7)	2 (2.4)	1	1 (2.1)	0 (0)	1
Cardiovascular complication, n (%)	1 (1.7)	1 (1.2)	1	1 (2.1)	1 (2.1)	1
Bleeding, n (%)	0 (0)	1 (1.2)	1	0 (0)	0 (0)	–
Abdominal abscess, n (%)	1 (1.7)	0 (0)	0.413	1 (2.1)	0 (0)	1
Death, n (%)	1 (1.7)	0 (0)	0.413	1 (2.1)	0 (0)	1

IQR, interquartile range

early detect postoperative complications such as intra-abdominal bleeding or anastomotic leakage. Another potential benefit is to minimize the severity of leakage when occurring and possibly avoid reoperation.<sup>13,14</sup> Our study showed that there was no difference in fluid accumulation and intra-abdominal infection between the two groups. Thus, similar to other studies,<sup>1,15</sup> our results suggest that prophylactic drainage for the prevention of intraperitoneal fluid accumulation is not necessary.

Abdominal drainage might have a role in the diagnosis and treatment of anastomotic leakage. In our study, one patient in the drain group was diagnosed with anastomotic leakage at day 6 postoperatively without clinical signs of peritonitis except that there was fecal fluid in the drain's output. Conservative treatment was successful for that patient. Whereas two patients in the no-drain group with anastomotic leakage required reoperation, one with a misdiagnosis of postoperative paralytic ileus and the other with a diagnosis of localized peritonitis in the right upper quadrant. Prophylactic drainage in these two patients might help to early diagnose anastomotic leakage or prevent reoperation. Therefore, routine drainage may still play a role in the diagnosis and treatment of anastomotic leakage. Nevertheless, it should be highlighted that with the application of the ERAS protocol and the advancement of surgical techniques and instruments, anastomotic leakage is very rare. Thus, routine drainage for all patients should be considered and further studied in terms of the diagnosis and prevention of anastomotic leakage.

On the other hand, routine drainage may cause some problems. In our study, three patients in the drain group had intestinal obstruction; one patient resolved after drain removal and two patients required reoperation. Whether the drainage tube causes intestinal obstruction is still unclear, but this complication was

mentioned before.<sup>4,16</sup> In addition, routine drainage can cause other problems such as pain, discomfort, and limitation of returning to normal activities of the patients.

Routine abdominal drainage is still under debate in colectomy for colon cancer. Some studies showed no significant difference between the groups with and without prophylactic drainage in terms of postoperative complications such as anastomotic leakage, mortality, wound infection, pelvic sepsis, postoperative bowel obstruction, and reintervention for abdominal complication.<sup>5,7,13,17–20</sup> Several other studies favored routine drainage after colorectal surgery because a prophylactic drain could reduce the incidence of colorectal anastomotic leakage and the rate of reintervention due to complications.<sup>21–23</sup> However, since most level-1 evidence studies (well-designed randomized controlled trial and systematic review and meta-analysis) recommended against the use of prophylactic drainage, we agree with the ERAS guidelines that routine drainage should not be used after colorectal anastomosis. Since most of the studies were performed in the upper-middle- or high-income countries, our study supports this recommendation in the LMIC setting.

There are several limitations in this study. First, the sample size of the study is relatively small. Second, there was potential selection bias in the comparison between the two groups, which is a nature of a non-randomized comparative study. We tried to overcome this issue by using the PSM analysis, but potential bias might not be ruled out completely. Third, this study came from a single center with a single surgical team. This might limit the generalizability of the results to other settings.

## CONCLUSION

In conclusion, laparoscopic colectomy without prophylactic drainage is safe in the treatment of colon cancer. This approach



does not increase postoperative complications but shortens the length of postoperative hospital stay when compared to the surgery with routine prophylactic drainage. We suggest against the use of prophylactic drainage after laparoscopic colectomy for colon cancer even in the LMIC setting.

## AUTHORS' CONTRIBUTIONS

All authors contributed to the study conception and design. Material preparation, data collection, and analysis were performed by Le Huy Luu, Tran Van Hoi, and Nguyen Lam Vuong. The first draft of the manuscript was written by Le Huy Luu and all authors commented on previous versions of the manuscript. All authors read and approved the final manuscript.

## Disclaimer

This manuscript has been published as a preprint on Research Square (Available at: <https://europepmc.org/article/ppr/ppr436790>) prior to its formal publication in the World Journal of Laparoscopic Surgery, a peer-reviewed journal.

## ORCID

Nguyen Lam Vuong  <http://orcid.org/0000-0003-2684-3041>

## REFERENCES

- Gustafsson UO, Scott MJ, Hubner M, et al. Guidelines for perioperative care in elective colorectal surgery: Enhanced recovery after surgery (ERAS®) society recommendations: 2018. *World J Surg* 2018;43(3):659–695. DOI: 10.1007/s00268-018-4844-y.
- Jesus EC, Karliczek A, Matos D, et al. Prophylactic anastomotic drainage for colorectal surgery. *Cochrane Database Syst Rev* 2004;2004(4):Cd002100. DOI: 10.1002/14651858.CD002100.pub2.
- Guerra F, Giuliani G, Coletta D, et al. A meta-analysis of randomized controlled trials on the use of suction drains following rectal surgery. *Dig Surg* 2018;35(6):482–490. DOI: 10.1159/000485139.
- Poon CM, Leong HT. Abdominal drain causing early small bowel obstruction after laparoscopic colectomy. *Jsls* 2009;13(4):625–627. PMID: 20202408.
- Menahem B, Vallois A, Alves A, et al. Prophylactic pelvic drainage after rectal resection with extraperitoneal anastomosis: Is it worthwhile? A meta-analysis of randomized controlled trials. *Int J Colorectal Dis* 2017;32(11):1531–1538. DOI: 10.1007/s00384-017-2891-8.
- Bretagnol F, Slim K, Faucheron JL. [Anterior resection with low colorectal anastomosis. To drain or not?]. *Ann Chir* 2005;130(5):336–339. DOI: 10.1016/j.anchir.2005.03.007.
- Zhang HY, Zhao CL, Xie J, et al. To drain or not to drain in colorectal anastomosis: A meta-analysis. *Int J Colorectal Dis* 2016;31(5):951–960. DOI: 10.1007/s00384-016-2509-6.
- Hashiguchi Y, Muro K, Saito Y, et al. Japanese Society for Cancer of the Colon and Rectum (JSCCR) guidelines 2019 for the treatment of colorectal cancer. *Int J Clin Oncol* 2020;25(1):1–42. DOI: 10.1007/s10147-019-01485-z.
- Dindo D, Demartines N, Clavien PA. Classification of surgical complications: A new proposal with evaluation in a cohort of 6336 patients and results of a survey. *Ann Surg* 2004;240(2):205–213. DOI: 10.1097/01.sla.0000133083.54934.ae.
- Ho DE, Imai K, King G, et al. 'MatchIt': Nonparametric preprocessing for parametric causal inference. *J Stat Softw* 2011;42(8):1–28. DOI: <https://doi.org/10.18637/jss.v042.i08>.
- Dougherty SH, Simmons RL. The biology and practice of surgical drains. Part II. *Curr Probl Surg* 1992;29(9):633–730. DOI: 10.1016/0011-3840(92)90028-2.
- Lennox MS. Prophylactic drainage of colonic anastomoses. *Br J Surg* 1984;71(1):10–11. DOI: 10.1002/bjs.1800710103.
- Solaini L, Cavaliere D, Pecchini F, et al. The use of intra-abdominal drain in minimally invasive right colectomy: A propensity score matched analysis on postoperative outcomes. *Int J Colorectal Dis* 2019;34(12):2137–2141. DOI: 10.1007/s00384-019-03440-w.
- Taflampas P, Christodoulakis M, Tsiptsis DD. Anastomotic leakage after low anterior resection for rectal cancer: Facts, obscurity, and fiction. *Surg Today* 2009;39(3):183–188. DOI: 10.1007/s00595-008-3835-2.
- Puleo FJ, Mishra N, Hall JF. Use of intra-abdominal drains. *Clin Colon Rectal Surg* 2013;26(3):174–177. DOI: 10.1055/s-0033-1351134.
- Yang M, Kidane B, Saettler E. Delayed small bowel obstruction due to intra-abdominal drain: Case report and literature review. *Int Surg* 2018;103(3–4):149–153. DOI: 10.9738/intsurg-d-14-00297.1.
- Podda M, Di Saverio S, Davies RJ, et al. Prophylactic intra-abdominal drainage following colorectal anastomoses. A systematic review and meta-analysis of randomized controlled trials. *Am J Surg* 2020;219(1):164–174. DOI: 10.1016/j.amjsurg.2019.05.006.
- Urbach DR, Kennedy ED, Cohen MM. Colon and rectal anastomoses do not require routine drainage: A systematic review and meta-analysis. *Ann Surg* 1999;229(2):174–180. DOI: 10.1097/00000658-199902000-00003.
- Petrowsky H, Demartines N, Rousson V, et al. Evidence-based value of prophylactic drainage in gastrointestinal surgery: A systematic review and meta-analyses. *Ann Surg* 2004;240(6):1074–1084; discussion 1084–1075. DOI: 10.1097/01.sla.0000146149.17411.c5.
- Karliczek A, Jesus EC, Matos D, et al. Drainage or nondrainage in elective colorectal anastomosis: A systematic review and meta-analysis. *Colorectal Dis* 2006;8(4):259–265. DOI: 10.1111/j.1463-1318.2006.00999.x.
- Akiyoshi T, Ueno M, Fukunaga Y, et al. Incidence of and risk factors for anastomotic leakage after laparoscopic anterior resection with intracorporeal rectal transection and double-stapling technique anastomosis for rectal cancer. *Am J Surg* 2011;202(3):259–264. DOI: 10.1016/j.amjsurg.2010.11.014.
- Qu H, Liu Y, Bi DS. Clinical risk factors for anastomotic leakage after laparoscopic anterior resection for rectal cancer: A systematic review and meta-analysis. *Surg Endosc* 2015;29(12):3608–3617. DOI: 10.1007/s00464-015-4117-x.
- Rondelli F, Bugiantella W, Vedovati MC, et al. To drain or not to drain extraperitoneal colorectal anastomosis? A systematic review and meta-analysis. *Colorectal Dis* 2014;16(2):O35–O42. DOI: 10.1111/codi.12491.

# Nebulizer Underwater Sealed Chest Tube Drain Assembly: An Innovation for Irrigation in Laparoscopy and Endoscopy Procedures

Patrick Okechukwu Igwe

Received on: 27 March 2023; Accepted on: 10 May 2023; Published on: 14 February 2024

## ABSTRACT

**Background:** The conventional method of irrigation during laparoscopy and endoscopy is well documented in literature. The use of nebulizer or underwater sealed chest tube drain to achieve this has not been designed or studied in literature.

**Aim:** To showcase an innovation using nebulizer and underwater sealed chest tube drain assembled for irrigation during laparoscopy and endoscopy procedures.

**Materials and methods:** A prospective preliminary experimental study was conducted using a newly designed method of irrigation in laparoscopic and endoscopic surgeries performed from March 2021 to March 2022 in a tertiary center and a private hospital in South Southern, Nigeria. Ethical approval was obtained from the hospital ethics committee and informed consent was obtained from patients. The effectiveness of this new method was compared with standard irrigation machine as control. The patients were blocked into laparoscopy and colonoscopy procedures, respectively. Statistical analysis was performed using Statistical Package for Social Sciences (SPSS version 26).

**Results:** The results showed that the use of nebulizer underwater sealed chest tube drain assembly was very effective in laparoscopy and colonoscopy procedures. In three cases of fundoplication operations, five cases of cholecystectomies and 30 cases of hydro-jet insufflation colonoscopies were performed with good outcomes.

**Conclusion:** This new novel method will serve a very good alternative irrigation method in laparoscopy and endoscopy procedures. It is currently being studied in other methods, such as hysteroscopy, cystoscopy, and therapeutic endoscopies.

**Keywords:** Irrigation, Laparoscopy and endoscopy, Nebulizer, Underwater sealed chest tube drain.

*World Journal of Laparoscopic Surgery* (2024): 10.5005/jp-journals-10033-1581

## INTRODUCTION

The routine act of obtaining clear vision is an asset during laparoscopy and endoscopy procedures.<sup>1</sup> Conventionally, methods of irrigation during such laparoscopy and endoscopy have well documented literature reviews.<sup>2,3</sup> However, the use of nebulizer or underwater sealed chest tube drain to achieve irrigation with clear vision has not been designed or studied in literature.

## AIM

To showcase an innovation using nebulizer and underwater sealed chest tube drain assembled for irrigation during laparoscopy and endoscopy procedures.

## MATERIALS AND METHODS

A prospective preliminary experimental study was conducted using a newly designed method of irrigation in laparoscopic and endoscopic surgeries performed from March 2021 to March 2022 in a tertiary center and a private hospital in South Southern, Nigeria. Ethical approval was obtained from hospital ethics committee and informed consent was obtained from patients. The effectiveness of this new method was compared with standard irrigation machine as control. The patients were blocked into laparoscopy and colonoscopy procedures, respectively. Statistical analysis was performed using Statistical Package for Social Sciences (SPSS version 26).

Colorectal and Minimal Access, General Surgery Unit, Department of Surgery, University of Port Harcourt Teaching Hospital, Port Harcourt, Rivers State, Nigeria

**Corresponding Author:** Patrick Okechukwu Igwe, Colorectal and Minimal Access, General Surgery Unit, Department of Surgery, University of Port Harcourt Teaching Hospital, Port Harcourt, Rivers State, Nigeria, Phone: +2348035510045, e-mail: igwe\_patrick@yahoo.com

**How to cite this article:** Igwe PO. Nebulizer Underwater Sealed Chest Tube Drain Assembly: An Innovation for Irrigation in Laparoscopy and Endoscopy Procedures. *World J Lap Surg* 2024;17(1):20–22.

**Source of support:** Nil

**Conflict of interest:** None

## RESULTS

The result showed that the use of nebulizer underwater sealed chest tube drain assembly was very effective in laparoscopy and colonoscopy procedures. In three cases of fundoplication, five cases of cholecystectomies and 30 cases of hydro-jet insufflation colonoscopies performed with good outcome. [Figures 1 to 4](#) show the images of the different parts of the assembly.

## DISCUSSION

Clear and clean intraoperative field during laparoscopic and endoscopic surgical dissection aids good outcome during



Fig. 1: Nebulizer



Fig. 2: Underwater sealed chest tube



Fig. 3: The nebulizer and underwater sealed chest tube assembled

diagnostic and therapeutic procedures.<sup>1</sup> Having a good irrigation system is an advantage supplementary to laparoscopic and endoscopic armamentaria.

The dissection of laparoscopic procedures has only been documented using blunt and sharp dissections too. Hematomata

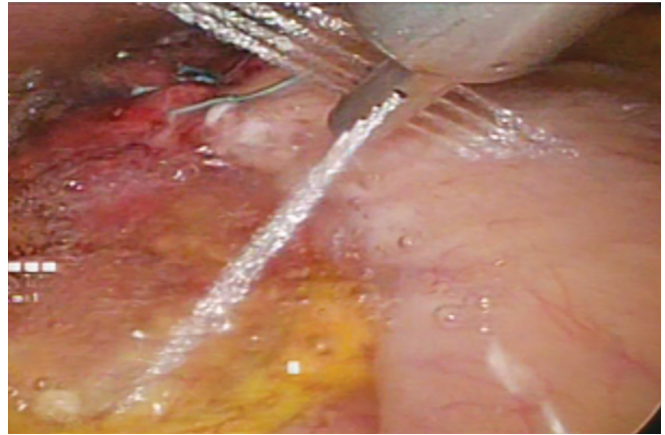


Fig. 4: The action of irrigation

can be produced by vigorous dissection. For more than 20 years, hydro-jet has been used during laparoscopy.<sup>1-4</sup> A particular hydro-jet generator is needed for hydro-jet dissection, which generates a high-pressure jet with a pressure range of 1500–4500 mm Hg. Several irrigation techniques also employed an irrigation probe with a hypodermic needle-like tip, including the “original” hydro-jet systems that drove the fluid through a central cannula.<sup>5-7</sup> Yet to make is the nebulizer underwater sealed assembly utilized in dissection and proper irrigation. It is simply connected the nebulizer to under water sealed chest tube drain filled with saline. This system is inexpensive, easily accessible, and user-friendly. Under pressure, the saline acts less like a knife with size 11 scalpel and more like a mild blunt dissector. It can also serve for clear vision during endoscopies or endoluminal surgery. It might theoretically spread cancerous cells or purulent materials but this is still under study.<sup>8</sup> A very thin water is produced via hydro-jet tubing system when in action.

It is possible to anticipate less postoperative pain with less tissue dissection. By more precisely delineating the anatomy. Hydro-dissection minimizes injury to the bile ducts.<sup>9</sup> The underwater sealed chest tube drain assembly gave a very clear vision during fundoplication surgery in author's experience.

Another method of separating tissues along bloodless natural planes is called hydro-dissection, which involves injecting a one-time fixed amount of saline/adrenaline solution into adherent tissues to cause water logging.<sup>10,11</sup> I observed this mechanism better with under water sealed chest tube drain assembly when used for bleeding diverticular disease especially in an unprepared or poorly prepared bowel during emergency colonoscopy.

The author used physiological warm normal saline or sterile (especially in malignant cases), which was easily accessible and reasonably priced, in the chest tube. It was easily absorbed in body, cleansed bodily systems, diluted any blood, and promoted hemostasis. Because anatomical bloodless tissue planes were easier to see, dissection proceeded more quickly. Laparoscopic procedure requires the identification of such bloodless tissue planes to prevent injury to adjacent structures.

The nebulizer under water sealed chest tube drain assembly also work like the multistream saline jet (MSSJ), except that saline is not the only fluid used in nebulizer under water sealed chest tube system. The MSSJ dissection is not hemostatic itself just as the nebulizer underwater sealed chest tube drain assembly too. In theory, it might dislodge any clots and therefore promote



bleeding, but in fact, it aids the surgeon in locating any bleeding vessels so that they can be diathermized.<sup>12</sup> The author utilizes warmed fluids since consuming significant volumes of cold saline or water can cause hypothermia. The warmth also relieves the CO<sub>2</sub>-induced hypothermia. Saline or water retention in the tissues can result in fluid overload, which is something to keep in mind, especially if the patient has liver, heart, or renal failure. To prevent saline-related problems like fluid overload and sepsis, I suctioned the peritoneal cavity dry at the end of the surgery. I also irrigated and suctioned out during endoscopic procedure. With laparoscopic procedures, the habit to always utilize heated blankets and a warmer is the norm. I had used this irrigation method in a different format during my earlier beginning in laparoscopy and endoscopy procedures.<sup>13</sup> I have also designed some innovation helpful in training residents in laparoscopic surgery,<sup>14</sup> and focused in research to aid performing laparoscopy in low- and middle-income economy. This method will not only add to literature but serve in immense value for beginners in laparoscopy and endoscopy procedures.

The use of nebulizer attracted a lot of interest to both the surgical and physicians especially during the oral presentation in the scientific conference and hence opens avenue for more research and collaboration in this regard. It is currently being studied in other methods, such as hysteroscopy, cystoscopy, and therapeutic endoscopies.

## CONCLUSION

This new novel method will serve a very good alternative irrigation method in laparoscopy and endoscopy procedures. It served for clear vision in this regard.

## PRESENTATIONS

- Society of Gastroenterology and Hepatology for Nigerian (SOGHIN) Kano 2022. As "Nebulizer Underwater sealed chest tube drain assembly: An innovation for irrigation in laparoscopy and endoscopy procedures."
- Proposal for further research in in therapeutic endoscopy in MD program of the National Postgraduate College of Nigeria.

## AUTHORS' CONTRIBUTION

The author has read and approved the final manuscript". POI was involved in conception and design and has given the final approval of the version to be published and agreed to be responsible for all aspects of the work in making that questions related to the accuracy or integrity of any part of the work are appropriately investigated and resolved. POI has involved carried out the

acquisition of data, or analysis and interpretation of data and drafting the manuscript.

## ACKNOWLEDGMENT

Author would like to thank Prof RK Mishra for his intuitive and didactic drills, teaching, and demonstration.

## REFERENCES

1. Durai R, Ng PC. Multi-stream saline-jet dissection using a simple irrigation system defines difficult tissue planes. *JSL* 2010;14(1):53–59. DOI: 10.4293/108680810X12674612014545.
2. Schöb OM, Schlumpf RB, Uhlschmid GK, et al. The multimodal water jet dissector – A technology for laparoscopic liver surgery. *Endosc Surg Allied Technol* 1994;2(6):311–314. PMID: 7704552.
3. Durai R, Ng PC. "Spaghetti technique" —Novel technique to facilitate laparoscopic appendectomy and cholecystectomy. *J Laparoendosc Adv Surg Tech A* 2009;19(5):667–668. DOI: 10.1089/lap.2009.0024.
4. Reich H. Laparoscopic treatment of extensive pelvic adhesions, including hydrosalpinx. *J Reprod Med* 1987;32(10):736–742. PMID: 2960807.
5. Park AE, Mastrangelo MJ Jr, Gandsas A, et al. Laparoscopic dissecting instruments. *Semin Laparosc Surg* 2001;8(1):42–52. PMID: 11337736.
6. Corvin S, Sturm W, Schlatter E, et al. Laparoscopic retroperitoneal lymph-node dissection with the waterjet is technically feasible and safe in testis-cancer patient. *J Endourol* 2005;19(7):823–826. DOI: 10.1089/end.2005.19.823.
7. Shekarri H, Shekarri B, Upadhyay J, et al. Hydro-jet assisted laparoscopic partial nephrectomy: Initial experience in a porcine model. *J Urol* 2000;163(3):1005–1008. PMID: 10688039.
8. Cuschieri A. Experimental evaluation of water-jet dissection in endoscopic surgery. *Endosc Surg Allied Technol* 1994;2(3–4):202–204. PMID: 8000886.
9. Singh K, Ohri A. Anatomic landmarks: Their usefulness in safe laparoscopic cholecystectomy. *Surg Endosc* 2006;20(11):1754–1758. DOI: 10.1007/s00464-005-0528-4.
10. Caliskan K, Nursal TZ, Yildirim S, et al. Hydrodissection with adrenaline-lidocaine-saline solution in laparoscopic cholecystectomy. *Langenbecks Arch Surg* 2006;391(4):359–363. DOI: 10.1007/s00423-006-0049-1.
11. Naude GP, Morris E, Bongard FS. Laparoscopic cholecystectomy facilitated by hydrodissection. *J Laparoendosc Adv Surg Tech A* 1998;8(4):215–218. DOI: 10.1089/lap.1998.8.215.
12. Burke RK. Bipolar electrocautery is a vital component of an efficient, integrated hydro-dissection system. *Endosc Surg Allied Technol* 1993;1(2):107–109. PMID: 8055298.
13. Igwe PO. Minimal access surgical experience in developing economy: A young trainee stimulant. *World J Lap Surg* 2021;14(1):20–22. DOI: 10.5005/jp-journals-10033-1433.
14. Igwe PO. Laparoscopy in Developing. Countries: A Resident-friendly Endo-Lap New Training Device. *World J Lap Surg* 2018;11(1):54–57. DOI: 10.5005/jp-journals-10033-1335.



# Evaluation of Perioperative Factors for Prediction of Postcholecystectomy Syndromes

Sayed Mohammed Asfaque Aamir<sup>1</sup>, Sattwik Acharya<sup>2</sup>

Received on: 19 August 2023; Accepted on: 15 October 2023; Published on: 14 February 2024

## ABSTRACT

**Aim:** To find the factors contributing to postcholecystectomy symptoms after laparoscopic cholecystectomy.

**Methodology:** A retrospective observational study with 50 symptomatic patients visiting the outpatient department (OPD) of the Department of Surgery and Department of Casualty following laparoscopic cholecystectomy whose perioperative clinical factors were evaluated to predict the development of postcholecystectomy syndromes using a Chi-square test.

### Conclusion:

- Pain was the predominant symptom seen in all (100%) of the patients.
- Female sex (70%) and body mass index (BMI; 30%) were a strong significant predictor.
- Previous history of hospitalization ( $p < 0.0008$ ) for acute cholecystitis (32%), acute pancreatitis (4%), obstructive jaundice (18%), cirrhosis (14%) were significant predictors of pelvic congestion syndrome (PCS).
- Ultrasonography (USG) findings ( $p < 0.0471$ ) of thickened gallbladder (GB) wall (40%) and pericholecystic collection (16%) were strong predictors of difficult surgery and contributed to PCS.
- The most common type of early PCS was bile leak (16%).
- Age and previous abdominal surgeries were not significant predictors.

**Keywords:** Abdominal pain, Acute cholecystitis, Analysis, Bile duct injury, Calot's triangle, Cholecystostomy, Cholelithiasis, Gallstone, Laparoscopic cholecystectomy, Tokyo guidelines.

*World Journal of Laparoscopic Surgery* (2024): 10.5005/jp-journals-10033-1605

## INTRODUCTION

Most outpatient department (OPD) patients of the Department of Surgery come with an incidental imaging finding of gallstone disease or complications.<sup>1</sup> The incidence and presentation vary between genders, races, ethnicities, and geographical locations.

The threshold levels with the dilemma of operating an incidentally found gallstone varies between various centers and their operating surgeons with some having a conservative, while others having a surgical approach irrespective of textbook indications of gallbladder (GB) removal.

With the advent of modern imaging systems and laparoscopic methods of surgery, the incidence of cholecystectomy increased making it a daycare surgery in patients of good performance scale hence causing a major impact on health care costs.<sup>2</sup> Symptomatic patients most of the time benefit from a cholecystectomy.<sup>3,4</sup>

Postcholecystectomy syndrome encompasses a wide variety of symptoms ranging from abdominal pain to jaundice and indicates its persistence despite surgery, hence indicating an alternate preoperative diagnosis that might coincide with gallstone disease such as acute or chronic cholecystitis, pancreatitis, or common bile duct (CBD) obstruction.

Since the entry of laparoscopy, its judicious use needs to be defined. Contrast to open surgeries, using minimal incisions, have also been highlighted.<sup>5-7</sup>

<sup>1</sup>Department of General Surgery, SCB Medical College & Hospital, Cuttack, Odisha, India

<sup>2</sup>Department of Medicine and General Surgery, Veer Surendra Sai Institute of Medical Sciences and Research, Burla, Odisha, India

**Corresponding Author:** Sayed Mohammed Asfaque Aamir, Department of General Surgery, SCB Medical College & Hospital, Cuttack, Odisha, India, Phone: +91 8249262652, e-mail: cruisemi003@gmail.com

**How to cite this article:** Aamir SMA, Acharya S. Evaluation of Perioperative Factors for Prediction of Postcholecystectomy Syndromes. *World J Lap Surg* 2024;17(1):23–27.

**Source of support:** Nil

**Conflict of interest:** None

## AIM AND OBJECTIVES

The study was designed to find the significant perioperative factors contributing to Postcholecystectomy symptoms after laparoscopic cholecystectomy.

## METHODOLOGY

### Study Methods

Fifty patients who presented with postcholecystectomy symptoms to surgery OPD and Casualty of SCB Medical College & Hospital,

a tertiary hospital in Odisha, India in between January 2021 and November 2022 were evaluated.

The patients had previously undergone laparoscopic cholecystectomy electively or in an emergency setting after admission to hospital for acute emergency relating to gallstones. Perioperative Clinical and Radiological Features were analyzed.

### Inclusion Criteria

- Symptomatic patients presenting to the OPD following cholecystectomy.
- Patients whose preoperative ultrasonography (USG) and liver function test (LFT) were performed.
- Age, 18 years.

### Exclusion Criteria

- Patients who were uncooperative.
- Below 18 years of age.
- Prophylactic cholecystectomy done with a primary procedure.
- Patients without complete documents of operated procedure.

The patients were evaluated routinely with the following:

- Routine investigation was done in all patients.
- Radiological investigations – USG of abdomen and pelvis, magnetic resonance pancreaticography in all patients.
- Endoscopy was done in 48 patients.

Data were analyzed using the statistical package for the social sciences (SPSS), version 2.0, software and Chi-square test was used to measure the association.

## RESULTS

### Sex Distribution

- Fifty patients were taken up for the study.
- Most of our patients in the study were females (70%).

### Age Distribution

The most aged patient in our study group was 62 years. Most patients in our study group were between 31 and 40 years.

### Postoperative Symptoms

- Intermittent episodic colicky pain (<20 minutes) in the upper abdomen was the most common complaint.
- The other parameters are equally distributed.

### Etiological Factors

Etiology contributing to the postcholecystectomy syndromes were divided into biliary and nonbiliary factors.

### Perioperative Clinical Factors

- The following tabulated risk factors were taken into consideration.
- A total of 23 patients had previously undergone endoscopic retrograde cholangiopancreatography (ERCP) for choledocholithiasis.
- A total of 11 patients gave history of delayed surgery.
- A total of 15 patients had an elevated body mass index (BMI) (>25).
- Two patients had previous attacks of cholangitis.

### Perioperative Radiological Factors

- A total of 20 patients had a thickened GB wall.
- Pericholecystic fluid collection was present in eight individuals.

**Table 1: Age distribution**

Age (years)	Frequency (N)	%
18–30	14	28.0
31–40	15	30.0
41–50	12	24.0
51–60	09	18.0
61–70	00	00
>70	00	00
Total	50	100.0

- Eight patients had multiple stones.
- Three patients had a cystic duct stump above 2 cm.

### Intraoperative Findings

- A total of 35 patients had a contracted GB.
- One patient had a porcelain GB.
- Two patients had Mirizzi syndrome.
- Four patients had acute biliary pancreatitis.

### Operative Outcomes

- A total of 11 patients had a prolonged duration.
- Seven patients had an intraoperative bleeding above 50 mL.
- A total of 22 patients had a difficult GB dissection.
- A total of 21 patients had a difficult extraction of specimen.
- Seven patients had to undergo conversion to open cholecystectomy (OC).

## SIGNIFICANT ASSOCIATION

### Significant Association of Clinical History Factors

- Pancreatitis ( $p = 0.02$ )
- Peptic ulcer ( $p = 0.004$ )
- Gastritis ( $p = 0.05$ )
- Cholangitis ( $p = 0.05$ )
- Cirrhosis ( $p = 0.03$ )
- Delayed surgery ( $p = 0.03$ )
- Body mass index >27.5 ( $p = 0.02$ )

### Significant Association of Clinical and Radiological Features

- Palpable GB ( $p = 0.05$ )
- Recurrent CBD stones ( $p = 0.02$ )
- Stone impaction ( $p = 0.03$ )
- Pericholecystic fluid ( $p = 0.002$ )
- Thick GB wall ( $p = 0.01$ )

### Significant Association of Perioperative Factors

- Contracted GB ( $p = 0.02$ )
- Conversion to open surgery ( $p = 0.05$ )
- Significant intraoperative blood loss ( $p = 0.01$ )
- Difficult GB dissection ( $p = 0.04$ )
- Difficult peritoneal access ( $p = 0.02$ )

## DISCUSSION

### Age Distribution

- Most of our patients age spectrum were within the 31–40-year category (Table 1).
- As per our study, the age of the patient was not a significant predictor of postcholecystectomy syndrome.

**Table 2:** Types of postoperative symptoms and frequency

Symptoms	Male (N = 15)	Female (N = 35)	Total
Pain			
• Epigastric	02 (13.3%)	10 (28.6%)	12 (24.0%)
• Right hypochondrium	13 (86.7%)	25 (71.4%)	38 (76.0%)
Type of pain			
• Colicky	13 (86.6%)	23 (65.7%)	36 (72.0%)
• Gripping	01 (6.7%)	04 (11.4%)	05 (10.0%)
• Dull aching	01 (6.7%)	08 (22.9%)	09 (18.0%)
Radiation to back			
• Present	04 (26.7%)	10 (28.6%)	14 (28.0%)
• Absent	11 (73.3%)	25 (71.4%)	36 (72.0%)
Duration of pain (in months)			
• <6 months	04 (26.7%)	06 (17.1%)	10 (20.0%)
• ≥6 months	11 (73.3%)	29 (82.9%)	40 (80.0%)
Vomiting	08 (53.3%)	10 (28.6%)	18 (36.0%)
Fever	01 (6.7%)	05 (14.3%)	06 (12.0%)
Dyspepsia/bloating	01 (6.7%)	09 (25.7%)	10 (20.0%)

### Gender Distribution

Major chunk of our samples were incidentally females (35/50) which signified a female predisposition of postcholecystectomy syndrome.

### Presenting Complaints

#### Pain

Pain was the most common symptom in our study group present in all the members. All patients presented with nonresolution of pain post-surgery (Table 2). About 82% of patients presented with right colicky hypochondrial pain. Failure of proper preoperative evaluation to rule out gastritis and pancreatitis was the major nonbiliary factor

Weinert et al.,<sup>8</sup> in his study, found that pain was the most common symptom followed by nausea-vomiting and jaundice.

#### Vomiting

Patients presented with spontaneous vomiting in 38% of the patients during episodes of pain (Table 2). Disease severity was indicated by vomiting. Localized or diffuse Peritonitis due to Bile Leak causing Ileus was the established cause.

#### Dyspepsia

A total of 22% of the patients presented with dyspepsia (Table 2).

On upper gastrointestinal endoscopy (UGIE), three of them had duodenal ulceration.

Gastritis, gastroesophageal reflux disease (GERD), aerophagia, use of nonsteroidal anti-inflammatory drugs (NSAIDs) may coexist with cholelithiasis.

#### Fever

Fever was present in 12% of the patients (Table 2) which was associated with chills and rigors due to cholangitis launching a systemic inflammatory response syndrome (SIRS).

In our study, febrile patients were associated with a thickened GB wall and pericholecystic fluid collection and those patients subsequently had a difficult cholecystectomy.

Hence, fever was a strong predictor of PCS in our study design.

**Table 3:** Etiology

Etiological factors			
	Frequency [N(%)]	Nonbiliary factors	Frequency [N(%)]
<i>Biliary factors</i>			
Recurrent CBD stone	03 (6.0%)	Gastritis	42 (84.0%)
Retained CBD stone	06 (12.0%)	Pancreatitis	02 (4.0%)
CBD stricture	02 (4.0%)	Peptic ulcer	19 (38.0%)
Bile leakage	08 (16.0%)	No obstructive cause	06 (12.0%)
Sphincter of Oddi dysfunction	03 (6.0%)		

**Table 4:** Perioperative clinical risk factors

Risk factors	Frequency (N)	%
History of ERCP	23	46
Obesity	15	30
Delayed surgery (>6 weeks)	11	22
Attack of cholecystitis	16	32
Raised BMI	15	30
Previous abdominal symptoms	15	30
Liver cirrhosis	07	14
History of acute cholangitis/pancreatitis	02	4
Previous t/t (percutaneous drainage)	00	00

t/t, treatment

### Etiology

After patient evaluation, we found the following:

- Bile Leak was found in 16% of the patients as the most common biliary etiology (Table 3).
- Gastritis was the most common (84%) nonbiliary etiology (Table 3).

### History

Of the 50 patients, 2 had undergone lower segment cesarean section (LSCS), 11 had undergone tubectomy, 1 had undergone hysterectomy, 1 had undergone appendectomy, and 1 patient presented with obstructive jaundice due to CBD calculus, and he underwent ERCP with CBD stenting (Table 4).

Three patients had attack of acute cholecystitis which required hospitalization and were managed conservatively. One patient had acute pancreatitis and was treated conservatively with hospitalization.

In our study design, history of previous abdominal surgeries did not correlate to the development of PCS symptoms.

History of previous hospitalization due to an attack of acute cholecystitis was a significant predictor in my study design.

### General Physical Examination

Obesity (BMI >30 kg/m<sup>2</sup>) correlated with a problematic access to peritoneal cavity to achieve a pneumoperitoneum ( $p = 0.05$ ) and difficult specimen retrieval thus corresponding to a difficult cholecystectomy (Table 4).

### Ultrasonography

Preoperative ultrasound data were evaluated in all the patients.

As per our study design, preoperative ultrasound with thickened GB wall with pericholecystic fluid (Table 5) was a strong predictor of PCS due to a difficult laparoscopic cholecystectomy.

**Table 5:** Preoperative radiology findings

Parameters	Frequency (N)	%
Thick-walled GB (>4 mm)	20	40
Contracted GB	09	18
Packed stone	08	16
Polyp	05	10
Evidence of acute cholecystitis		
• Edematous GB	10	20
• Pericholecystic fluid collection	08	16
• Air in GB (emphysematous cholecystitis)	00	
• Subphrenic collection	00	
• Intraperitoneal fluid collection	01	2
Fatty liver with hepatomegaly	05	10
Liver cirrhosis	07	14
Portal vein thrombosis (PV)	01	2

**Table 6:** Intraoperative findings

Parameters	Frequency (N)	%
Mucocele	3	6
Gangrenous GB	4	8
Contracted GB	35	70
Mirizzi syndrome	2	4
Porcelain GB	1	2
Cholecystoenteric fistula	1	2
Acute biliary pancreatitis	4	8

**Table 7:** Operative outcomes

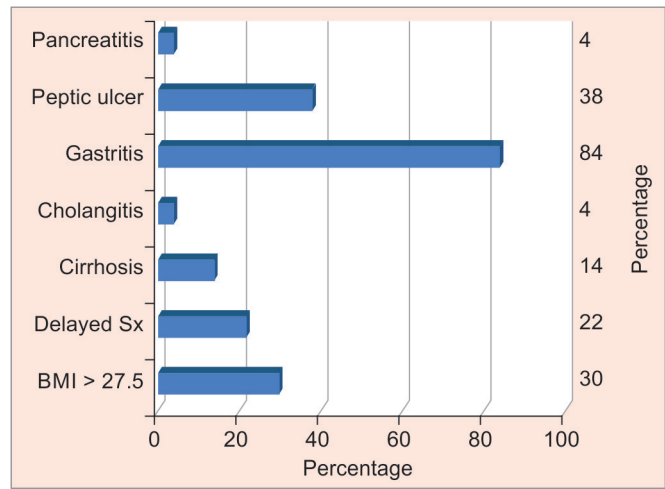
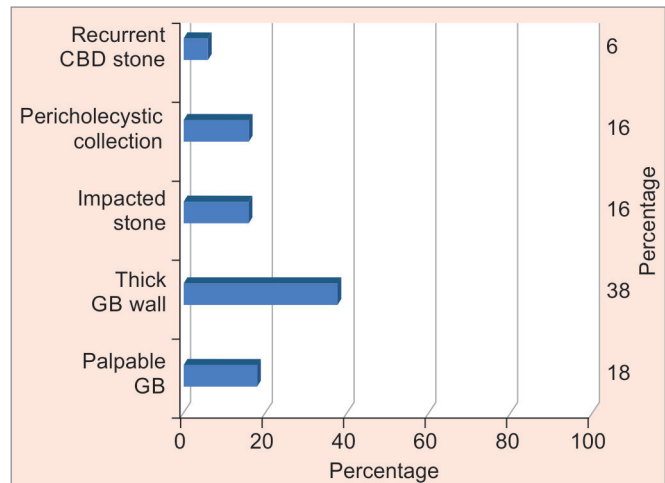
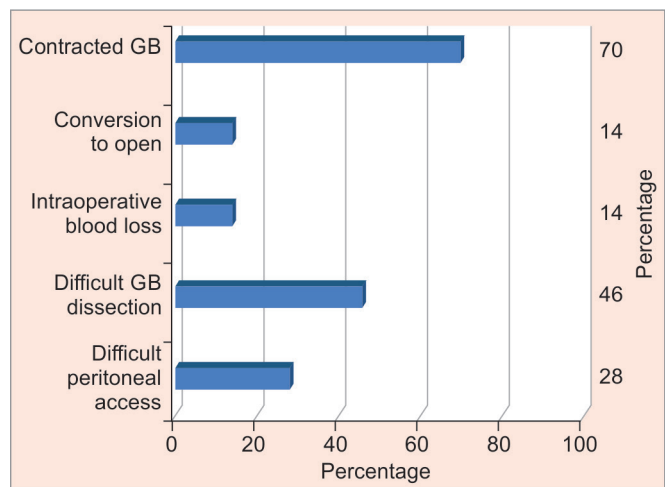
Parameters	Frequency (N)	%
Duration of surgery, above 1 hour	11	22
Bleeding during symptoms, above 50 mL	07	14
Difficult peritoneal access	14	28
Difficult dissection	22	44
Difficult extraction	21	42
Conversion to OC	07	14

### Intraoperative and Outcomes

The most common intraoperative pathology found in patients presenting with PCS was a contracted GB (Table 6) causing inadequate Calot's Triangulation and difficulty in dissection (Table 7).

### CONCLUSION

- The cardinal symptom in our study population was pain (100%).
- Female sex (70%) and BMI (30%) were strong significant predictors.
- History of hospital admission ( $p < 0.0008$ ) for an acute attack of cholecystitis (32%), acute pancreatitis (4%), surgical jaundice (18%), cirrhosis (14%) were significant predictors of PCS (Fig. 1).
- Ultrasonography findings ( $p < 0.0471$ ) of thickened GB wall (40%) and pericholecystic collection (16%) (Fig. 2) with a contracted GB with difficult dissection (Fig. 3) were strong predictors of difficult surgery and contribute to PCS.
- The most common type of early PCS was bile leak (16%).
- Age and previous abdominal surgeries were not significant predictors.


**Fig. 1:** Percentages of patients with significant history findings

**Fig. 2:** Percentages of patients with significant radiological findings

**Fig. 3:** Percentages of patients with significant intraoperative factors

- Patients should be educated about the postoperative course of the surgery and should be counseled about the possibility of the persistence of symptoms.



- Communication between the patient and surgeon regarding frequently associated postoperative problems will help reveal subtle symptoms of PCS.
- Postoperatively, colonic symptoms show poor resolution.
- Patients with colonic symptoms had a history of neuroses such as depression and history of antidepressant intake.
- So, those with a history of psychotropic drugs intake may have a silent GB calculi and irritable bowel syndrome. This subset of patients do not recover from laparoscopic cholecystectomy.
- Hence, it is important to analyze the perioperative factors that can predispose to postcholecystectomy syndromes.

## ORCID

Syed Mohammed Asfaque Aamir  <https://orcid.org/0009-0007-5103-1711>

Sattwik Acharya  <https://orcid.org/0009-0000-3404-2258>

## REFERENCES

1. Loria P, Dilengite MA, Bozzoli M, et al. Prevalence rates of gallstone disease in Italy. The Chianciano population study. *Eur J Epidemiol* 1994;10(2):143–150. DOI: 10.1007/BF01730363.
2. Escarce JJ, Chen W, Schwartz JS. Falling cholecystectomy thresholds since the introduction of laparoscopic cholecystectomy. *JAMA* 1995;273(20):1581–1585. PMID: 7745770.
3. Peterli R, Schuppiesser JP, Herzog U, et al. Prevalence of postcholecystectomy symptoms: Long-term outcome after open versus laparoscopic cholecystectomy. *World J Surg* 2000;24(10):1232–1235. DOI: 10.1007/s002680010243.
4. Konsten J, Gouma DJ, von Meyenfeldt MF, et al. Long-term follow-up after open cholecystectomy. *Br J Surg* 1993;80(1):100–102. DOI: 10.1002/bjs.1800800132.
5. Harju J, Juvonen P, Eskelinen M, et al. Minilaparotomy cholecystectomy versus laparoscopic cholecystectomy: A randomized study with special reference to obesity. *Surg Endosc* 2006;20(4):583–586. DOI: 10.1007/s00464-004-2280-6.
6. Rosenberg J, Leinskold T. Dome down laparoscopic cholecystectomy. *Scand J Surg* 2004;93(1):48–51. DOI: 10.1177/145749690409300110.
7. Shamiyeh A, Wayand W. Current status of laparoscopic therapy of cholecystolithiasis and common bile duct stones. *Dig Dis* 2005;23(2):119–126. DOI: 10.1159/000088593.
8. Weinert CR, Arnett D, Jacobs D Jr, et al. Relationship between persistence of abdominal symptoms and outcome after cholecystectomy. *Arch Intern Med* 2000;160(7):989–995. DOI: 10.1001/archinte.160.7.989.

# Hysteroscopy, an Essential Adjunct to Laparoscopy, in Evaluation of Women with Chronic Pelvic Pain

Vinita Sarbhai<sup>1</sup>, Preeti<sup>2</sup>

Received on: 13 September 2023; Accepted on: 27 October 2023; Published on: 14 February 2024

## ABSTRACT

**Introduction:** Chronic pelvic pain (CPP) is a significant contributor to morbidity in women, accounting for 10–20% of all visits to gynecology outpatient department (OPD). Evaluating CPP remains a challenge due to its broad and multifactorial etiology. While laparoscopy is considered the gold standard for diagnosing CPP, it may overlook intrauterine causes. Hysteroscopy, on the other hand, provides an internal view for diagnosing intrauterine pathologies.

**Aim and objectives:** This study aims to assess the role of hysteroscopy as a complementary procedure with laparoscopy in the evaluation of women with CPP.

**Materials and methods:** This study was conducted at the Department of Obstetrics and Gynaecology in Kasturba Hospital, New Delhi, India. From January 2017 to March 2020, 50 women with CPP lasting more than six months underwent hysteroscopy in conjunction with laparoscopy. They were assessed for the causes of CPP and potential treatment options.

**Results:** Hysteroscopy identified abnormalities in 24 (48%) of the patients. Among them, 9 (18%) had intrauterine adhesions, 6 (12%) had a partial septum, 4 (8%) had internal os stenosis, 4 (8%) had fibroids, 3 (6%) had polyps, and 2 (4%) had chronic pelvic inflammatory disease (PID) (with overlapping findings). These pathologies went undetected during laparoscopy. However, laparoscopy successfully diagnosed other intra-abdominal causes of CPP, including adhesions in 34%, endometriosis in 28%, chronic PID in 24%, fibroids in 12%, genital/abdominal Koch's in 6%, dermoid cysts, and other ovarian cysts in 4% each, and paraovarian cysts in 2%. In the same procedure, concurrent therapeutic interventions such as adhesiolysis (18%), cervical dilatation (8%), septal resection (6%), and polypectomy (4%) were performed using an operative hysteroscope.

**Conclusion:** Hysteroscopy proved effective in identifying various intrauterine causes of CPP. It serves as a valuable adjunct to laparoscopy for diagnosing conditions affecting the cervix and uterine cavity, which can often coexist with the underlying causes of CPP.

**Keywords:** Chronic pelvic pain, Diagnostic laparoscopy, Hysterectomy, Hysteroscopy, Laparoscopic surgery, Polyp, Uterine abnormality.

*World Journal of Laparoscopic Surgery* (2024): 10.5005/jp-journals-10033-1597

## INTRODUCTION

Chronic pelvic pain (CPP) is a significant source of morbidity among women, especially in the reproductive age-group. The American College of Obstetricians and Gynecologists (ACOG) defines CPP as noncyclical pain in the pelvic region, severe enough to require medical attention, and located below the umbilicus. This pain can manifest in the anterior abdominal wall, lumbosacral back, or buttocks, and last for a minimum of six months.<sup>1</sup> Also, CPP is associated with a reduced quality of life, fatigue, depression, anxiety, and marital and sexual dysfunction.<sup>2</sup> It accounts for 10–20% of all visits to gynecology outpatient department (OPD).<sup>3</sup>

Evaluating CPP remains challenging due to its wide and multifactorial etiology. Common gynecological pathologies that may present with CPP include endometriosis, adenomyosis, ovarian cysts, pelvic inflammatory disease (PID), polyps, adhesions, fibroids, genital tuberculosis, pelvic congestion, paraovarian masses, and hydrosalpinx, among others. While laparoscopy is considered the gold standard for diagnosing CPP, it may not always detect intrauterine causes like polyps and adhesions.

Hysteroscopy enables direct visualization of the uterus and can uncover various abnormalities such as polyps, leiomyomas [the International Federation of Gynecology and Obstetrics (FIGO) class 0–3], uterine adhesions, a stenotic cervix, and abnormal uterine

<sup>1</sup>Department of Gynaecology and Obstetrics, Kasturba Hospital, New Delhi, India

<sup>2</sup>Department of Gynaecology and Obstetrics, Lok Nayak Hospital, New Delhi, India

**Corresponding Author:** Vinita Sarbhai, Department of Gynaecology and Obstetrics, Kasturba Hospital, New Delhi, India, Phone: +91 9810359546, e-mail: vinitasarbhai@gmail.com

**How to cite this article:** Sarbhai V, Preeti. Hysteroscopy, an Essential Adjunct to Laparoscopy, in Evaluation of Women with Chronic Pelvic Pain. *World J Lap Surg* 2024;17(1):28–32.

**Source of support:** Nil

**Conflict of interest:** None

formations, all of which can be underlying causes of CPP. These findings are often overlooked during transvaginal sonography (TVS) and laparoscopy. Moreover, hysteroscopy offers the possibility of obtaining histological specimens and, in some cases, provides a means to treat the underlying cause. Due to the limited available data on the utility of hysteroscopy as a diagnostic tool for CPP, this study was conducted to assess its role as a complementary modality alongside laparoscopy in the evaluation of women suffering from CPP.

**Table 1:** Diagnosis on the basis of laparoscopic findings\*

Diagnosis	Frequency	Percentage	Operation performed
Adhesions	17	34	Adhesiolysis (34%)
Endometriosis	14	28	Ablation of endometriotic spots with cystectomy (22%)
Chronic PID	12	24	Drainage of pyosalpinx
Fibroid	6	12	Nil
Koch's pathology	3	6	Antitubercular treatment (ATT) started
Dermoid cyst	2	4	Cystectomy (4%)
Ovarian cyst	2	4	Cystectomy (4%)
Paraovarian cyst	1	2	Cystectomy (2%)
No cause	13	26	Nil

\*With overlapping pathologies

**Table 2:** Provisional diagnosis and treatment imparted on hysteroscopy\*

Diagnosis	Frequency	Percentage	Operation
Intrauterine adhesions	9	18	Adhesiolysis (9)
Partial septum	6	12	Resection of septum (3)
Internal os stenosis	4	8	Sharp dissection (4)
Fibroid	4	8	No intervention (4)
Polyp	3	6	Polypectomy (2)
Chronic PID	2	4	No intervention (2)
No cause	26	52	No intervention (26)

\*Many findings were overlapping

## MATERIALS AND METHODS

This study was carried out at the Department of Obstetrics and Gynaecology in Kasturba Hospital, New Delhi, India after approval from the Institutional Ethics Committee. We enrolled 50 women who presented with CPP lasting more than six months, between January 2017 and March 2020.

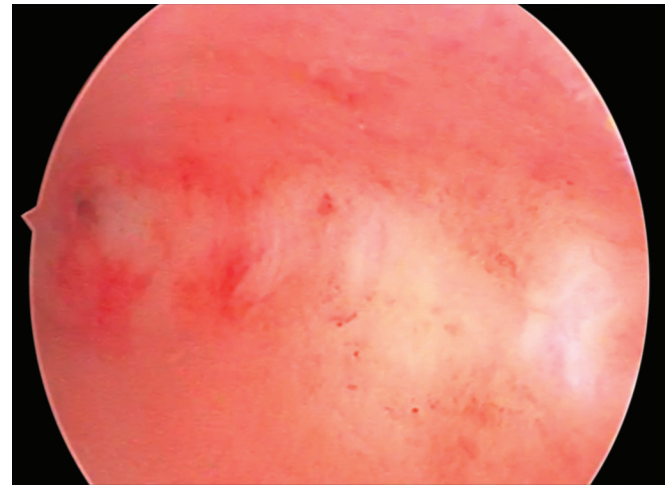
We meticulously documented the clinical symptoms, presentations, and pelvic examination findings of these patients. Subsequently, these patients underwent hysteroscopy in conjunction with laparoscopy after undergoing detailed Transvaginal ultrasonography. We recorded the operative findings during hysteroscopy and laparoscopy, as well as the follow-up data.

## RESULTS

The mean age of the 50 patients presenting with CPP was 28.18 years. The majority of them reported experiencing dull aching pain (74%). Infertility was the most frequently associated complaint, observed in 46% of cases. Other accompanying complaints included menstrual disorders (30%), vaginal discharge (28%), dyspareunia (22%), and dysmenorrhea (28%). Ultrasonography was performed on all of the patients, revealing anatomical factors in the uterus that could lead to CPP in 11 individuals (22%). Among them, 8 (16%) had fibroids, and 1 (2%) had polyps. Additionally, 2 (4%) patients displayed congenital uterine abnormalities on TVS, with 1 having a partial septum and the other having an arcuate uterus. Regarding tubal or ovarian factors, 15 patients (30%) exhibited ovarian cysts, 3 (6%) had hydrosalpinx, and 4 (8%) had tubo-ovarian masses detected through ultrasound.

Laparoscopy successfully diagnosed the intra-abdominal causes of CPP, including adhesions in 34%, endometriosis in 28%, chronic PID in 24%, fibroids in 12%, genital/abdominal Koch's in 6%, dermoid cysts, and other ovarian cysts in 4% each, and paraovarian cysts in 2% (Table 1).

On hysteroscopy, intrauterine adhesions were seen in 9 (18%) patients, fibroids in 4 (8%) patients, internal os stenosis in 4 (8%) cases, polyps in 3 (6%) patients, and bilateral ostia were not visualized in 6 (12%), Atrophic epithelium in 3 (6%) and hyperplastic epithelium in 2 (4%) patients. Congenital malformations of the uterus were seen in 7 (14%) patients among whom 6 (12%) presented with partial septum and 1 (2%) had an arcuate uterus. Endometrial curettage was performed for patients with hyperplastic epithelium.



**Fig. 1:** Cornual phimosis with fundal adhesions

Inflammatory cells in the endometrium were indicative of chronic PID in 4% of patients. No pathology was detected in 52% of patients. (Table 2).

Intrauterine adhesions were observed in nine cases (18%). Among these, fine-thin adhesions were found in five patients, while four patients had dense adhesions. Notably, one patient with dense adhesions had previously undergone a hysteroscopic myomectomy. Out of the nine patients with intrauterine adhesions, two had a tubular cavity due to the presence of dense adhesions. Internal os stenosis was identified by the difficulty in introducing the hysteroscope due to adhesions and was encountered in four patients.

These adhesions also caused the obliteration of the ostia (Fig. 1). In six patients (12%), bilateral ostia could not be visualized. Among them, four patients (8%) had fibrosed ostia with adhesions covering them, and two patients had ostia that couldn't be visualized due to a partial septum.

Adhesiolysis was performed in all these patients using sharp dissections with hysteroscopic scissors until the pinkish underlying endometrium, which bleeds, was reached (Fig. 2). In one patient, an intrauterine Foley catheter was kept in place for four days. All patients received estrogen therapy.

Partial septum was observed in six patients (12%), protruding from the fundus (Fig. 3). Among them, three patients had septa measuring around 3 cm, and three patients had small septa (<2 cm) protruding from the fundus. One patient had an arcuate uterus,

which was identified by an indentation of the fundus. Resection of the partial septum was performed in 3 patients (6%) with septa larger than 3 cm, while it was not carried out in women with small septa measuring less than 2 cm.

Uterine polyps were detected in three patients (6%). One small polyp, measuring 1 cm, was found near the posterior cornua

in one patient, and fundal polyps (2 cm) were observed in two patients. Polypectomy was performed in two patients with larger polyps.

Fibroids, which presented as firm bulges protruding into the cavity, were identified in four patients (8%). Endometrial curettage was performed in 4% of patients with hyperplastic endometrium, and the samples were sent for histopathological examination. The reports confirmed the presence of inflammation. Fortunately, none of the patients experienced any complications during hysteroscopy or operative procedures.

## DISCUSSION

Chronic pelvic pain is a major contributor to morbidity among women, significantly affecting their well-being and causing distress and disability. Identifying the precise cause of CPP is crucial to prevent patients from undergoing unnecessary treatments and enduring endless referrals. While laparoscopy is a standard part of the protocol for evaluating CPP, hysteroscopy is often overlooked. Intrauterine pathologies, such as polyps, mullerian anomalies, sub-mucous fibroids, and intrauterine adhesions, can be challenging to diagnose using TVS and laparoscopy, leading to their frequent omission.

In the present study, hysteroscopy revealed various pathologies in patients with CPP. Intrauterine adhesions were the most common, seen in 18% of patients, followed by fibroids in 8%, internal os stenosis in another 8%, polyps in 6%, the absence of bilateral ostia visualization in 12%, atrophic epithelium in 6%, and hyperplastic epithelium in 4% of patients. Additionally, congenital uterine malformations were identified in 14% of patients, with 12% having a partial septum and 2% having an arcuate uterus. Hysteroscopy successfully identified pathologies that were missed during TVS, including internal os stenosis, polyps, mullerian anomalies, bilateral ostial block, atrophic epithelium, and intrauterine adhesions. Furthermore, it revealed cases with overlapping pathologies that were not detected by laparoscopy or TVS (Table 3).

The findings in our study closely parallel those of Boruah S and Phukan P,<sup>4</sup> where out of 61 patients, 15% had polyps, 12% had fibroids, 10% had intrauterine adhesions, 7% had atrophic endometrium, 19% had adenomyosis, and 8% had uterine malformations. Their study concluded that hysteroscopy plays a significant role in identifying the causes of CPP.

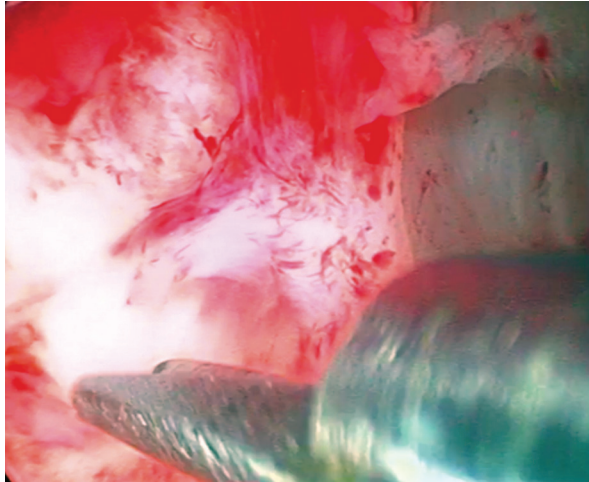


Fig 2: Adhesiolysis of intrauterine adhesions

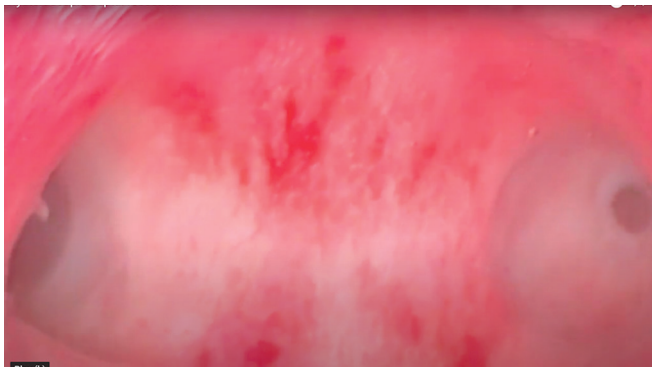


Fig. 3: Partial septum in uterine cavity

Table 3: Comparison of clinical, TVS, and final diagnosis

Diagnosis	TVS	Hysteroscopy	Laparoscopy	Final diagnosis on hysteroscopy
Adhesions	0	9 (18%)	17 (34%)	17 (34%)
Endometriosis	6 (12%)	0	14 (28%)	14 (28%)
Chronic PID	7 (14%)	2 (4%)	12 (24%)	12 (24%)
Fibroid	8 (16%)	4 (8%)	6 (12%)	9 (18%)
Koch's pathology	0	0	3 (6%)	3 (6%)
Polyp	1 (2%)	3 (6%)	0	3 (6%)
Internal os stenosis	0	4 (2%)	0	4 (8%)
Dermoid cyst	2 (4%)	0	2 (4%)	2 (4%)
Ovarian cyst	10 (20%)	0	2 (4%)	2 (4%)
Paraovarian cyst	0%	0	1(2%)	1 (2%)
No cause	18 (36%)	26 (52%)	13 (26%)	11 (22%)



Similar results were observed in a study by Carter JE,<sup>5</sup> which documented abnormal findings during hysterolaparoscopy in 140 patients. In this study, fibroids were seen in 18% of patients, intrauterine polyps in 6.4%, cervical stenosis in 2.9%, intrauterine scarring in 2.1%, and a bicornuate uterus in 0.7%. Combining hysterolaparoscopy helped identify overlapping pathologies contributing to CPP, such as endometriosis and adhesions in 13%, endometriosis and fibroid in 15%, and fibroid and adhesions in 3%. Therefore, combined hysterolaparoscopy offers significant advantages over laparoscopy alone in identifying the causes of pelvic pain. The study also highlighted the role of submucous leiomyomas and polyps (24.4%) in causing chronic pain by distorting the endometrial cavity chronically. Consequently, the conclusion was that hysteroscopy should be routinely performed in women with CPP, as abnormalities are present in 30% of these patients.

Similar findings were observed in a study conducted by Dias BHM et al.,<sup>6</sup> where out of 191 patients, 51.8% were diagnosed with some form of pathology during hysteroscopy. Among them, 23% had cervical stenosis, 15% had polyps, 12% had submucosal fibroids, 10% had intrauterine adhesions, 8% had mullerian anomalies, and 7% had atrophic endometrium. In total, pathologies were identified in 51.83% of the patients during hysteroscopy. The study highlighted that cervical stenosis is a significant contributor to CPP and has a strong association with endometriosis and/or PID. Cervical stenosis can lead to retrograde menstrual flow through the fallopian tubes, particularly when it's present. The narrowing of the cervical canal restricts the outflow of menstrual blood during the shedding of the epithelium, leading to blood accumulation in the cavity. This, combined with menstrual cramps, can result in the reflux of material into the abdominal cavity. Cervical stenosis was observed in 4 patients in our present study.

In our study, hysteroscopy revealed fibroids in four patients (8%) and polyps in three patients (6%). Both fibroids and polyps can induce pain by chronically distorting the endometrial cavity. Large polyps and submucosal myomas, in particular, may cause pain, especially when the uterus attempts to expel them through contractions.

The presence of endometrial hyperplasia with micropolymp formation is suggestive of chronic PID, which is a major contributor to CPP in our country. Endometrial sampling can be sent for acid-fast bacilli (AFB) testing and cytology, allowing for the exclusion of tuberculosis-related pathology and endometrial cancer.

Atrophic endometrium can suggest damage resulting from chronic PID or repeated dilatation and curettage (D&C) procedures. Intrauterine adhesions may indicate chronic PID, tuberculosis, the aftermath of D&C, or previous surgical interventions. These adhesions can lead to the distortion of the uterine cavity, contributing to CPP.

Although a partial septum itself may not directly cause CPP, its presence can become relevant when associated with endometriosis. Nawroth et al.<sup>7</sup> reported a significantly higher incidence of endometriosis in patients with a septate uterus, suggesting that in such cases, a combined hysteroscopy and laparoscopy should be considered. Further, larger studies could confirm this association, potentially supporting surgical intervention for CPP. In clinical practice, hysteroscopic resection of the uterine septum (even without laparoscopic endometriosis treatment) often leads to a significant improvement or complete resolution of severe dysmenorrhea.

Hysteroscopy proved invaluable in our study by detecting pathologies that were missed by TVS or laparoscopy. Internal os stenosis, a significant cause of CPP, remained entirely undetected by TVS or laparoscopy. Additionally, polyps, mullerian anomalies, bilateral ostial block, atrophic epithelium, and intrauterine adhesions were all overlooked during TVS or laparoscopy.

Another significant advantage of hysteroscopy is its capability to directly sample and treat abnormalities, enabling early diagnosis and simultaneous intervention. In our study involving 50 patients, a substantial portion (74%) did not require any operative intervention during hysteroscopy. However, some patients required multiple procedures due to overlapping findings. The most common procedure performed was adhesiolysis in seven patients (14%), followed by cervical os dilation in four patients (8%). Polypectomy was conducted in 2 patients with polyps measuring 2 cm in size.

In the present study, resection of the partial septum was performed in three patients (6%), while an impressive 74% of patients did not require any operative intervention during hysteroscopy. Some patients needed more than one procedure due to overlapping findings, and importantly, no complications or perforations were noted.

Conducting interventions simultaneously during hysteroscopy leads to reduced morbidity, increased patient satisfaction, and an improved quality of life. Hysteroscopy is not only cost-effective but also carries a low risk of complications when performed by qualified professionals. It provides direct visualization of the uterine cavity, facilitating the detection of abnormalities. As a complementary diagnostic tool for intrauterine pathologies related to CPP, hysteroscopy allows for therapeutic interventions to be performed simultaneously, making it a valuable procedure.

## CONCLUSION

Hysteroscopy proves to be an invaluable complementary methodology in diagnosing intrauterine pathologies associated with CPP. The ability to perform concomitant therapeutic interventions such as adhesiolysis, polypectomy, and septal resection through operative hysteroscopy greatly enhances its utility.

Traditionally, laparoscopy has been the cornerstone for diagnosing CPP. However, based on our findings, we strongly recommend that hysteroscopy be regarded as an extremely useful adjunct to laparoscopy. Combining hysteroscopy and laparoscopy, known as combined hysterolaparoscopy, should be considered the gold standard for the evaluation of CPP, following a comprehensive assessment and screening using TVS.

## REFERENCES

1. ACOG Committee on Practice Bulletins—Gynecology. ACOG practice bulletin no. 51. Chronic pelvic pain. *Obstet Gynecol* 2004;103(3): 589–605. PMID: 14990428.
2. Ayorinde AA, Macfarlane GJ, Saraswat L, et al. Chronic pelvic pain in women: An epidemiological perspective. *Womens Health (Lond)* 2015;11(6):851–864. DOI: 10.2217/whe.15.30.
3. Howard FM. The role of laparoscopy in chronic pelvic pain: Promise and pitfalls. *Obstet Gynecol Surv* 1993;48(6):357–387. DOI: 10.1097/00006254-199306000-00001.
4. Boruah S, Phukan P. Laparoscopic evaluation of chronic pelvic pain in women: Its present role and advantage over other diagnostic procedures. *J Evolution Med Dent Sci* 2016;5(13):560–563. DOI: 10.14260/jemds/2016/128.

5. Carter JE. Combined hysteroscopic and laparoscopic findings in patients with chronic pelvic pain. *J Am Assoc Gynecol Laparosc* 1994;2(1):43–47. DOI: 10.1016/s1074-3804(05)80830-8.
6. Dias BHM, de Andrade AC, da Silva AM, et al. Evaluation of hysteroscopy as a complementary exam in the investigation of chronic pelvic pain. *J Health Biol Sci* 2013;1(3):105. DOI: 10.12662/2317-3076jhbs.v1i3.29.p105.2013.
7. Nawroth F, Rahimi G, Nawroth C, et al. Is there an association between septate uterus and endometriosis? *Hum Reprod* 2006;21(2):542–544. DOI: 10.1093/humrep/dei344.

# Port Site Infiltration and Extraperitoneal Instillation of Ropivacaine in Totally Extraperitoneal Hernia Repair: A Randomized Controlled Trial

Sachin Jain<sup>1</sup>, Naveen Sharma<sup>2</sup>, Seema Singh<sup>3</sup>

Received on: 02 May 2023; Accepted on: 15 June 2023; Published on: 14 February 2024

## ABSTRACT

**Aim:** To evaluate the role of intraoperative local anesthetic use in the reduction of postoperative pain after totally extraperitoneal (TEP) hernia repair.

**Settings and design:** Teaching hospital in Delhi, RCT.

**Materials and methods:** 18–60-year-old men with unilateral inguinal hernia were randomized to either ropivacaine group (30) or placebo group (30) using a randomization sequence generated online. Port sites and preperitoneal space received either 0.75% ropivacaine or 0.9% saline (placebo). The primary outcome was numerical response scale (NRS) pain score at 6 hours after surgery. The secondary outcomes include NRS at 2 hours, 24 hours, and total analgesic requirement during the first postoperative week. The same surgeon using the same type of mesh performed all procedures using three midline ports and without mesh fixation. The patient, surgery team, and observer were blinded.

**Statistical analysis used:** Shapiro–Wilk test of normality, median test for independent samples.

**Results:** All patients underwent allocated procedure. There were no conversions. The baseline parameters were comparable in the two groups. The Shapiro–Wilk test of normality revealed that the data were not distributed normally. The median NRS at 6 hours was 3 (IQR 1, 3) in the ropivacaine group compared with 3 (IQR 1, 4) in the placebo group ( $p = 0.981$ , Independent samples median test). Similar comparable pain scores were obtained at 2 and 24 hours. No significant difference was noted in analgesic requirement in the first 24 hours, till postoperative day 7, time to ambulation or micturition between groups.

**Conclusions:** Infiltration of port sites and preperitoneal space with ropivacaine does not reduce postoperative pain or analgesic requirement in TEP.

**Clinical significance:** The use of local anesthetic agents intraoperatively has no added benefit in reducing postoperative pain in TEP hernia repair.

**Keywords:** Abdominal pain, Hernia, Hernioplasty, Inguinal hernia, Inguinal hernia repair, Laparoscopic, Laparoscopic hernia repair, Laparoscopic inguinal hernia repair, Postoperative pain, Randomized controlled trial.

*World Journal of Laparoscopic Surgery* (2024): 10.5005/jp-journals-10033-1602

## INTRODUCTION

Totally extraperitoneal (TEP) repair has been recommended as one of the two preferred treatment options in adult patients with unilateral inguinal hernia.<sup>1</sup> The technique has been refined over the last decade and the results have been found to be good in the hands of experienced surgeons. As most surgeons performing laparoscopic inguinal hernia repair are now using a mesh size of 15 × 10 cm or more, the recurrence rates have become very low.<sup>1</sup> Surgeons' efforts are now directed toward reducing early and late postoperative pain as this has a great impact on the patient's satisfaction. Local anesthetics are believed to reduce the postoperative pain when used intraoperatively in the surgical wound sites. The limited space developed in TEP laparoscopic inguinal hernia repair (provides an ideal setting for direct instillation of local anesthetic agent. When local anesthetic is injected intraoperatively at wound sites, it can serve to minimize the postoperative pain. A few studies have previously evaluated this question and some have found a remarkable decrease in the postoperative pain score.<sup>2–5</sup> Conversely, other studies have found no decrease in pain after infiltration of port sites or instillation of local anesthetic solution in the preperitoneal space.<sup>6–9</sup> Ropivacaine is a newer local anesthetic with a longer duration of action with a favorable side effect profile compared with older local anesthetic agents.<sup>10,11</sup> We performed this randomized

<sup>1</sup>Department of GI Surgery, Dharamshila Narayana Superspeciality Hospital, New Delhi, India

<sup>2</sup>Department of General Surgery, All India Institute of Medical Sciences, Jodhpur, Rajasthan, India

<sup>3</sup>Department of General Surgery, Rama Medical College, Hospital and Research Centre, Hapur, Uttar Pradesh, India

**Corresponding Author:** Sachin Jain, Department of GI Surgery, Dharamshila Narayana Superspeciality Hospital, New Delhi, India, Phone: +91 9654631321, e-mail: sachindoc09@gmail.com

**How to cite this article:** Jain S, Sharma N, Singh S. Port Site Infiltration and Extraperitoneal Instillation of Ropivacaine in Totally Extraperitoneal Hernia Repair: A Randomized Controlled Trial. *World J Lap Surg* 2024;17(1):33–37.

**Source of support:** Nil

**Conflict of interest:** None

**Patient consent statement:** The author(s) have obtained written informed consent from the patient(s) for publication of the research details and related images.

controlled trial to evaluate whether intraoperative use of local anesthetic (ropivacaine) in extraperitoneal space and in port sites in TEP mesh hernioplasty reduces postoperative pain.

## MATERIALS AND METHODS

The aim of this study was to compare the infiltration of port sites and instillation of extraperitoneal space with ropivacaine vs placebo for postoperative pain relief after TEP inguinal hernia repair. The primary objective was to compare the postoperative pain scores using numerical response scale (NRS) scoring at 6 hours (h) postoperatively. Secondary objectives were to compare the postoperative pain scores at 2 h and 24 h postoperatively using NRS and to determine the total analgesic requirement in postoperative period till postoperative day 7.

This randomized clinical trial was conducted from November 2014 to March 2016 in the Department of Surgery at a teaching hospital in Delhi, India. Clearance from Institutional Ethics Committee was obtained prior to recruitment of patients into the study protocol. The protocol was submitted to the University of Delhi and the research was conducted as a part of a postgraduate thesis.

Male patients between the ages of 18–60 years falling under ASA grades I and II with a diagnosis of unilateral inguinal hernia falling in Nyhus classification types 1, 2, and 3a undergoing TEP repair were included in the study. Patients with a complicated hernia including irreducible, obstructed, or strangulated hernias, patients with previous lower abdominal surgery, patients with coagulopathy, patients who have received analgesic in the last 24 hours, and patients not giving informed consent for randomization were excluded from the trial.

Sample size was calculated assuming effect size of 0.8, power of the study as 90% and type 1 error of 0.5. Calculated sample size was 28 in each group (using G-Power software version 3.1.9). The anesthesiologist co-investigator randomized 30 patients in each group using a web generated randomization sequence ([www.randomization.com](http://www.randomization.com)). The randomization sequence was sealed in serially numbered opaque envelopes and kept in the custody of the anesthesiologist co-investigator. The anesthesiologist in the operating room called up our anesthesiologist co-investigator to allocate the group of the patient provided either the drug or placebo to the surgeons as determined by the randomization sequence. The patient, surgery team, and observer were kept blinded.

The same surgeon performed all the procedures. Totally extraperitoneal repair was performed with reusable trocars and instruments. The same type of mesh was used in all patients. General anesthesia was administered to all patients following standard anesthesia protocol and morphine 0.1–0.15 mg/kg was used intravenously for intraoperative analgesia, as routinely practiced. No further analgesics were used intraoperatively.

Each port site was infiltrated with 1 mL of 0.75% ropivacaine or placebo (0.9% saline) before the skin was incised for inserting ports. Horizontal infra-umbilical skin incision was made. A camera port was inserted over posterior rectus sheath. A telescope was inserted and preperitoneal space was developed using telescopic dissection. The other two ports were inserted under visual guidance. Direct and small indirect hernia sacs were reduced completely while large indirect sacs were ligated close to the deep ring and transected. Parietalization of peritoneum and cord structures was done. Extraperitoneal space was instilled with 14 mL of 0.75% ropivacaine or placebo under laparoscopic vision after adequate space creation for mesh placement. The mesh was not fixed with either sutures

or tacks. Port sites were again infiltrated with 1 mL of 0.75% ropivacaine or placebo at the time of closure of skin incisions.

The patients were monitored during surgery and postoperatively as per hospital protocol. Patients were followed up at 2, 6, and 24 h after surgery for postoperative pain using NRS scoring. Paracetamol 1 gm was administered intravenously as and when required; the first 24 hours of postoperative analgesia were used at a minimum interval of 6 hours. When the NRS score was more than 3/10, Diclofenac 50 mg intravenous or oral was used as a rescue analgesia if the patient's pain was not controlled using 1 gm paracetamol.

Tablet diclofenac 50 mg was prescribed for pain relief in the postoperative period after discharge from the hospital, till 7th postoperative day. The postoperative analgesic requirement was calculated after 7 days. Time to ambulation, first act of micturition, and postoperative complications, such as hematoma, seroma, and wound infection were recorded.

Data were analyzed using SPSS statistical software (version 23.0). Independent samples median test was used to compare the numerical data without normal distribution. The Chi-square test ( $\chi^2$ ) test or Fischer exact test was used for categorical data. A *p*-value of < 0.05 was considered significant.

## RESULTS

A total of 221 patients with inguinal hernia who presented during the period November 2014 to March 2016, were assessed for eligibility for inclusion in the study. Out of them, 60 patients met the inclusion criteria and were selected for enrollment in the study. Patients were randomized into the ropivacaine group and placebo group, each consisting of 30 patients.

All the patients underwent the allocated procedure and patient's data were collected in the case record form. None of the procedures was converted to open surgery.

The CONSORT diagram of the study is shown in [Figure 1](#).

The two groups were similar in their baseline characteristics as given in [Table 1](#).

Pain scores were lower for ropivacaine group as compared with placebo group, but the difference was not statistically significant. [Table 2](#) compares the postoperative pain scores between the two groups.

No significant difference was noted in the mean analgesic requirement in the first 24 h (0.57 vs 0.83 tablets) as well as till postoperative day 7 (11.3 vs 10.8 tablets). The duration of surgery, as well as the time spent by the patient in the operating room was found comparable in the two study groups.

Preperitoneal space creation was satisfactory in all the cases. The instillation of fluid in the extraperitoneal space did not cause difficulty in dissection. No significant differences were noticed in the intraoperative or postoperative complications between the two groups.

## DISCUSSION

Our study was a double-blinded randomized controlled trial with 0.75% ropivacaine used in the test group and 0.9% saline used in the control group of patients with uncomplicated unilateral inguinal hernia undergoing TEP repair. Pain score at 6 h was considered as the primary objective as there could have been a confounding effect of general anesthesia on pain scores at 2 hours.



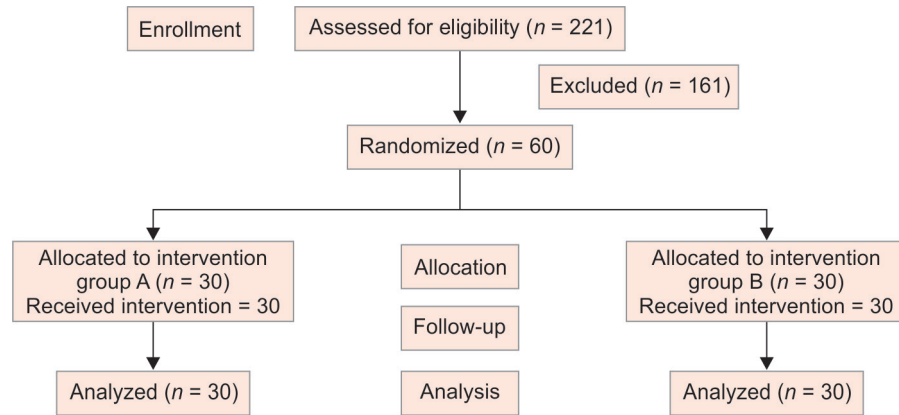


Fig. 1: CONSORT diagram of the study

Table 1: Baseline characteristics in the two groups

Study groups	Ropivacaine group	Placebo group
Age (In years) Mean $\pm$ Standard deviation (SD)	41.7 $\pm$ 13.2	35.3 $\pm$ 11.2
BMI (In kg/m <sup>2</sup> ) Mean $\pm$ Standard deviation (SD)	22.5 $\pm$ 2.6	22.7 $\pm$ 2.3

Table 2: Comparison of postoperative results between the two groups

	Ropivacaine group Median (IQR)	Placebo group Median (IQR)	p-value (Independent samples median test)
Pain at 2 hours (VAS)	1 (0,3)	2 (0,3)	0.187
Pain at 6 hours (VAS)	3 (1,3)	3 (1,4)	0.981
Pain at 24 hours (VAS)	3 (2,4)	3 (2,4)	0.160
Time to ambulation (hours)	4 (4,6)	4 (3,6)	0.411
Time to micturition	4 (4,6)	4 (4,6)	0.595

Pain scores at 2, 6, and 24 h were lower in ropivacaine group as compared with the control group but the difference was not statistically significant. Various other studies in the literature have compared postoperative pain scores following intraoperative use of bupivacaine in laparoscopic hernia repair.

Kumar et al. reported significantly lower VAS scores for pain in bupivacaine group as compared with the control group ( $1.69 \pm 1.04$  vs  $3.47 \pm 1.04$ , respectively, at 24 h postoperatively,  $p < 0.0001$ ;  $1.36 \pm 0.81$  vs  $2.29 \pm 1.44$ , respectively, at 48 h postoperatively,  $p = 0.0063$ ).<sup>3</sup> They administered intravenous diclofenac to all 53 studied patients before anesthesia reversal. This might have a confounding effect on pain scores in the early postoperative period. Mesh fixation was not done in their study group as well as ours. This may be responsible for lower pain scores in both groups as compared with other studies. O'Riordain et al. found patients treated with bupivacaine had lower median [range] visual analogue pain scores on discharge; [1.5 (0–5.9) vs 3.7 (0.2–6.9),  $p = 0.03$ ], and were more frequently

pain-free (54% vs 31%,  $p = 0.078$ ).<sup>2</sup> Bar-Dayana et al. also found the average pain levels as significantly reduced in bupivacaine group compared with the control group at 1 hour (4.0 vs 5.0, respectively;  $p = 0.0038$ ), 2 hours (4.0 vs 5.9, respectively;  $p = 0.0015$ ), and 4 hours (4.3 vs 5.8, respectively;  $p = 0.0038$ ) after surgery.<sup>5</sup> However, the drawback in his study was that no clear randomization method was mentioned, multiple surgeons and observers were involved, and no standard anesthesia protocol and analgesic use during surgery was defined in his study of 44 patients. Pain scores reported in their study were considerably higher than those reported in our study. This may be attributed to the use of tacks for mesh fixation. Hon et al. also concluded preemptive use of bupivacaine in surgical bed in TEP hernioplasty to be beneficial in their randomized trial with three arms of 30 patients each.<sup>4</sup> They randomized patients in to three groups: (a) preemptive bupivacaine group (PBU) which received port site infiltration of bupivacaine before skin incision and instillation of bupivacaine in preperitoneal space before mesh placement, (b) standard bupivacaine group (SBU) which received bupivacaine in preperitoneal space after mesh placement, and (c) control group which received port site infiltration and preperitoneal instillation with saline. In his study, the PBU group had lower pain scores as compared with the SBU group at 2 hours ( $1.1 \pm 1.5$  vs  $2.3 \pm 1.7$ ,  $p = 0.005$ ) and 24 hours ( $0.7$  vs  $1.5$ ,  $p = 0.004$ ) while no significant difference in pain score was noted at 6 h ( $1.1 \pm 1.3$  vs  $1.6 \pm 1.4$ ,  $p = 0.153$ ). The PBU group was superior to control group in pain relief at all times with pain scores at 2 h ( $1.1 \pm 1.5$  vs  $3.4 \pm 1.7$ ,  $p = 0.000$ ), 6 h ( $1.1 \pm 1.3$  vs  $1.8 \pm 1.7$ ,  $p < 0.001$ ), and at 24 h ( $0.7 \pm 0.0$  vs  $1.4 \pm 1.6$ ,  $p = 0.001$ ), respectively while the SBU group showed better pain relief only at 6 h postoperatively as compared with the control group [pain score at 2 h ( $2.3 \pm 1.7$  vs  $3.4 \pm 1.7$ ,  $p = 0.022$ ), at 6 h ( $1.6 \pm 1.4$  vs  $1.8 \pm 1.7$ ,  $p = 0.006$ ) and at 24 h ( $1.5 \pm 1.3$  vs  $1.4 \pm 1.6$ ,  $p = 0.404$ ) respectively]. Although they did not fix the mesh, they ligated all indirect hernia sacs and invaginated transversalis fascia in direct hernias. These techniques might potentially have increased pain. In our study, we have reduced all direct and small indirect inguinal hernias completely and ligated large indirect sacs.

On the contrary, Abbas et al. reported no significant difference in the postoperative pain scores at 4 h and 24 h; between bupivacaine group and the control group of 20 patients each ( $p$ -value = 0.615 and 0.100, respectively).<sup>8</sup> Deans et al. studied 100 patients and also found no significant difference between bupivacaine 0.25%, bupivacaine 0.25% with adrenaline 0.25%, bupivacaine 0.5% and control group for median pain scores at 24 h as [4 (2–8) vs 3 (2–8)

vs 4 (1–8), vs 4 (1–8),  $p = 0.71$ ] respectively.<sup>6</sup> They used adrenaline with a view that adrenaline might increase the availability of local anesthetic in preperitoneal space by limiting its systemic absorption as it does in open surgery; but did not find it useful. The drawback in their study was that port site infiltration was not done and as they have performed TAPP repair, the diaphragmatic and visceral components of pain due to pneumoperitoneum and diffusion of carbon dioxide into bowel during TAPP surgery may contribute to the visceral component of pain. These may be responsible for significantly higher pain scores than those observed in our study. Further, the drug may escape from the preperitoneal space through gaps in peritoneal suture-line. Suvikapakornkul et al. found the mean pain scores in bupivacaine and placebo group as 3.5 vs 5.2 ( $p = 0.059$ ), 2.9 vs 4.5 ( $p = 0.117$ ), 2.1 vs 3.2 ( $p = 0.101$ ), 1.5 vs 2.7 ( $p = 0.145$ ), and 1.6 vs 2.0 ( $p = 0.672$ ) after the 1st, 2nd, 6th, 12th, and 24th hour, respectively.<sup>8</sup> Although the pain scores in their study were lower in bupivacaine group, the difference was not statistically significant and they concluded that there is no strong evidence to confirm that bupivacaine instillation into preperitoneal space after laparoscopic hernioplasty can reduce postoperative pain. The drawback in the study was that they did not infiltrate the port sites and used tacks for mesh fixation. These factors might be responsible for higher pain scores observed in their study as compared with our study.

A meta-analysis by Tong et al. also concluded that extraperitoneal bupivacaine treatment during laparoscopic TEP inguinal hernioplasty was not more efficacious for the reduction of postoperative pain than the placebo.<sup>9</sup> Results in our study for postoperative pain relief were consistent with the results of some studies<sup>6–9</sup> while others<sup>2–5</sup> differ.

We also compared the postoperative analgesic requirement between the test and the control group. There was no significant difference in analgesic consumption in the 1st 24 hours as well as till the postoperative day 7 between the two groups.

Deans et al.,<sup>6</sup> Suvikapakornkul et al.,<sup>7</sup> Abbas et al.,<sup>8</sup> also reported comparable use of analgesics postoperatively in local anesthetic and placebo group, whereas Bar-Dayana et al.,<sup>5</sup> O'Riordain et al.,<sup>2</sup> and Kumar et al.<sup>3</sup> have reported reduced analgesic use in the treatment group.

No significant difference was noted regarding space creation, fall of inferior epigastric vessels or bleeding from inferior epigastric vessels in the two groups.

There was no incidence of injury to vas deferens and visceral injury. No significant difference was noted regarding time to ambulation and micturition in the two groups.

There was no incidence of hematoma formation and early recurrence. The incidence of postoperative seroma formation was 10% in ropivacaine group and 16.6% in the control group but the difference was not statistically significant. The incidence of seroma formation varies from 14 to 30% in various studies.<sup>4,7</sup> In our study, all seromas resolved spontaneously in 2–4 weeks.

One patient in placebo group developed surgical site infection which was managed on oral antibiotics and serial dressings. The incidence of postoperative complications in our study was comparable to what is reported in the literature.

In our study, we tried our best to strengthen our research protocol. Patients were randomized using computer generated sequence, double-blinding was done, no patient received preoperative and intraoperative analgesic, standard anesthesia

protocol was followed, single surgeon for all surgeries and single observer who were blinded about the groups, similar type of mesh was used in all patients, and no mesh fixation was done. Various other studies cited before has also used a sample size ranging from 40 to 60. The sample size in our study comparable to other similar studies.

Researchers have used varying amount of bupivacaine (10–60 mL) for postoperative analgesia.<sup>4–8</sup> We have used a total of 20 mL of 0.75% ropivacaine for postoperative analgesia. The amount of drug required to be effective in preperitoneal space might be high and further studies may be done in this regard.

## CONCLUSION

Postoperative pain following laparoscopic TEP mesh hernioplasty may still be a concern but the pain itself is mild that any reduction in pain score after local anesthetic use in preperitoneal space and port sites is not significant. Also, there was no difference in analgesic consumption in postoperative period in the local anesthetic group as compared with the placebo.

We concluded that port site infiltration and extraperitoneal instillation of ropivacaine in TEP mesh hernioplasty is not beneficial.

## ETHICAL AND HUMANE CONSIDERATIONS

*Ethical clearance:* It was obtained from institutional ethical committee, UCMS and GTB Hospital.

Trial Registered with CTRI—CTRI Reg No. CTRI/2016/07/007088.

## REFERENCES

- Miserez M, Alexandre JH, Campanelli G, et al. The European hernia society groin hernia classification: Simple and easy to remember. *Hernia* 2007;11(2):113–116. DOI: 10.1007/s10029-007-0198-3.
- O'Riordain DS, Kelly P, Horgan PG, et al. A randomized controlled trial of extraperitoneal bupivacaine analgesia in laparoscopic hernia repair. *Am J Surg* 1998;176(3):254–257. DOI: 10.1016/s0002-9610(98)00151-2.
- Kumar S, Joshi M, Chaudhary S. 'Dissectalgia' following TEP, a new entity: its recognition and treatment. Results of a prospective randomized controlled trial. *Hernia: The journal of hernias and abdominal wall surgery*. *Hernia* 2009;13(6):591–596. DOI: 10.1007/s10029-009-0538-6.
- Hon SF, Poon CM, Leong HT, et al. Pre-emptive infiltration of Bupivacaine in laparoscopic total extraperitoneal hernioplasty: a randomized controlled trial. *Hernia: The journal of hernias and abdominal wall surgery*. *Hernia* 2009;13(1):53–56. DOI: 10.1007/s10029-008-0422-9.
- Bar-Dayana A, Natour M, Bar-Zakai B, et al. Preperitoneal bupivacaine attenuates pain following laparoscopic inguinal hernia repair. *Surg Endosc* 2004;18(7):1079–1081. DOI: 10.1007/s00464-003-8214-x.
- Deans GT, Wilson MS, Brough WA. Controlled trial of preperitoneal local anaesthetic for reducing pain following laparoscopic hernia repair. *Br J Surg* 1998;85(7):1013–1014. DOI: 10.1046/j.1365-2168.1998.00763.x.
- Suvikapakornkul R, Valaivarangkul P, Noiwan P, et al. A randomized controlled trial of preperitoneal bupivacaine instillation for reducing pain following laparoscopic inguinal herniorrhaphy. *Surg Innov* 2009;16(2):117–123. DOI: 10.1177/1553350609334128.
- Abbas MH, Hamade A, Choudhry MN, et al. Infiltration of wounds and extraperitoneal space with local anesthetic in patients undergoing laparoscopic totally extraperitoneal repair of unilateral inguinal

- hernias: A randomized double-blind placebo-controlled trial. *Scand J Surg* 2010;99(1):18–23. DOI: 10.1177/145749691009900105.
9. Tong YS, Wu CC, Bai CH, et al. Effect of extraperitoneal bupivacaine analgesia in laparoscopic inguinal hernia repair: A meta-analysis of randomized controlled trials. *Hernia* 2014;18(2):177–183. DOI: 10.1007/s10029-013-1100-0.
  10. Hansen TG. Ropivacaine: A pharmacological review. *Expert Rev Neurother* 2004;4(5):781–791. DOI: 10.1586/14737175.4.5.781.
  11. Kuthiala G, Chaudhary G. Ropivacaine: A review of its pharmacology and clinical use. *Indian J Anaesth* 2011;55(2):104–110. DOI: 10.4103/0019-5049.79875.

# Laparoscopic vs Open Colorectal Surgeries in Urgent Surgical Situations

Loay M Gertallah<sup>1</sup>, Ahmed M Abdelaziz<sup>2</sup>, Ahmed I Elagrody<sup>3</sup>, Ahmed S Allam<sup>4</sup>, Mohamed Elbaz<sup>5</sup>, Mahmod Ghoname<sup>6</sup>, Mahmoud Sherbeiny<sup>7</sup>, Ahmed L Sharaf<sup>8</sup>, Ola A Harb<sup>9</sup>, Mahmoud Abdelaziz<sup>10</sup>, Mohamed Negm<sup>11</sup>

Received on: 19 August 2023; Accepted on: 21 September 2023; Published on: 14 February 2024

## ABSTRACT

**Background:** Using minimally invasive surgeries (MISs) in non-elective and urgent cases was assessed by many previous studies and found to be nearly similar to and even better than open surgeries. There was no sufficient data regarding long-term, follow-up, tumor recurrence, or survival data of studied patients in those studies.

Aim of our study is to compare performing MIS and open colectomy in patients undergoing urgent (non-emergency, non-elective) colectomies, regarding primary outcomes of 30-day morbidity and mortality, secondary short-term outcomes, long-term and follow-up findings of included patients.

**Patients and methods:** A total of 200 patients were included, and we divided them into two groups according to the performed surgical approach: The first group included 100 patients who underwent MISs and the second group underwent open surgery and included 100 patients. We evaluated the primary patients' outcome which was 30-day postoperative morbidity and mortality. Secondary evaluated patients' outcomes included; ICU admissions, surgical reintervention, wound infection or dehiscence, postoperative ileus, postoperative leakage at an anastomotic site, and occurrence of intra-abdominal infections. Long-term evaluated patients' outcomes included the occurrence of incisional hernias and oncological outcomes as overall survival rates and recurrence rates.

**Results:** Regarding demographic and baseline data, patients who underwent open surgery were older (65 years vs 58 years,  $p < 0.001$ ). More females underwent open surgery (54% vs 50%,  $p = 0.002$ ). Overweight and obese patients were more likely to have MIS colectomy ( $p < 0.001$ ). There is a statistically significant relation between approach and all histopathological types (24.2% within the laparoscopic approach vs 11.6% within the open approach had mucoid carcinoma), N stage (82.8% within the laparoscopic approach vs 43.8% within open the approach had N stage 0), American Joint Committee on Cancer (AJCC) stage (63.8% within laparoscopic approach vs 20.8% within open approach had AJCC stage II) Open colectomy were liable to be diagnosed with acute diverticulitis and volvulus ( $p < 0.001$ ). Operative time is longer in MIS patients in comparison to open colectomy patients the median time to complete an MIS colectomy was 21 minutes longer ( $p < 0.001$ ). Postoperative mortality is less in MIS patients than the open surgery patients. On univariable analysis, 30-day postoperative mortality following MIS colectomy was lower than that after open surgery ( $p < 0.05$ ).

**Conclusions:** Using MIS in urgent colectomy is associated with less postoperative, morbidity, mortality, short-term complications, and long-term complications than open colectomy.

**Keywords:** Advanced laparoscopic surgery, Laparoscopic, Open, Minimally invasive surgeries, Open surgery, Urgent colectomy.

*World Journal of Laparoscopic Surgery* (2024): 10.5005/jp-journals-10033-1607

## INTRODUCTION

Minimally invasive surgeries (MISs) have become the preferred surgical approach for performing elective resections of the colon and rectum.<sup>1</sup> Minimally invasive surgeries have many clear benefits as less postoperative pain and ileus, short hospital length of stay (LOS), and better quality of life in addition to similar oncologic outcomes.<sup>2</sup> These advantages made MISs the approaches of choice by most surgeons for performing nearly 50% of elective colorectal resections.<sup>3</sup>

Using MISs in non-elective and urgent cases was assessed by many previous studies and found by most of them to be nearly similar to and even better than open surgeries.<sup>4,5</sup> Minimally invasive surgeries in urgent cases was found to be associated with; reduced costs, short LOS, and less postoperative morbidity and mortality than open colectomy.<sup>6</sup>

These former studies include both urgent and emergency colorectal resections and using MISs was reported in 5–30% of all cases.<sup>7,8</sup>

<sup>1,2,11</sup>Department of General Surgery, Zagazig University, Zagazig, Egypt

<sup>3,4</sup>Department of Internal Medicine, Faculty of Medicine, Zagazig University, Zagazig, Egypt

<sup>5</sup>Department of Internal Medicine, Faculty of Medicine, Cairo University, Giza, Egypt

<sup>6</sup>Department of Hepatogastroenterology and Infectious Diseases, Faculty of Medicine, Al-Azhar University, Cairo, Egypt

<sup>7</sup>Department of Hepatology and Gastroenterology, Theodor Bilharz, Research Institute, Giza, Egypt

<sup>8</sup>Department of Tropical Medicine, Zagazig University, Zagazig, Egypt

<sup>9</sup>Department of Pathology, Zagazig University, Zagazig, Egypt

<sup>10</sup>Department of General Surgery, Surgical Oncology, Oncology Center, Mansura University, Egypt

**Corresponding Author:** Ola A Harb, Department of Pathology, Zagazig University, Zagazig, Egypt, Phone: +01224785643, e-mail: olaharb2015@gmail.com



There was no sufficient data regarding long-term, follow-up, tumor recurrence, or survival data of studied patients in those studies.

Aim of our study is to compare performing MIS and open colectomy in patients undergoing urgent (nonemergency, non-elective) colectomies, regarding primary outcomes of 30-day morbidity and mortality, secondary short-term outcomes, long-term and follow-up findings of included patients.

## PATIENTS AND METHODS

This is a retrospective randomized study that was approved by the Institutional Review Board of the Faculty of Medicine, Zagazig University. We included all colectomies performed between January 1, 2016, and December, 2021.

After the application of inclusion criteria of selecting patients with non-elective colectomy and excluding all cases with elective planned colectomy and cases with incomplete data, 200 patients were included, and we divided them into two groups according to the performed surgical approach: The first group included 100 patients who underwent MISs and the second group underwent open surgery and included 100 patients.

Minimally invasive surgery patients included: Totally laparoscopic surgery, laparoscopic surgery with open assistance, and laparoscopic surgery with unplanned conversion to open surgery.

The group of patients who underwent open surgeries included all patients with planned urgent open colectomies.

We compared between both groups of patients as regards; baseline demographic data and comorbidities.

We evaluated the primary patients' outcome which was 30-day postoperative morbidity and mortality. Secondary evaluated patients' outcomes included; ICU admissions, surgical reintervention, hospital LOS, wound infection or dehiscence, postoperative ileus, postoperative leakage at anastomotic site, occurrence of intra-abdominal infections, and pulmonary or cardiac complications.

Long-term evaluated patients' outcomes included the occurrence of incisional hernias and oncological outcomes as overall survival rates and recurrence rates.

## Statistical Analysis

We analyzed data using SAS/STAT software (version 90.4), SAS Institute Inc., Cary, North Carolina, USA. We compared baseline data using the  $\chi^2$  test for all categorical variables, and we used *t*-test for continuous variables. We compared operative time using the Wilcoxon Rank-Sum test.

We compared postoperative outcomes using the  $\chi^2$  test and logistic regression, then using multivariable logistic regression analysis. We considered a *p*-value of  $< 0.05$  a statistically significant value.

## RESULTS

This study included 200 patients with an age range from 30 to 68 years with a mean age of 50.51 years and a mean BMI of 22.54 kg/m<sup>2</sup>. Males represented 33% of them. Patients of 135 underwent histopathological examination; of them, 51.1% had conventional adenocarcinoma, 21.5% had benign lesions. Among 106 patients with confirmed malignancy by HPE; 29.2, 28.3, and 23.6% had T stage 4, 3, and 1, respectively. concerning N stage; 65.1% had stage 0, 16% had N stage 3 with no patient with distant metastasis. About 50, 29.2, and 20.8% had grades II, III, and I, respectively.

**How to cite this article:** Gertallah LM, Abdelaziz AM, Elagrody AI, *et al.* Laparoscopic vs Open Colorectal Surgeries in Urgent Surgical Situations. *World J Lap Surg* 2024;17(1):38–43.

**Source of support:** Nil

**Conflict of interest:** None

On investigating the cause of resection, 53, 14.5, and 10% underwent resection for malignancy, benign neoplasm, and ischemia respectively. About 37, 25, and 23% underwent right hemicolectomy, sigmoid resection, and anterior resection respectively.

Of patients, 56.5% underwent an open approach while the remaining 45.5% had a laparoscopic approach.

Among the MIS group of patients (20%) underwent unplanned conversion to open.

Regarding demographic and baseline data, patients who underwent open surgery were older (65 years vs 58 years,  $p < 0.001$ ). More females underwent open surgery (54 vs 50%,  $p = 0.002$ ).

Overweight and obese patients were more likely to have MIS colectomy ( $p < 0.001$ ).

American Society of Anesthesiologists (ASA) I and II patients were more likely to have MIS in comparison with ASA III patients ( $p < 0.001$ ). Patients with comorbid conditions were more likely to have open surgery ( $p < 0.001$ ).

Minimally invasive surgery patients were more likely to have completed mechanical and antibiotic bowel preparation ( $p < 0.001$ ).

Generally, the commonest surgery indications were obstructing or perforating colorectal cancer and acute diverticulitis.

There is statistically significant relation between approach and all of sex (79.3% within laparoscopic approach vs 57.5% within open approach were females), reason for resection (66.7% within laparoscopic approach vs 42.5% within open approach underwent resection for malignancy), ASA classification (20.7% within laparoscopic approach vs 58.4% within open approach had ASA I), and type of primary operation (2.3% within laparoscopic approach vs 12.4% within open approach underwent anterior resection).

There is a statistically non-significant relation between the approach and either age, BMI, or resection site (Table 1).

There is a statistically significant relation between approach and all histopathological types (24.2% within the laparoscopic approach vs 11.6% within the open approach had mucoid carcinoma), N stage (82.8% within the laparoscopic approach vs 43.8% within the open approach had N stage 0), American Joint Committee on Cancer (AJCC) stage (63.8% within laparoscopic approach vs 20.8% within open approach had AJCC stage II).

There is statistically non-significant relation between approach and either T stage, M stage, or grade.

Minimally invasive surgery colectomy patients were liable to be diagnosed with obstructing or perforating colorectal cancer, chronic diverticulitis with stricture, ulcerative colitis, or bleeding colorectal polyps.

Open colectomy was liable to be diagnosed with acute diverticulitis and volvulus ( $p < 0.001$ ). Operative time is longer in MIS patients in comparison to open colectomy patients the median time to complete an MIS colectomy was 21 minutes longer ( $p < 0.001$ ).

Postoperative mortality is less in MIS patients than in open surgery patients.

**Table 1:** Relation between approach and baseline data among studied patients

	Laparoscopic N = 87 (%)	Open N = 113 (%)	p
Sex			
Male	18 (20.7%)	48 (42.5%)	0.001**
Female	69 (79.3%)	65 (57.5%)	
Reason for resection			
Malignancy	58 (66.7%)	48 (42.5%)	<0.001**
Benign neoplasm	8 (9.2%)	21 (18.6%)	
Diverticular disease	5 (5.7%)	11 (9.7%)	
Obstruction	0 (0%)	7 (6.2%)	
Ischemia	7 (8%)	13 (11.5%)	
Colo proctitis	7 (8%)	7 (6.2%)	
Perforation	2 (2.3%)	6 (5.3%)	
Resection site			
Cecum	20 (23%)	26 (23%)	0.193
Ascending colon	16 (18.4%)	11 (9.7%)	
Transverse colon	10 (11.5%)	6 (5.3%)	
Descending colon	18 (20.7%)	28 (24.8%)	
Sigmoid colon	14 (16.1%)	23 (20.4%)	
Rectum	9 (10.3%)	19 (16.8%)	
ASA classification			
0	69 (79.3%)	47 (41.6%)	<0.001**
I	18 (20.7%)	66 (58.4%)	
Type of primary operation			0.041*
Right hemicolectomy	36 (41.4%)	37 (32.7%)	
Left hemicolectomy	18 (20.7%)	28 (24.8%)	
Transverse colon resection	10 (11.5%)	6 (5.3%)	
Sigmoid resection	21 (24.1%)	28 (24.8%)	
Anterior resection	2 (2.3%)	14 (12.4%)	
	Mean ± SD	Mean ± SD	p
Age (year)	49.49 ± 8.42	51.29 ± 8.95	0.15
BMI (kg/m <sup>2</sup> )	22.63 ± 1.33	22.47 ± 1.32	0.406

$\chi^2$ , Chi-square test; t, independent sample t test; MC, Monte Carlo test; \* $p < 0.05$  is statistically significant; \*\* $p \leq 0.001$  is statistically highly significant

On univariable analysis, 30-day postoperative mortality following MIS colectomy was lower than that after open surgery ( $p < 0.05$ ).

Prolonged duration of staying in hospital (>30 days), postoperative bleeding, shock, sepsis, postoperative ileus, reoperation, dehiscence or infection of the wounds, anastomotic leakage, deep venous thrombosis (DVT), urinary tract infection (UTI), surgical site infections (SSI), pulmonary embolism (PE), and hospital readmission were lower for the MIS patients.

Minimally invasive surgery patients had a shorter duration of hospital stay ( $p < 0.001$ ).

Regarding long-term incidence of incisional hernias is less in the MIS group of patients (Table 2).

**Table 2:** Relation between approach and histopathological data of studied patients

	Laparoscopic N = 87 (%)	Open N = 113 (%)	p
Histological type			
Conventional adenocarcinoma	39 (59.1%)	30 (43.5%)	0.004*
Mucoid carcinoma	16 (24.2%)	8 (11.6%)	
Squamous cell carcinoma	3 (4.5%)	10 (14.5%)	
Benign	8 (12.1%)	21 (30.4%)	
T stage			
1	11 (19%)	14 (29.2%)	0.378
2	24 (41.4%)	6 (12.5%)	
3	9 (15.5%)	11 (22.9%)	
4	14 (24.1%)	17 (35.4%)	
N stage			
0	48 (82.8%)	21 (43.8%)	<0.001**
1	5 (8.6%)	3 (6.3%)	
2	3 (5.2%)	9 (18.8%)	
3	2 (3.4%)	15 (31.3%)	
M stage (0)	58 (100%)	48 (100%)	
AJCC stage	N = 58	N = 48	
I	11 (19%)	11 (22.9%)	0.024*
II	37 (63.8%)	10 (20.8%)	
III	10 (17.2%)	27 (56.3%)	
Grade	N = 58	N = 48	
I	11 (19%)	11 (22.9%)	0.073
II	38 (65.5%)	15 (31.3%)	
III	9 (15.5%)	22 (45.8%)	

$\chi^2$ , Chi-square test; MC, Monte Carlo test; \* $p < 0.05$  is statistically significant; \*\* $p \leq 0.001$  is statistically highly significant

There is a statistically significant relation between approach and short-term complications. The open approach significantly increases the risk of short-term complications by 2.2 folds.

There is a statistically non-significant relation between approach and either reoperation or long-term complications. The open approach significantly increases the risk of reoperation and long-term complications by 1.8 and 1.46 folds respectively (Table 3).

There is a statistically significant relation between complications and all of sex (50% within complicated vs 26.4% of non-complicated were males), and approach (32.1% within complicated vs 47.9% within non-complicated underwent laparoscopic approach).

There is a statistically non-significant relation between approach and either age, resection site, type of operation, BMI, or ASA classification.

Regarding long-term oncological outcomes such as tumor recurrence, response to therapy, and 3-year overall survival rate and 3-year recurrence-free survival rate, there were no significant differences between performed surgical approaches (Table 4).

## DISCUSSION

In the present study, we clarified the advantages of MIS in urgent colectomy cases over open surgery and demonstrated their benefits over open colectomy regarding postoperative short-term

**Table 3:** Relation between approach and outcome of studied patients

	<i>Laparoscopic</i>	<i>Open</i>		
	<i>N = 87 (%)</i>	<i>N = 113 (%)</i>	<i>p</i>	<i>COR (95% CI)</i>
Reoperation	11 (12.6%)	23 (20.4%)	0.15	1.8 (0.81–3.85)
Short-term complications	16 (18.4%)	37 (32.7%)	0.023*	2.2 (1.1–4.22)*
Long-term complications	10 (11.5%)	18 (15.9%)	0.307	1.46 (0.64–3.34)

$\chi^2$ , Chi-square test; COR, crude odds ratio; CI, confidence interval; \* $p < 0.05$  is statistically significant; \*\* $p \leq 0.001$  is statistically highly significant

**Table 4:** Relation between complications and baseline data of studied patients

	<i>Complicated</i>	<i>Non-complicated</i>	
	<i>N = 56 (%)</i>	<i>N = 144 (%)</i>	<i>p</i>
Sex			
Male	28 (50%)	38 (26.4%)	0.001**
Female	28 (50%)	106 (73.6%)	
Reason for resection			
Malignancy	36 (64.3%)	70 (48.6%)	0.245
Benign neoplasm	5 (8.9%)	24 (16.7%)	
Diverticular disease	5 (8.9%)	11 (7.6%)	
Obstruction	0 (0%)	7 (4.9%)	
Ischemia	6 (10.7%)	14 (9.7%)	
Colo proctitis	2 (3.6%)	12 (8.3%)	
Perforation	2 (3.6%)	6 (4.2%)	
Resection site			
Cecum	16 (28.6%)	30 (20.8%)	0.385
Ascending colon	6 (10.7%)	21 (14.6%)	
Transverse colon	3 (5.4%)	13 (9%)	
Descending colon	17 (30.4%)	29 (20.1%)	
Sigmoid colon	10 (17.9%)	27 (18.8%)	
Rectum	4 (7.1%)	24 (16.7%)	
ASA classification			
0	25 (44.6%)	91 (63.2%)	<0.001**
I	31 (55.4%)	53 (36.8%)	
Type of primary operation			
Right hemicolectomy	22 (39.3%)	51 (35.4%)	0.375
Left hemicolectomy	17 (30.4%)	29 (20.1%)	
Transverse colon resection	3 (5.4%)	13 (9%)	
Sigmoid resection	10 (17.9%)	39 (27.1%)	
Anterior resection	4 (7.1%)	12 (8.3%)	
Approach			
Laparoscopic	18 (32.1%)	69 (47.9%)	0.043*
Open	38 (67.9%)	75 (52.1%)	
	<i>Mean <math>\pm</math> SD</i>	<i>Mean <math>\pm</math> SD</i>	<i>p</i>
Age (year)	51.05 $\pm$ 8.26	50.3 $\pm$ 8.95	0.585
BMI (kg/m <sup>2</sup> )	22.51 $\pm$ 1.27	22.55 $\pm$ 1.35	0.85

$\chi^2$ , Chi-square test; MC, Monte Carlo test; \* $p < 0.05$  is statistically significant; \*\* $p \leq 0.001$  is statistically highly significant

outcomes, long-term outcome, our findings are similar to the results of Hajirawala et al.,<sup>8</sup> study and Warps et al.,<sup>9</sup> who showed that MIS is beneficial in non-elective cases of colectomy. Minimally invasive surgery in urgent colectomy was associated with lower; mortality, short hospitalization, less incidence of ileus, less wound infection or dehiscence, and less readmission rate (Tables 5 and 6).

Minimally invasive surgery was demonstrated to be better than open surgery by many previous studies.<sup>4,5,10</sup>

Vallance et al.,<sup>6</sup> showed similar results to ours that MIS was associated with a shorter duration of hospital stay and less incidence of 90-day mortality than open colectomy.

Moreover, Keller et al.,<sup>7</sup> demonstrated that MIS was associated with favorable short-term and long-term outcomes. Post-colectomy

wound infections particularly in urgent non-elective cases are liable to occur, and it was found that MIS was associated with lower incidence than open cases.<sup>11</sup>

Postoperative readmissions after colectomy were associated with increased postoperative morbidity, mortality, and reduced overall survival rate.<sup>12</sup>

We showed similar to previous reports that patients who underwent urgent MIS colectomy were less liable to hospital re-admission this is due to a reduction in rates of most short-term postoperative complications following MIS.

Patients who underwent MIS colectomy were less likely to have hypertension, chronic obstructive pulmonary disease, renal failure, dialysis, smoking, sepsis at the time of surgery.

**Table 5:** Relation between complications and histopathological data of studied patients

	Complicated	Non-complicated	<i>p</i>
	<i>N</i> = 56 (%)	<i>N</i> = 144 (%)	
Histological type	<i>N</i> = 41	<i>N</i> = 94	0.335
Conventional adenocarcinoma	25 (61%)	44 (46.8%)	
Mucoid carcinoma	7 (17.1%)	17 (18.1%)	
Squamous cell carcinoma	4 (9.8%)	9 (9.6%)	
Benign	5 (12.2%)	24 (25.5%)	0.808
T stage	<i>N</i> = 36	<i>N</i> = 70	
1	11 (30.6%)	14 (20%)	
2	5 (13.9%)	25 (35.7%)	
3	11 (30.6%)	9 (12.9%)	
4	9 (24.1%)	22 (31.4%)	0.702
N stage	<i>N</i> = 36	<i>N</i> = 70	
0	23 (63.9%)	46 (65.7%)	
1	4 (11.1%)	4 (5.7%)	
2	5 (13.9%)	7 (10%)	
3	4 (11.1%)	13 (18.6%)	–
M stage (0)	36 (100%)	70 (100%)	
AJCC stage	<i>N</i> = 36	<i>N</i> = 70	0.8
I	7 (19.4%)	15 (21.4%)	
II	16 (44.4%)	31 (44.3%)	
III	13 (36.2%)	24 (34.3%)	0.989
Grade	<i>N</i> = 36	<i>N</i> = 70	
I	7 (19.4%)	15 (21.4%)	
II	18 (50%)	35 (50%)	
III	11 (30.6%)	20 (28.6%)	

$\chi^2$ , Chi-square test; MC, Monte Carlo test; \* $p < 0.05$  is statistically significant; \*\* $p \leq 0.001$  is statistically highly significant

**Table 6:** Binary regression analysis of factors associated with complications among studied patients

	$\beta$	<i>p</i>	AOR	95% CI	
				Lower	Upper
Male sex	0.924	0.006*	2.519	1.305	4.864
Open approach	0.470	0.172	1.600	0.815	3.140

\* $p < 0.05$  is statistically significant; AOR, adjusted odds ratio; CI, confidence interval; Male sex and open approach independently increase risk of complications by 2.519 and 1.6 folds respectively

Patients with comorbid conditions were more liable to perform open surgery, which is in line with previous reports.<sup>6,7</sup>

Former studies showed that MIS in patients undergoing colectomies has less liability to short-term morbidity and mortality.<sup>8,13</sup>

## CONCLUSIONS

We demonstrate that using MIS in urgent colectomy is associated with less postoperative, morbidity, mortality, less short-term complications, and long-term complications than open colectomy.

## Points of Strength

This is a randomized cohort comparative study that included a large number of urgent colectomy patients.

## Points of Weakness

This is a retrospective study that leads to the liability of bias in collected data.

## Recommendations

We recommend performing a prospective and randomized study including large number of patients with urgent colectomy to prove and clarify our results.

## REFERENCES

- Hajirawala LN, Krishnan V, Leonardi C, et al. Minimally invasive surgery is associated with improved outcomes following urgent inpatient colectomy. *JSLs* 2022;26(1):e2021.00075 1. DOI: 10.4293/JSLs.2021.00075.
- Govaert JA, Fiocco M, van Dijk WA, et al. Dutch value based healthcare study group. multicenter stratified comparison of hospital costs between laparoscopic and open colorectal cancer resections: influence of tumor location and operative risk. *Ann Surg* 2017;266(6):1021–1028. DOI: 10.1097/SLA.0000000000002000.
- Davis CH, Shirkey BA, Moore LW, et al. Trends in laparoscopic colorectal surgery over time from 2005–2014 using the NSQIP database. *J Surg Res* 2018;223:16–21. DOI: 10.1016/j.jss.2017.09.046.
- Nash GM, Bleier J, Milsom JW, et al. Minimally invasive surgery is safe and effective for urgent and emergent colectomy. *Colorectal Dis* 2010;12(5):480–484. DOI: 10.1111/j.1463-1318.2009.01843.x.
- Catani M, De Milito R, Romagnoli F, et al. Laparoscopic colorectal surgery in urgent and emergent settings. *Surg Laparosc Endosc Percutan Tech* 2011;21(5): 340–343. DOI: 10.1097/SLE.0b013e3182318b5c.
- Vallance AE, Keller DS, Hill J, et al. Role of emergency laparoscopic colectomy for colorectal cancer. *Ann Surg* 2019;270(1):172–179. DOI: 10.1097/SLA.0000000000002752.
- Keller DS, Pedraza R, Flores-Gonzalez JR, et al. The current status of emergent laparoscopic colectomy: A population-based study of



- clinical and financial outcomes. *Surg Endosc* 2016;30(8):3321–3326. DOI: 10.1007/s00464-015-4605-z.
8. Hajirawala L, Leonardi C, Orangio G, et al. Urgent inpatient colectomy carries a higher morbidity and mortality than elective surgery. *J Surg Res* 2021;268:394–404. DOI: 10.1016/j.jss.2021.06.081.
9. Warps AK, Zwanenburg ES, Dekker JWT, et al. Laparoscopic versus open colorectal surgery in the emergency setting a systematic review and meta-analysis. *Ann Surg Open* 2021;2(3):e097. DOI: 10.1097/AS9.0000000000000097.
10. Champagne B, Stulberg JJ, Fan Z, et al. The feasibility of laparoscopic colectomy in urgent and emergent settings. *Surg Endosc* 2009;23(8):1791–1796. DOI: 10.1007/s00464-008-0227-z.
11. Gantz O, Zagadailov P, Merchant AM. The cost of surgical site infections after colorectal surgery in the United States from 2001 to 2012: A longitudinal analysis. *Am Surg* 2019;85(2):142–149. PMID: 30819289.
12. Schneider EB, Hyder O, Brooke BS, et al. Patient readmission and mortality after colorectal surgery for colon cancer: Impact of length of stay relative to other clinical factors. *J Am Coll Surg* 2012;214(4):390–398. DOI: 10.1016/j.jamcollsurg.2011.12.025.
13. Mullen MG, Michaels AD, Mehaffey JH, et al. Risk associated with complications and mortality after urgent surgery vs elective and emergency surgery. *JAMA Surg* 2017;152(8):768–774. DOI: 10.1001/jamasurg.2017.0918.

# Laparoscopic Surgery Practice in the Era of COVID-19: The Pakistani Perspective

Syed Ali Haider<sup>1</sup>, Muhammad Zubair<sup>2</sup>, Sumera Qazi<sup>3</sup>

Received on: 01 July 2022; Accepted on: 20 February 2023; Published on: 14 February 2024

## ABSTRACT

**Aims:** The SARS-CoV-2 coronavirus disease-19 (COVID-19) pandemic has wreaked havoc worldwide. Not only has it severely impacted the way of life, but also damaged global economies and worsened social disparities, including those in healthcare. The pandemic, having imposed an enormous burden on global healthcare infrastructure, has led to drastic changes in medical and surgical practices, including those of laparoscopic and minimally invasive surgery. This study aimed to explore the practice of laparoscopic surgeons during the COVID-19 era in Pakistan.

**Materials and methods:** Surgeons involved in laparoscopic surgery (LS) were approached via e-mail practicing in different surgical setups and cities of Pakistan. After taking Institutional Review Board (IRB) approval and informed consent a questionnaire was filled out by all participating laparoscopic surgeons. The data was then analyzed in SPSS version 26.

**Results:** A total of 168 surgeons involved in LS from different disciplines responded to the invitation and filled out the online questionnaire. The mean age of the surgeons was  $48.72 \pm 8.04$  years and most of them were married and the majority belonged to the major cities of the country, i.e., Karachi, Lahore, Multan, Islamabad, and Rawalpindi. Surgeons who participated had a mean practice experience of  $12.12 \pm 6.88$  years (minimum 3 and maximum 31 years). Most of the respondents were General Surgeons (GS), followed by minimal invasive surgeons (MIS) having advanced training in laparoscopy, Obstetricians and Gynecologists (OB-GYN), and Urologists.

**Conclusion:** The LS practice in Pakistan during the COVID-19 era is widely variable. There is a dire need to formulate apt local guidelines, that are practical and implementable in developing countries.

**Keywords:** Coronavirus disease-19, Health care professionals, Laparoscopic surgery, Minimally invasive surgery, Surgical smoke.

*World Journal of Laparoscopic Surgery* (2024): 10.5005/jp-journals-10033-1591

## INTRODUCTION

Since the start of the SARS-CoV-2 corona virus disease-19 (COVID-19) pandemic in 2019, the tally of patients suffering from the disease around the world has continuously increased with time. As of June 24th, 2022, the number of patients has risen to 547,492,681 globally, whereas 6,347,816 lives have been lost to this deadly pandemic.<sup>1</sup> Pakistan itself has seen 30,384 deaths as of June 24th, 2022, and with the first case of the much-feared sub-Omicron variant being reported recently, the pandemic is nowhere near its end.<sup>2</sup> Where COVID-19 has deteriorated the socioeconomic and political landscape of all the countries of the world, it has also changed the lives and practices of healthcare professionals (HCPs) for an indefinite amount of time.<sup>3</sup>

Due to the high risk of contracting the virus from patients, all HCPs are encouraged to always don personal protective equipment (PPE) and take safety precautions while handling patients suffering from COVID-19. The risk further increases with exposure to aerosol-generating procedures (e.g., endotracheal intubation, extubation, non-invasive ventilation, etc.) for at least 10 minutes at a distance of fewer than 2 meters from the patient.<sup>4</sup> Although the gains of LS for patients are established, there have been concerns regarding additional prospects of COVID-19 spread owing to the creation of pneumoperitoneum, use of energy devices, and diathermy during laparoscopy.<sup>3</sup> This has initiated an array of discussions from the use of energy devices and proper disposal of gases after insufflation to the use of filtration devices to curtail and limit the application of the laparoscopic approach during the COVID-19 pandemic.<sup>5</sup>

<sup>1,2</sup>Department of Surgery, Dow University of Health Sciences, Sindh, Karachi, Pakistan

<sup>3</sup>Department of Obstetrics and Gynaecology, Sindh Government Hospital Korangi, Sindh, Karachi, Pakistan

**Corresponding Author:** Syed Ali Haider, Department of Surgery, Dow University of Health Sciences, Sindh, Karachi, Pakistan, Phone: +92 3218203820, e-mail: dralihaider@gmail.com

**How to cite this article:** Haider SA, Zubair M, Qazi S. Laparoscopic Surgery Practice in the Era of COVID-19: The Pakistani Perspective. *World J Lap Surg* 2024;17(1):44–51.

**Source of support:** Nil

**Conflict of interest:** None

Laparoscopy is employed in scores of acute surgical undertakings; however, information at hand on the risks for HCPs performing LS on COVID-19 positive or suspected cases is limited.

Numerous renowned societies and professional organizations of minimally invasive surgeons have issued guidelines on the preventive measures and the technical, mechanical, and procedural modifications to be taken during a laparoscopic undertaking for the safety of HCPs and theater staff.<sup>6</sup> This study aims to explore the practices of laparoscopic surgeons during this COVID-19 era to statistically evaluate their practices and awareness so that further steps can be recommended or devised on those grounds to improve the practices of laparoscopic surgeons in our local milieu amidst a rising fear of an increasing number of cases.

## MATERIALS AND METHODS

A cross-sectional, observational study was performed after IRB approval (IRB-1783/DUHS/Approval/2020) conducted from December 2020 to October 2021 via a purposive sampling technique. All surgeons performing laparoscopic surgeries in Pakistan were included in the study. Surgeons in training and those who had abandoned/stopped all types of operations during the COVID-19 pandemic were excluded from the study. Participants were requested through electronic communication channels, i.e., Surgical groups WhatsApp® and email groups, citing the link of the online semi-structured, pre-tested questionnaire by the investigators after consenting to participate in reading the online informed consent document. The identity of the participants and information retrieved from them was kept confidential.

Data was entered and analyzed by SPSS version 26. Frequency and percentages were calculated for qualitative data like gender, city of practice, academic association, and other responses while mean and standard deviation were calculated for quantitative data like age and years of practice. Stratification was done with reference to gender, teaching involvement, and specialties to control the effect modifier. The Chi-square test was put in application to appraise the impact of these on the outcome variables. The *p*-value < 0.05 was taken as significant.

## RESULTS

A total of 168 surgeons involved in LS from different disciplines responded to the invitation and filled out the online questionnaire. The mean age of the surgeons was  $48.72 \pm 8.04$  years 146 (86.9%) of them were married and the majority belonged to the Major cities of the country, i.e., Karachi, Lahore, Multan, Islamabad, and Rawalpindi (Table 1). Surgeons who participated had a mean practice experience of  $12.12 \pm 6.88$  years (minimum 3 and maximum 31 years). Most of the respondents were general surgeons (GS) performing basic laparoscopic procedures, followed by minimal invasive surgeons (MIS) having advanced laparoscopic training, Obstetricians and Gynecologists (OB-GYN), and Urologists. About 41% were practicing in the city of Karachi and the rest were distributed in other cities of Pakistan (Table 1). Only 28% were academic surgeons involved in teaching. More than half of the respondents have neither been associated with any Laparoscopic surgical association nor have read any LS guidelines for laparoscopic surgery during the COVID-19 pandemic (Table 1).

About 87% of surgeons were of the opinion that LS carries the additional risk of COVID-19 transmission while a little more than half agreed to have changed practice approaches during the COVID era. A total of 23 (13.7%) were only testing suspected patients for COVID before operating and the majority resorted to RT-PCR nasopharyngeal swabs for preoperative COVID screening. The choice of PPEs was also variable amongst surgeons with only a minority donning the N95 or respirator masks, eye protection, and coverall suits even during the peak of the pandemic. The availability of anesthesia gas scavenging systems (AGSS), negative pressure in the operating room (OR), smoke evacuation systems, and high-efficiency particulate air (HEPA) or ultra-low particulate air (ULPA) filter systems for laparoscopic surgeons were very limited. Only 30 (17.9%) practiced the recommendation of doing LS with lower intra-abdominal pressure than usual, i.e., <12 mm Hg. Minimizing the Trendelenburg position and avoiding the use of energy devices was also an uncommon practice, though, more than half (56%)

**Table 1:** Demographics and characteristics

Variables	Number (%)
Specialty	
GS	98 (58.3%)
MIS	24 (14.3%)
OB-GYN	24 (14.3%)
Urologist	22 (13.1%)
City	
Karachi	69 (41.1%)
Lahore	32 (19%)
Hyderabad	22 (13.1%)
Multan	14 (8.3%)
Sialkot	12 (7.1%)
Islamabad and Rawalpindi	9 (5.4%)
Peshawar	9 (5.4%)
Sukkur	1 (0.6%)
Involved in teaching	
Yes	28 (16.7%)
No	140 (83.3%)
Member of laparoscopic association	
Yes	57 (33.9%)
No	111 (66.1%)
Which MIS guideline for COVID-19 have you read?	
SAGES	43 (25.6%)
IRCG	22 (13.1%)
EAES	9 (5.4%)
None	94 (56%)

of surgeons exercised exsufflating the pneumoperitoneum with vacuum suction before removing the ports for converting to open surgery or closure (Table 2).

Females (61.3%) and teaching surgeons (60.7%) were more statistically believing in additional risk of COVID transmission during LS while male surgeons (81%) and teaching surgeons (92.9%) were mandatorily doing preoperative COVID testing compared to female and non-academic surgeons with the difference reaching statistical significance (*p*-values < 0.05). The differences in practices with respect to gender and academic teaching affiliation are detailed in Table 3, whereas apart from preoperative COVID testing and working in HEPA/ULPA filter-installed ORs the rest were statistically similar between teaching versus non-teaching surgeons, but most of the questionnaire responses differed widely amongst gender groups as evident by the *p*-values.

Table 4 details the comparison of practices with respect to the specialties of participants, the Pearson Chi-square test for *p*-value showed that the practices were widely variable saving only two acts, i.e., use of the smoke evacuation system during LS and reducing the Trendelenburg tilt intentionally, which was not enacted routinely by all the subspecialties statistically (*p*-value > 0.05).

## DISCUSSION

The SARS-CoV-2 pandemic has brought attention to a neglected matter in recent times, that of aerosols and plume exposure-related

**Table 2:** Details of responses by surgeons

Questions	Responses	Number (%)
Does MIS carry additional risk of COVID-19 transmission?		
	Yes	87 (51.8%)
	No	42 (25%)
	Not sure	39 (23.2%)
Has your surgical practice changed during COVID era?		
	Yes	93 (55.4%)
	No	65 (38.7%)
	Only for COVID positive cases	10 (6%)
Have you made preoperative COVID testing mandatory?		
	Yes	121 (72%)
	No, only for suspected cases	23 (13.7%)
	My institute has a mandatory testing policy	24 (14.3%)
Which test do you advise preoperatively?		
	RT-PCR for COVID-19	137 (81.5%)
	COVID-19 antibodies	24 (14.3%)
	Rapid antigen	7 (4.2%)
Which mask do you use?		
	Surgical mask	103 (61.3%)
	KN95	34 (20.2%)
	N95	21 (12.5%)
	Full face respirator	10 (6%)
Do you wear eye protection equipment?		
	Yes	29 (17.3%)
	No	139 (82.7%)
Do you wear coverall suit?		
	Yes	10 (6%)
	No	158 (94%)
Does your OR have AGSS installed?		
	Yes	12 (7.1%)
	No	137 (81.5%)
	Don't know	19 (11.3%)
Does your OR have negative pressure system?		
	Yes	9 (8.3%)
	No	113 (64.3%)
	Don't know	46 (27.4%)
Do you use a smoke evacuation system while doing laparoscopic surgery?		
	Yes	9 (5.4%)
	No	159 (94.6%)
OR having HEPA or ULPA filter system		
	Yes	12 (7.1%)
	No	131 (78%)
	Don't know	25 (14.9%)
Maintaining intra-abdominal pressure lower than usual (<12 mm Hg)		
	Yes	30 (17.9%)
	No	115 (68.5%)
	Sometimes	23 (13.7%)

(Contd...)

**Table 2:** (Contd...)

Questions	Responses	Number (%)
Change in position of the patient (minimizing the degree of Trendelenburg position)		
	Yes	10 (6%)
	No	158 (94%)
Avoiding use of energy devices		
	Yes	20 (11.9%)
	No	148 (88.1%)
Exsufflation of pneumoperitoneum using vacuum suction unit before closure or conversion		
	Yes	95 (56%)
	No	54 (32.1%)
	Sometimes	19 (11.3%)

risks to health during laparoscopy. Laparoscopy brings about the generation of aerosols as it requires the establishment and efficient pneumoperitoneum maintenance through CO<sub>2</sub> insufflation. A study found that after 10 minutes of laparoscopic dissection by ultrasound or electrosurgery, in comparison to dissection in open surgery, there was an elevation of the concentration of particles measuring 0.3–0.5 µm.<sup>7</sup> Also, there is a possible increased threat of transmission to HCPs in surgical theaters by laparoscopy due to gas leakage of the pneumoperitoneum which may hold suspended viruses in soaring concentration.<sup>5</sup> However, in the literature, only a small number of reports have related to this feared risk of transmission of viruses to the surgical team via inhalation from patients undergoing LS. Our findings revealed that only 51.8% of surgeons believed that LS carries an increased risk of COVID-19 transmission, out of which 61.3% were females and only 49.6% were males. About 55.8% of the surgeons admitted to having brought changes to their practices during the COVID-19 era.

DesCoteaux et al. demonstrated that the cautery smoke produced in the course of laparoscopic interventions has breathable aerosols and cell-size fragments.<sup>8</sup> It has very tiny particles (5%), diffused in water vapor (95%), that are not only able to go across the surgical masks but also inoculate the conjunctival layer in the eye.<sup>8–10</sup> Long before the COVID-19 pandemic, these understandings resulted in the proposal of advanced protective measures in the operating room (OR) like respirator masks, FFP2 or higher, sealing wrap goggles, and air filtration devices, though the implementation remained lacking largely.<sup>9,11</sup> The concentration of aerosolized particles lessens with the lowering of insufflation pressures and minimizing the duration and power of energy devices. The process of intubation, OR air pressure, intra-abdominal pressure, desufflator, smoke evacuation, and tissue extraction are some of the potential routes for viral contamination in the OR during LS, the most potent of which is intubation and extubation.<sup>12</sup>

RT-PCR for COVID-19 is strongly recommended for testing of surgical patients before operative interventions; however, 10–30% false-negative rate precludes guaranteeing non-infectivity.<sup>13</sup> For this reason, wearing complete PPE, limiting elective hospitalizations, and spacing surgeries with keeping 30 minutes 1 hour between them is recommended.<sup>5,13–15</sup> The International Endoscopic Surgery Societies have been propounding the risk of aerosolization of particles in advocacy to avoid laparoscopic approach in COVID-19-positive and suspected patients, which has led to preventive measures being defined more coherently with time. These include



**Table 3:** Comparison of practices with reference to gender and teaching involvement

Questions	Responses	Gender		p-value	Involved in teaching		p-value
		Male number (%)	Female number (%)		Yes number (%)	No number (%)	
Does LS carry additional risk of COVID-19 transmission?							
	Yes	68 (49.6%)	19 (61.3%)	0.001*	17 (60.7%)	70 (50%)	0.04*
	No	42 (30.7%)	0 (0%)		11 (39.3%)	31 (22.1%)	
	Not sure	27 (19.7%)	12 (38.7%)		0 (0%)	39 (27.9%)	
Has your surgical practice changed during COVID era?							
	Yes	71 (51.8%)	22 (71%)	0.088	15 (53.6%)	78 (55.7%)	0.281
	No	56 (40.9%)	9 (29%)		13 (46.4%)	52 (37.1%)	
	Only for COVID positive cases	10 (7.3%)	0 (0%)		0 (0%)	10 (7.1%)	
Have you made preoperative COVID testing mandatory?							
	Yes	111 (81%)	10 (32.3%)	0.000*	26 (92.9%)	95 (67.9%)	0.02*
	No, only for suspected cases	14 (10.2%)	9 (29%)		0 (0%)	23 (16.4%)	
	My institute has a mandatory testing policy	12 (8.8%)	12 (38.7%)		2 (7.1%)	22 (15.7%)	
Which test do you advise preoperatively?							
	RT-PCR for COVID-19	118 (86.1%)	19 (61.3%)	0.000*	26 (92.9%)	111 (79.3%)	0.209
	COVID-19 antibodies	12 (8.8%)	12 (38.7%)		2 (7.1%)	22 (15.7%)	
	Rapid antigen	7 (5.1%)	0 (0%)		0 (0%)	7 (5%)	
Which mask do you use?							
	Surgical mask	72 (52.6%)	31 (100%)	0.000*	19 (67.9%)	84 (60%)	0.117
	KN95	34 (24.8%)	0 (0%)		3 (10.7%)	31 (22.1%)	
	N95	21 (15.3%)	0 (0%)		6 (21.4%)	15 (10.7%)	
	Full face respirator	10 (7.3%)	0 (0%)		0 (0%)	10 (7.1%)	
Do you wear eye protection equipment?							
	Yes	29 (21.2%)	0 (0%)	0.05	2 (7.1%)	27 (19.3%)	0.121
	No	108 (78.8%)	31 (100%)		26 (92.9%)	113 (80.7%)	
Do you wear coverall suit?							
	Yes	0 (0%)	10 (32.3%)	0.000*	2 (7.1%)	8 (5.7%)	0.771
	No	137 (100%)	21 (67.7%)		26 (92.9%)	132 (94.3%)	
Does your OR have AGSS installed?							
	Yes	12 (8.8%)	0 (0%)	0.000*	2 (7.1%)	10 (7.1%)	0.115
	No	118 (86.1%)	19 (61.3%)		26 (92.9%)	111 (79.3%)	
	Don't know	7 (5.1%)	12 (38.7%)		0 (0%)	19 (13.6%)	
Does your OR have negative pressure system?							
	Yes	9 (6.6%)	0 (0%)	0.173	4 (14.3%)	5 (3.6%)	0.071
	No	94 (68.6%)	19 (61.3%)		17 (60.7%)	96 (68.6%)	
	Don't know	34 (24.8%)	12 (46%)		7 (25%)	39 (27.9%)	
Do you use a smoke evacuation system while doing laparoscopic surgery?							
	Yes	0 (0%)	9 (29%)	0.000*	0 (0%)	9 (6.4%)	0.168
	No	137 (100%)	22 (71%)		28 (100%)	22 (93.6%)	
OR having HEPA or ULPA filter?							
	Yes	0 (0%)	12 (38.7%)	0.000*	0 (0%)	12 (8.6%)	0.033*
	No	112 (81.8%)	19 (61.3%)		20 (71.4%)	111 (79.3%)	
	Don't know	25 (18.2%)	0 (0%)		7 (28.6%)	17 (12.1%)	
Maintaining intrabdominal pressure lower than Usual (<12 mm Hg)?							
	Yes	20 (14.6%)	10 (32.3%)	0.000*	5 (17.9%)	25 (17.9%)	0.995
	No	103 (75.2%)	12 (38.7%)		19 (67.9%)	96 (68.6%)	
	Sometimes	14 (10.2%)	9 (29%)		4 (14.3%)	19 (13.6%)	

(Contd...)

Table 3: (Contd...)

Questions	Responses	Gender		p-value	Involved in teaching		p-value
		Male number (%)	Female number (%)		Yes number (%)	No number (%)	
Change in position of the patient (minimizing the degree of Trendelenburg position)?							
	Yes	10 (7.3%)	0 (0%)	0.121	1 (3.6%)	9 (6.4%)	0.560
	No	127 (92.7%)	31 (100%)		27 (96.4%)	131 (93.6%)	
Avoiding use of energy devices?							
	Yes	20 (14.6%)	0 (0%)	0.023*	3 (10.7%)	17 (12.1%)	0.831
	No	117 (85.4%)	31 (100%)		25 (89.3%)	123 (87.9%)	
Exsufflation of pneumoperitoneum using vacuum suction unit before closure or conversion?							
	Yes	75 (54%)	21 (67.7%)	0.000*	16 (57.1%)	79 (56.4%)	0.120
	No	54 (39.4%)	0 (0%)		6 (21.4%)	48 (34.3%)	
	Sometimes	9 (6.6%)	10 (32.3%)		6 (21.4%)	13 (9.3%)	

\*p-value < 0.05 denoting statistical significance. Involve in teaching = Academic surgeons involved in teaching and training undergraduate and postgraduate students

Table 4: Comparison of practices in between specialties

Questions	Responses	Specialty				p-value
		GS number (%)	MIS number (%)	OB-GYN number (%)	Urologists number (%)	
Does MIS carry additional risk of COVID-19 transmission?						
	Yes	61 (62.2%)	15 (62.5%)	11 (45.8%)	0 (0%)	0.000*
	No	24 (24.5%)	5 (20.8%)	1 (4.2%)	12 (54.4%)	
	Not sure	13 (13.3%)	4 (16.7%)	12 (50%)	10 (45.5%)	
Has your surgical practice changed during COVID era?						
	Yes	48 (49%)	10 (41.7%)	23 (95.8%)	12 (54.5%)	0.000*
	No	50 (51%)	14 (58.3%)	1 (4.2%)	0 (0%)	
	Only for COVID positive cases	0 (0%)	0 (0%)	0 (0%)	10 (45.5%)	
Have you made preoperative COVID testing mandatory?						
	Yes	75 (76.5%)	24 (100%)	12 (50%)	10 (45.5%)	0.000*
	No, only for suspected cases	23 (23.5%)	0 (0%)	0 (0%)	0 (0%)	
	My institute has a mandatory testing policy	0 (0%)	0 (0%)	12 (50%)	12 (54.5%)	
Which test do you advise preoperatively?						
	RT-PCR for COVID-19	91 (92.9%)	24 (100%)	12 (50%)	10 (45.5%)	0.000*
	COVID-19 antibodies	0 (0%)	0 (0%)	12 (50%)	12 (54.5%)	
	Rapid antigen	7 (7.1%)	0 (0%)	0 (0%)	0 (0%)	
Which mask do you use?						
	Surgical mask	55 (56.1%)	15 (62.5%)	23 (95.8%)	10 (45.5%)	0.000*
	KN95	28 (28.6%)	5 (20.8%)	1 (4.2%)	0 (0%)	
	N95	9 (9.2%)	0 (0%)	0 (0%)	12 (54.5%)	
	Full face respirator	6 (6.1%)	4 (16.7%)	0 (0%)	0 (0%)	
Do you wear eye protection equipment?						
	Yes	13 (13.3%)	4 (16.7%)	0 (0%)	12 (54.5%)	0.000*
	No	85 (86.7%)	20 (83.3%)	24 (100%)	10 (45.5%)	
Do you wear coverall suit?						
	Yes	0 (0%)	0 (0%)	10 (41.7%)	0 (0%)	0.000*
	No	98 (100%)	24 (100%)	14 (58.3%)	22 (100%)	
Does your OR have AGSS installed?						
	Yes	0 (0%)	0 (0%)	0 (0%)	12 (54.5%)	0.000*
	No	91 (92.9%)	24 (100%)	12 (50%)	10 (45.5%)	
	Don't know	7 (7.1%)	0 (0%)	12 (50%)	0 (0%)	

(Contd...)

Table 4: (Contd...)

Questions	Responses	Specialty				p-value
		GS number (%)	MIS number (%)	OB-GYN number (%)	Urologists number (%)	
Does your OR have negative pressure system?						
	Yes	4 (4.1%)	5 (20.8%)	0 (0%)	0 (0%)	0.000*
	No	76 (77.6%)	14 (58.3%)	11 (45.8%)	12 (54.5%)	
	Don't know	18 (18.4%)	5 (20.8%)	13 (54.2%)	10 (45.5%)	
Do you use a smoke evacuation system while doing laparoscopic surgery?						
	Yes	9 (9.2%)	0 (0%)	0	0 (0%)	0.079
	No	89 (90.8%)	24 (100%)	24 (100%)	22 (100%)	
OR having HEPA or ULPA filter						
	Yes	0 (0%)	0 (0%)	12 (50%)	0 (0%)	0.000*
	No	78 (79.6%)	19 (79.2%)	12 (50%)	22 (100%)	
	Don't know	20 (20.4%)	5 (20.8%)	0 (0%)	0 (0%)	
Maintaining intrabdominal pressure lower than usual (<12 mm Hg)						
	Yes	20 (20.4%)	0 (0%)	10 (41.7%)	0 (0%)	0.000*
	No	55 (56.1%)	24 (100%)	14 (58.3%)	22 (100%)	
	Sometimes	23 (23.5%)	0 (0%)	0 (0%)	0 (0%)	
Change in position of the patient (minimizing the degree of Trendelenburg position)						
	Yes	10 (10.2%)	0 (0%)	0 (0%)	0 (0%)	0.055
	No	88 (89.8%)	24 (100%)	24 (100%)	22 (100%)	
Avoiding use of energy devices						
	Yes	20 (20.4%)	0 (0%)	0 (0%)	0 (0%)	0.001*
	No	78 (79.6%)	24 (100%)	24 (100%)	22 (100%)	
Exsufflation of pneumoperitoneum using vacuum suction unit before closure or conversion						
	Yes	73 (74.5%)	9 (37.5%)	13 (54.2%)	0 (0%)	0.000*
	No	21 (21.4%)	10 (41.7%)	1 (4.2%)	22 (100%)	
	Sometimes	4 (4.1%)	5 (20.8%)	10 (41.7%)	0 (0%)	

\*p-value < 0.05 denoting statistical significance. GS, general surgeons; MIS, minimally invasive surgeons; OB-GYN, obstetricians and gynecologists

appropriate PPE, proper room filtration, ventilation, and installation of smoke evacuation–filtration system.<sup>5,14</sup> Wong et al. stressed on using certified N95 respirators, face shields or eye goggles in addition to routine protective gadgets.<sup>16</sup> Owing to the possibility of transmission even with N95 masks, employing a powered air purifying respirator (PAPR) during procedures involving the generation of aerosols when operating on COVID-positive or suspected-positive cases is strongly recommended. Repici and colleagues advocated advanced measures and novel equipment for protection in endoscopic undertakings.<sup>17</sup> The Zhejiang University School of Medicine's Handbook of COVID-19 Prevention and Treatment gives an account of vital findings and essence from the initial waves advising level III protection during all kinds of surgeries, ORs with negative pressure systems with some other precautionary measures.<sup>18</sup> All aforementioned studies place special emphasis on the significance of protecting HCPs with apt PPE, be they examining or operating upon the patients. According to our findings, only 12.5% of surgeons wore N95 masks during surgeries, while 61.3% wore surgical masks which don't provide sufficient protection. Notable, 52.6% of male surgeons used surgical masks, 24.8% KN95, 15.3% N95, and a full face respirator were worn by 7.3%, in contrast, all-female surgeons (100%) chose to wear surgical masks. Furthermore, only 17.3% of all surgeons wore eye protection (21.2% males and 0% females) and only 6% wore protective cover all suits (32.3% females and 0% males). Even though these findings

are statistically significant, they point towards a much larger lack of adherence to existing guidelines for protection against COVID-19 transmission.

A negative pressure OR environment prevents air from escaping the OR, making it the perfect tool for preventing virus transmission.<sup>16</sup> Operating in a negative pressure system installed ORs was among the common and strong recommendations of both the American Society of Gastrointestinal Endoscopy and the Society of American Gastrointestinal and Endoscopic Surgeons (SAGES).<sup>19,20</sup> Wax and Christian also concurred with this and included it in their set of practical recommendations.<sup>21</sup> A review of the preparedness of OR measures and responses in COVID-19 from anesthetists of Singapore General Hospital entailed their efforts of making dedicated ORs with committed ventilation systems and HEPA filters for COVID-19 suspected and diseased patients. Maintaining a single entry and exit route through the scrubbing lobby and implementing locked-OR doors protocol during surgical interventions were part of a plan to reduce transmission by controlling traffic and airflow.<sup>16</sup> However, unfortunately, only 8.3% of surgeons in our study reported working in negative-pressure ORs despite the existence of formal guidelines, hence highlighting an infrastructural weakness in healthcare systems that needs to be given focused attention in order to minimize transmission of SARS-CoV-2.

Previous researchers have demonstrated the toxic potential of surgical smoke alongside several other plausible risks during

operative interventions.<sup>10</sup> This is especially relevant when laser aerosolizes contaminated tissue rich in infectious living and dead agents. The expected debris produced from different types of energy devices commonly employed in open and minimally invasive abdominal operations namely Ultrasonic scalpel, laser ablation, and electrocautery are 0.35–6.5 microns, 0.3 microns, and less than 0.1 microns respectively.<sup>22</sup> Even though the exact potential of coronavirus to aerosolize in the abdomen is not known, abstaining from electrosurgical dissection and certain energy devices, e.g., ultrasonic scalpel, may reduce the danger of viral emission by reducing particle aerosolization. Moreover, surgical smoke filtration systems have proven to be beneficial in protecting against the infectious potential of SARS-Cov-2. Given that the virus size ranges from 0.070 to 0.075  $\mu\text{m}$ , the recommended filters are HEPA, with an efficiency of 99.97% in removing particles  $> 0.03 \mu\text{m}$  diameter or ULPA filters, which can filter particles  $> 0.05 \mu\text{m}$  size. All surgical societies (SAGES, EAES, AMASI, IAGES) have adopted a set of measures to minimize the emission of aerosols during the intervention, consisting of the reduced pressure of the pneumoperitoneum, tight incisions to prevent leakage at the trocar orifices, minimum use of energy devices and use of cold hemostasis whenever possible, and integrated insufflation devices comprising smoke evacuation and filtration mode (HEPA/ULPA).<sup>6,23–26</sup> According to our data, only 5.3% of surgeons reported having used smoke evacuation systems during laparoscopic surgeries, only 7.1% reported having used HEPA or ULPA filters, and only 11.9% had avoided the use of energy devices. Unfortunately, discrepancies also existed between the practices of male and female surgeons as evident by the fact that 29% of female surgeons reported using smoke evacuation systems against an alarming 0% of male surgeons. Furthermore, 38.7% of female surgeons reported using HEPA/ULPA filters against yet another 0% of male surgeons. On the other hand, 14.6% of male surgeons interestingly reported avoiding the use of energy devices against 0% of female surgeons.

The debate on whether to prefer open surgery or LS during the pandemic will probably go on, but the gist of it can be understood by the fact that the Royal College of Surgeons of England had advocated caution for surgeons in considering LS, and the Society of American Gastrointestinal and Endoscopic Surgeon (SAGES) had recommended filtering released  $\text{CO}_2$  by employing apt filter systems during LS and robotic surgery.<sup>6,27</sup> On the contrary, the Association of Laparoscopic Surgeons of Great Britain and Ireland (ALSGBI) backed the use of the laparoscopic approach while the American College of Surgeons was of the opinion that in light of insufficient statistical evidence to propound for or against preferring open over LS approach, surgeons should bank on the approach with lesser operative duration and maximum safety.<sup>28,29</sup> Considering the differences in the practices of surgeons on multiple strata described in our study, and the lack of an established consensus on the link of LS to COVID-19 transmission, it is clear that there needs to be a collective effort by all stakeholders in healthcare to adhere to international guidelines for LS during COVID-19 as the slightest violation of the precautions or a lack of compliance may pose a significant danger for the entire OR staff, causing them additional psychological stress. On this ground, it would be worthwhile to limit the traffic of personnel in the OR, abstain from complex and complicated maneuvers, and assign experienced personnel.<sup>5,14,15</sup>

## CONCLUSION

The COVID-19 era has had a widespread effect on surgical practice and the healthcare system. This study shows the wide variation in LS practices and the lack of adherence to the recommendations of international Laparoscopic Surgical Associations in Pakistan. We feel that there is a dire need for efforts to establish a consensus and formulate practical local guidelines for surgeons involved in LS, tailored to the country's healthcare system.

## Clinical Significance

As a result of COVID-19, Pakistan has not only experienced a change in surgical practices in healthcare settings but has also struggled to provide the equipment and infrastructure necessary to adhere to various international guidelines. Our data only shows a glimpse of this situation in Pakistan and other developing countries, calling for combined efforts to raise awareness, establishing suitable OR environments with safety systems, and devising and implementing local and regional consensus guidelines.

## ORCID

Syed Ali Haider  <https://orcid.org/0000-0002-8156-1576>

Muhammad Zubair  <https://orcid.org/0000-0003-1140-1646>

Sumera Qazi  <https://orcid.org/0000-0002-3945-9500>

## REFERENCES

1. Worldometer. COVID-19 Coronavirus Pandemic. Worldometer. Available from: <https://www.worldometers.info/coronavirus>.
2. Pakistan Scientific and Technological Information Centre (PASTIC). COVID-19 S and T information resource portal. Available from: <http://covid.pastic.gov.pk>.
3. Gupta N, Agrawal H. COVID 19 and laparoscopic surgeons, the Indian scenario-perspective. *Int J Surg* 2020;79:165–167. DOI: 10.1016/j.ijsu.2020.05.076.
4. Ng K, Poon BH, Kiat Puar TH, et al. COVID-19 and the risk to health care workers: A case report. *Ann Intern Med* 2020;172(11):766–767. DOI: 10.7326/L20-0175.
5. Zheng MH, Boni L, Fingerhut A. Minimally invasive surgery and the novel coronavirus outbreak: Lessons learned in China and Italy. *Ann Surg* 2020;272(1):e5–e6. DOI: 10.1097/SLA.0000000000003924.
6. Francis N, Dort J, Cho E, et al. SAGES and EAES recommendations for minimally invasive surgery during COVID-19 pandemic. *Surg Endosc* 2020;34(6):2327–2331. DOI: 10.1007/s00464-020-07565-w.
7. Li CI, Pai JY, Chen CH. Characterization of smoke generated during the use of surgical knife in laparotomy surgeries. *J Air Waste Manag Assoc* 2020;70(3):324–332. DOI: 10.1080/10962247.2020.1717675.
8. DesCoteaux JG, Picard P, Poulin EC, et al. Preliminary study of electrocautery smoke particles produced in vitro and during laparoscopic procedures. *Surg Endosc* 1996;10(2):152–158. DOI: 10.1007/BF00188362.
9. Mowbray NG, Ansell J, Horwood J, et al. Safe management of surgical smoke in the age of COVID-19. *Br J Surg* 2020;107(11):1406–1413. DOI: 10.1002/bjs.11679.
10. Barrett WL, Garber SM. Surgical smoke: A review of the literature. Is this just a lot of hot air? *Surg Endosc* 2003;17(6):979–987. DOI: 10.1007/s00464-002-8584-5.
11. Dobrogowski M, Wesołowski W, Kucharska M, et al. Chemical composition of surgical smoke formed in the abdominal cavity during laparoscopic cholecystectomy – Assessment of the risk to the patient. *Int J Occup Med Environ Health* 2014;27(2):314–325. DOI: 10.2478/s13382-014-0250-3.
12. American Society of Anesthesiologists. ASA-APSF joint statement on non-urgent care during the COVID-19 outbreak. American Society of Anesthesiologists. Available from: <https://www.asahq.org>.



13. Tivey DR, Davis SS, Kovoor JG, et al. Safe surgery during the coronavirus disease 2019 crisis. *ANZ J Surg* 2020;90(9):1553–1557. DOI: 10.1111/ans.16089.
14. Joseph JP, Joseph AO, Oomman S, et al. Laparoscopic versus open surgery: Aerosols and their implications for surgery during the COVID-19 pandemic. *Eur Surg* 2020 52(4):188–189. DOI: 10.1007/s10353-020-00644-1.
15. Guraya SY. Transforming laparoendoscopic surgical protocols during the COVID-19 pandemic; Big data analytics, resource allocation and operational considerations. *Int J Surg* 2020;80:21–25. DOI: 10.1016/j.ijssu.2020.06.027.
16. Wong J, Goh QY, Tan Z, et al. Preparing for a COVID-19 pandemic: A review of operating room outbreak response measures in a large tertiary hospital in Singapore. *Can J Anaesth* 2020;67(6):732–745. DOI: 10.1007/s12630-020-01620-9.
17. Repici A, Aragona G, Cengia G, et al. Low risk of COVID-19 transmission in GI endoscopy. *Gut* 2020;69(11):1925–1927. DOI: 10.1136/gutjnl-2020-321341.
18. Liang T. Handbook of COVID-19 prevention and treatment. The First Affiliated Hospital, Zhejiang University School of Medicine, 2020. pp. 1–68.
19. ASGE Quality Assurance in Endoscopy Committee; Calderwood AH, Day LW, et al. ASGE guideline for infection control during GI endoscopy. *Gastrointest Endosc* 2018;87(5):1167–1179. DOI: 10.1016/j.gie.2017.12.009.
20. American Society for Gastrointestinal Endoscopy. Joint GI Society Message: COVID-19 clinical insights for our community of gastroenterologists and gastroenterology care providers. Available from: <https://www.asge.org/home/joint-gi-society-message-covid-19>.
21. Wax RS, Christian MD. Practical recommendations for critical care and anesthesiology teams caring for novel coronavirus (2019-nCoV) patients. *Can J Anaesth* 2020;67(5):568–576. DOI: 10.1007/s12630-020-01591-x.
22. Alp E, Bijl D, Bleichrodt RP, et al. Surgical smoke and infection control. *J Hosp Infect* 2006;62(1):1–5. DOI: 10.1016/j.jhin.2005.01.014.
23. Shabbir A, Menon RK, Somani J, et al. ELSA recommendations for minimally invasive surgery during a community spread pandemic: A centered approach in Asia from widespread to recovery phases. *Surg Endosc* 2020;34(8):3292–3297. DOI: 10.1007/s00464-020-07618-0.
24. Moletta L, Pierobon ES, Capovilla G, et al. International guidelines and recommendations for surgery during Covid-19 pandemic: A Systematic Review. *Int J Surg* 2020;79:180–188. DOI: 10.1016/j.ijssu.2020.05.061.
25. Campanile FC, Podda M, Arezzo A, et al. Acute cholecystitis during COVID-19 pandemic: A multisocietary position statement. *World J Emerg Surg* 2020;15(1):38. DOI: 10.1186/s13017-020-00317-0.
26. Porter J, Blau E, Gharagozloo F, et al. Society of robotic surgery review: Recommendations regarding the risk of COVID-19 transmission during minimally invasive surgery. *BJU Int* 2020;126(2):225–234. DOI: 10.1111/bju.15105.
27. Royal College of Surgeons of England. Updated Intercollegiate General Surgery Guidance on COVID-19. Available from: <https://www.rcseng.ac.uk/coronavirus/joint-guidance-for-surgeons-v2>.
28. El Boghdady M, Ewalds-Kvist BM. Laparoscopic Surgery and the debate on its safety during COVID-19 pandemic: A systematic review of recommendations. *Surgeon* 2021;19(2):e29–e39. DOI: 10.1016/j.surge.2020.07.005.
29. American College of Surgeons. COVID-19: Elective case triage guidelines for surgical care. Available from: <https://www.facs.org/covid-19/clinical-guidance/elective-case>.

## CASE REPORT

# Co-existent Classical Maydl's and Amyand's Hernias: A Rare Case Report

Shashank Shah<sup>1</sup>, Sushil Kumar Kharat<sup>2</sup>, Elmutaz Abdalla Mekki Kanani<sup>3</sup>, Adrian Gerard<sup>4</sup>

Received on: 30 December 2022; Accepted on: 20 February 2023; Published on: 14 February 2024

### ABSTRACT

**Aim:** The aim of this case report is to highlight the advantages of laparoscopy in the management of incarcerated, obstructed, and strangulated hernia.

**Background:** Inguinal hernias account for three-quarters of all abdominal wall hernias. They may present as emergencies and require quick and accurate diagnosis followed by prompt management in order to prevent undesirable consequences. The surgeon has to select the appropriate treatment approach from limited options. In this case report we are aiming to solidify the laparoscopy as an additional weapon in the surgeon's armamentarium.

**Case description:** This is a case of an unusual type of obstructed indirect inguinal hernia with impending strangulation. Diagnostic laparoscopy findings revealed a Maydl's hernia and an adherent inflamed appendix in a long-standing congenital inguinal indirect hernia. In addition to this, extensive small bowel adhesions were also seen.

**Conclusion:** This case highlights the superiority of laparoscopy compared to clinical/image judgment in incarcerated, obstructed, or strangulated hernia.

**Keywords:** Amyand, Case report, Inguinal hernia, Laparoscopy, Maydl.

*World Journal of Laparoscopic Surgery* (2024): 10.5005/jp-journals-10033-1601

### BACKGROUND

The overall incidence of abdominal wall hernia is approximately 1.7%, but the incidence generally increases up to 4% after the age of 45 years and three-quarters of these hernias are inguinal, which are more common in men than women.<sup>1</sup> Congenital type inguinal hernia is also prevalent, being diagnosed in childhood or later in adult life. Inguinal hernia repair is one of the most commonly performed surgical procedures. Some conditions like smoking, chronic obstructive pulmonary disease (COPD), prolonged heavy weight lifting, positive family history, appendectomy, and peritoneal dialysis may predispose to its development.<sup>2</sup> The inguinal hernia may present as an intermittent/persistent painless lump, or a painful lump in case of obstruction/strangulation. Clinical diagnosis eliminates the need for additional diagnostic work up and imaging studies.<sup>3</sup> Treatment is usually surgical if symptomatic. Various surgical therapeutic procedures are performed around the world with varying degrees of success. However, the treatment of hernia was revolutionized by the introduction of synthetic mesh and later by the utilization of the laparoscopic approach. There are some unique inguinal hernias that present diagnostic and management challenges, such as Maydl's and Amyand's hernias. They are rare and mostly diagnosed during operation. Knowledge of such variations is mandatory as they require special operative management strategy. We present a rare case of coexisting Maydl's and Amyand's hernias presenting as an obstructed inguinal hernia. To the best of our knowledge, this is the first such case to be reported.

### CASE DESCRIPTION

A 65-year-old male with no previous surgical history was admitted through the emergency room with a 4-day history of painful, irreducible swelling of his right groin. He has had self-remitting

<sup>1-4</sup>Department of General Laparoscopic and Bariatric Surgery, LOC Healthcare LLP, Pune, Maharashtra, India

**Corresponding Author:** Elmutaz Abdalla Mekki Kanani, Department of General Laparoscopic and Bariatric Surgery, LOC Healthcare LLP, Pune, Maharashtra, India, Phone: +91 9028307136, e-mail: mutazkanani313@hotmail.com

**How to cite this article:** Shah S, Kharat SK, Kanani EAM, et al. Co-existent Classical Maydl's and Amyand's Hernias: A Rare Case Report. *World J Lap Surg* 2024;17(1):52–54.

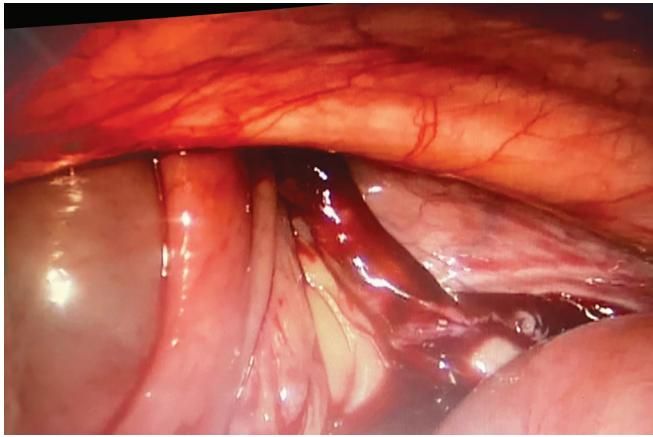
**Source of support:** Nil

**Conflict of interest:** None

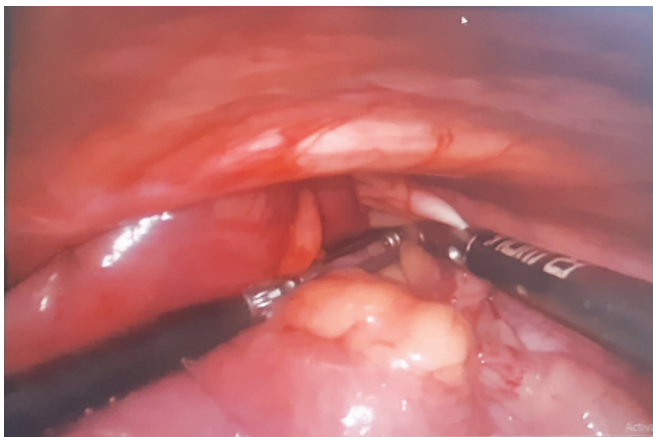
**Patient consent statement:** The author(s) have obtained written informed consent from the patient for publication of the case report details and related images.

occasional painful groin swelling for over a year but it suddenly got bigger with persistent pain. Symptoms included vomiting, progressive abdominal pain, mild abdominal distension, and constipation. Clinical evaluation revealed a blood pressure of 110/70 mm Hg, heart rate 96 min, respiratory rate 24 min, and 37.8°C body temperature. There was a painful, tense, non-reducible, pear-shaped, 5 × 3 cm lump on the right groin. An urgent diagnostic laparoscopy was performed; after adequate resuscitation; for a suspected strangulated right inguinal hernia. It revealed a tight right deep inguinal ring with ileal loops forming a W-shaped orientation and an adherent inflamed appendix as the hernia sac content (Figs 1 and 2). Dense adhesions were noted between the ileal loops.

Appendicectomy was performed after adhesiolysis. However, it was difficult to reduce the intestinal loop by laparoscopy hence



**Fig. 1:** The W-shaped orientation of ileal loops (note the brown-colored free fluid)



**Fig. 2:** The inflamed appendix: base can be seen; tip still adherent inside the hernia sac

an oblique right groin incision was made. An indirect hernia sac was encountered with the testis and a loop of small intestine as content. The tight deep ring was divided to facilitate reduction of the dusky and edematous bowel surrounded by dark-brown free fluid. With 100% oxygenation and warm saline fomentation, the intestinal loop regained normal color and peristaltic contraction. An orchidectomy was performed and the hernia sac was excised. Moloney's darn hernia repair was carried out. Manual bowel decompression and adhesiolysis were then performed through the slightly extended umbilical port incision. The patient made a smooth recovery and was discharged on the 5th postoperative day. Histopathological examination confirmed the diagnosis of acute appendicitis.

## DISCUSSION

A Maydl hernia is a rare variant of an inguinal hernia and occurs when there are two loops of small intestine within a single hernia sac, forming a "W" shape. Therefore, it is called a "W hernia" or "hernia-in-W" and it is particularly more susceptible to strangulation and the intervening intra-abdominal loop is also at risk of a closed loop obstruction.<sup>4</sup>

Although there is a scarcity of literature regarding Maydl's hernia, in their review, Narang et al. reported resection of various parts of the intestine as a result of Maydl's hernia and the incidence

of strangulation ranged between 0.6 and 1.9%,<sup>5</sup> similar to the suggestion of Weledji et al. (<2%).<sup>6</sup> Therefore, prompt surgical intervention is mandatory if Maydl's hernia is suspected.

The presence of an inflamed appendix in an inguinal hernia sac is called an Amyand hernia, in memory of Claudius Amyand (1660–1740), who reportedly performed the first appendectomy within an inguinal hernia.<sup>7</sup> It is difficult to determine with certainty the true prevalence of Amyand's hernia. An incidence from 0.14 to 1.3% when only the appendix is present within an inguinal hernia sac has been reported in retrospective studies, whereas the presence of appendicitis in the inguinal hernia is still rarer, arguably from 0.07 to 0.13%.<sup>7</sup>

Amyand's hernia contains an inflamed or perforated appendix as content.<sup>8</sup> Scrotal symptoms may be confused with acute hydrocele, testicular torsion, or epididymo-orchitis. Imaging of inguinal hernias is not routine, so preoperative diagnosis is not common.

The surgical management of Amyand's hernia was controversial but Losanoff and Basson came up with their classification in 2007 in an effort to standardize the surgical approach.<sup>9</sup> In summary, they recommend avoiding mesh insertion in the presence of appendicitis and/or sepsis.

Left-sided Amyand's hernia is very rare and may be linked to underlying conditions like situs inversus, malrotation, a mobile caecum, and an excessively long appendix.<sup>7</sup> Appendectomy in cases of left-sided Amyand's hernias should be performed promptly regardless of whether there is inflammation or not. This would avoid future diagnostic dilemmas if appendicitis occurs. Mesh repair is generally contraindicated in the presence of inflammation and infection. In our case, the hernia sac and the testis were removed so only darn repair was sufficient.

In this case the hernia was of the congenital type with persistently patent processus vaginalis, a condition we frequently encounter in adult patients.

## Clinical Significance

The co-existence of both Maydl's and Amyand's hernias with inflamed appendix is exceptionally rare. Preoperative imaging may give a clue in suspected cases but the advantage of diagnostic laparoscopy can't be over-emphasized.

## ORCID

Shashank Shah  <https://orcid.org/0000-0002-2550-0429>

Elmutaz Abdalla Mekki Kanani  <https://orcid.org/0000-0002-4885-6030>

## REFERENCES

1. Jenkins JT, Dwyer PJ. Inguinal hernias. *BMJ* 2008;336:269. DOI: 10.1136/mbj.39450.428275.AD.
2. Simons MP, Aufenacker T, Bay-Nielsen M, et al. European hernia society guidelines on the treatment of inguinal hernia in adult patients. *Hernia* 2009;13:343–403. DOI: <https://doi.org/10.1007/s10029-009-0529-7>.
3. Michalinos A, Moris D, Vernadakis S. Amyand's hernia: A review. *Am J Surg*. 2014;207(6):989–995. DOI: 10.1016/j.amjsurg.2013.07.043.
4. Venkatesh M, Sharma R, Bell D, et al. Maydl hernia. Reference article, *Radiopaedia.org* (Accessed on 04 Nov 2023). DOI: <https://doi.org/10.53347/rld-25969>.
5. Narang RR, Pathania OP, Punjabi PP, et al. Unusual Maydl's hernia (a case report). *J Postgrad Med* 1987;33:137. PMID: 3430401.
6. Weledji EP, Mokake M, Ngowe MN. A rare presentation of Maydl's hernia. *Case Rep Surg* 2014;184873. DOI: 10.1155/2014/184873.

7. Manatakis DK, Tasis N, Antonopoulou MI, et al. Revisiting Amyand's hernia: A 20-year systematic review. *World J Surg* 2021;45(6): 1763–1770. DOI: 10.1007/s00268-021-05983-y.
8. Gao Y, Zhang T, Zhang M, et al. Amyand's hernia: A 10-year experience with 6 cases. *BMC Surg* 2021 23;21(1):315. DOI: 10.1186/s12893-021-01306-z.
9. Perrotti S, Bosco D, Miano D, et al. Incarcerated Amyand's hernia: A case report. *Int J Surg Case Rep* 2018;51:265–267. DOI: 10.1016/j.ijscr.2018.08.064.



## CASE REPORT

# Perforated Strangulated Roux Limb in Diaphragmatic Hernia—A Rare Complication after Laparoscopic Total Gastrectomy for Gastric Cancer: A Case Report

Georgia Roberts<sup>1</sup>, Michael Bozin<sup>2</sup>, Bruce D Wilkie<sup>3</sup>, Phil Chan<sup>4</sup>, Cuong Duong<sup>5</sup>

Received on: 30 June 2023; Accepted on: 21 August 2023; Published on: 14 February 2024

## ABSTRACT

**Aim:** To report a case of a perforated strangulated roux limb in diaphragmatic hernia as a rare complication following laparoscopic total gastrectomy for gastric cancer.

**Background:** As minimally invasive surgery (MIS) becomes increasingly performed for esophagogastric cancers, diaphragmatic hernias (DHs) pose new challenges for surgeons.

**Case description:** We report the case of a 59-year-old patient who presented with hematemesis, epigastric pain, and hemodynamic instability. The patient had a history of gastric adenocarcinoma and had undergone a laparoscopic total gastrectomy 3 years before. The computed tomographic scan demonstrated a diaphragmatic hernia with a strangulated and perforated roux limb. The patient underwent staged resection of the necrotic roux limb to manage sepsis, followed by restoration of alimentary continuity.

**Conclusion:** A diaphragmatic hernia (DH) is a challenging complication of MIS for esophagogastric cancers and may be difficult to prevent. A staged approach was invaluable, allowing for careful assessment, expert opinion, and reconstruction.

**Clinical significance:** As MIS becomes increasingly performed, cases of complicated DH may become more apparent. Preventing DH may be difficult. A sutured crural repair with or without pexy of the roux limb may be performed if DH is identified at the time of gastrectomy. The value of mesh is unclear, and erosion remains a main concern.

**Keywords:** Case report, Diaphragmatic hernia, Gastric cancer, Laparoscopic gastrectomy.

*World Journal of Laparoscopic Surgery* (2024): 10.5005/jp-journals-10033-1570

## BACKGROUND

As minimally invasive surgery (MIS) becomes increasingly performed for esophagogastric cancers, diaphragmatic hernias (DHs) pose new challenges for surgeons.

## CASE DESCRIPTION

Three years after laparoscopic total gastrectomy for adenocarcinoma, a 59-year-old male presented with hemodynamic instability. Imaging confirmed a DH with a strangulated roux limb and perforation into the mediastinum and left upper quadrant (Fig. 1).

A staged approach was taken with the goals of controlling contamination, restoring normal physiology, and definitive reconstruction. An emergency gastroscopy and laparoscopy were performed. Hernia contents were reduced, 20 cm of ischemic roux limb resected, ends left stapled off, and extensive lavage performed. Drains were placed into the mediastinum and subdiaphragmatic space. The patient was admitted to ICU and commenced on broad-spectrum antibiotics, antifungals, and total parenteral nutrition. Ongoing sepsis on day 2 prompted a repeat CT, revealing an undrained posterior mediastinal collection (Fig. 2). To avoid pleural contamination with a thoracoscopic approach, an interventional radiologist successfully drained the collection using CT guidance along a paravertebral trajectory (Fig. 3). Relook laparoscopy on day 4 proved technically challenging due to dense hiatal adhesions. A further small segment of the jejunum was resected back to a healthy esophagus at 39 cm. To establish GI continuity, a

<sup>1</sup>Division of Surgical Oncology, Peter MacCallum Cancer Centre, Melbourne; Department of Surgery, St Vincent's Hospital, Melbourne, Victoria, Australia

<sup>2,3</sup>Division of Surgical Oncology, Peter MacCallum Cancer Centre, Melbourne; Department of Surgery, Royal Melbourne Hospital, Victoria, Australia

<sup>4</sup>Department of Radiology, Peter MacCallum Cancer Centre, Melbourne, Victoria, Australia

<sup>5</sup>Division of Surgical Oncology, Peter MacCallum Cancer Centre, Melbourne, Victoria, Australia

**Corresponding Author:** Georgia Roberts, Division of Surgical Oncology, Peter MacCallum Cancer Centre, Melbourne; Department of Surgery, St Vincent's Hospital, Melbourne, Victoria, Australia, Phone: +61 9231 2211, e-mail: georgiaroberts571@gmail.com

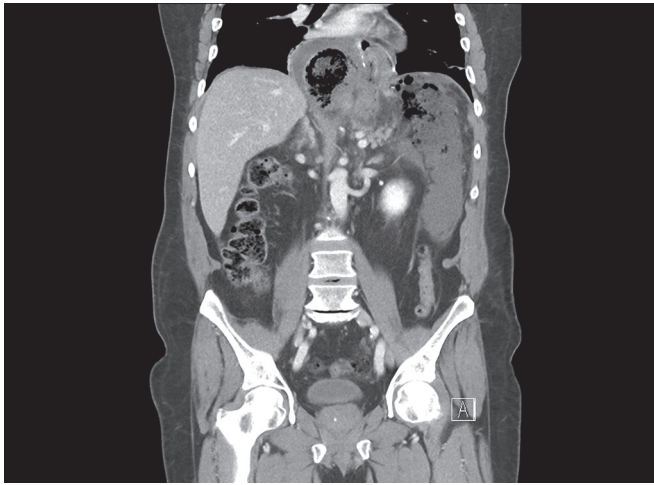**How to cite this article:** Roberts G, Bozin M, Wilkie BD, *et al.* Perforated Strangulated Roux Limb in Diaphragmatic Hernia—A Rare Complication after Laparoscopic Total Gastrectomy for Gastric Cancer: A Case Report. *World J Lap Surg* 2024;17(1):55–57.

**Source of support:** Nil

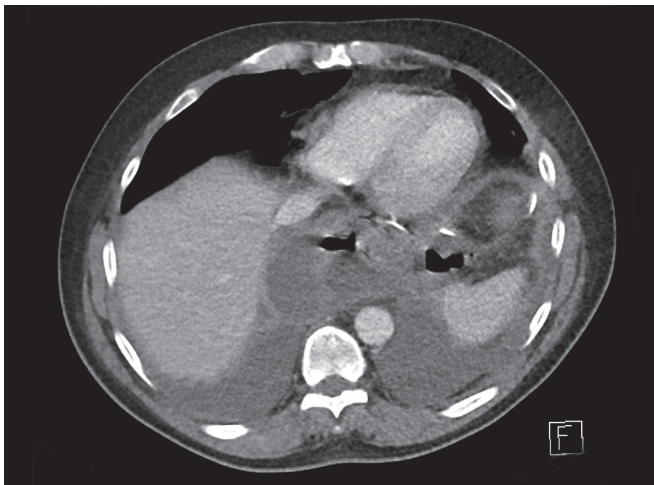
**Conflict of interest:** None

**Patient consent statement:** The author(s) have obtained written informed consent from the patient for publication of the case report details and related images.

laparotomy was undertaken on day 6 because of the technical challenges encountered at the previous laparoscopy. A retrocolic OJ anastomosis was performed using an OrVil® circular stapler.<sup>1</sup>



**Fig. 1:** Coronal contrast-enhanced CT on presentation showing incarcerated and perforated alimentary limb within a recurrent diaphragmatic hernia



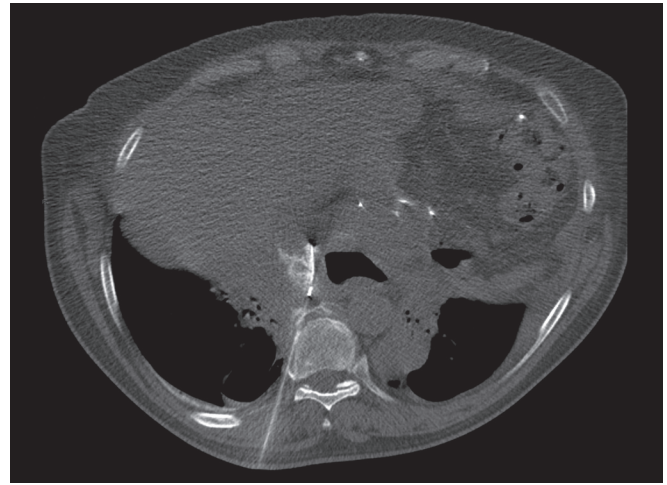
**Fig. 2:** Axial contrast-enhanced CT showing a posterior mediastinal collection situated posterolateral to the esophagus

The roux limb was lengthening and pexied to the crura to prevent future herniation. Remained well 2 years post-discharge with normal swallowing and stable weight.

## DISCUSSION

A review of the literature (MEDLINE and EMBASE) demonstrates the incidence of up to 9% of DH, 6 months after laparoscopic total gastrectomy, with symptomatic DH occurring in 1.6–3.8%.<sup>2–4</sup> Strangulation is rare, as identified in three cases necessitating resection of the small bowel or transverse colon.<sup>2,3,5</sup> Predisposing factors include division of the left crus, regardless of the type of anastomosis and MIS due to reduced adhesion formation.<sup>2,4,6</sup> It has been theorized negative intrathoracic pressure acts as a suction effect, progressively dilating the hiatus.<sup>3</sup> As MIS becomes increasingly performed, cases of complicated DH may become more apparent, particularly in gastric cancer-endemic countries.

Prevention of DH may be difficult. Avoiding disruption of the crura and phreno-esophageal ligament may reduce the suction



**Fig. 3:** Axial CT showing CT-guided micropuncture and hydrodissection technique demonstrating extrapleural route into mediastinal collection

effect from the intrathoracic cavity. This may not be avoidable in very proximal tumors necessitating extended total gastrectomy or cases with pre-existing hiatus hernia. Where preexisting hiatus hernias are identified at surgery, if feasible, we recommend a sutured crural repair with or without crural pexy of the roux limb. The value of mesh is unclear based on limited supporting evidence, and erosion remains our main concern.<sup>3</sup>

## Clinical Significance

As MIS becomes increasingly performed, cases of complicated DH may become more apparent. A staged approach was invaluable, allowing for careful assessment, seeking expert opinion, and reconstruction planning. A sutured crural repair with or without pexy of the roux limb may be performed if DH is identified at the time of gastrectomy in an attempt to prevent further DH. The value of mesh is unclear, and erosion remains a main concern.

## ACKNOWLEDGMENT

Authors would like to thank the patient for their consent to publish case report.

## ORCID

Georgia Roberts  <https://orcid.org/0000-0002-8649-7905>

## REFERENCES

1. Medtronic. DST Series (TM) EEA (TM) OrVil (TM) Device. Minneapolis, USA: Medtronic; 2022 [14 April, 2022]. Available from: <https://www.medtronic.com/covidien/en-us/support/products/surgical-stapling/dst-series-eea-orvil-devices.html>.
2. Gong CS, Ko CS, Kim BS, et al. Diaphragmatic hernia after totally laparoscopic total gastrectomy for gastric cancer. *Surg Laparosc, Endosc Percutan Tech* 2019;29(3):194–199. DOI: 10.1097/SLE.0000000000000638.
3. Urabe M, Haruta S, Ohkura Y, et al. Diaphragmatic herniation following total gastrectomy: Review of the long-term experience of a tertiary institution. *Langenbecks Archives Surg* 2019;404(8):993–998. DOI: 10.1007/s00423-019-01842-6.
4. Ito E, Ohdaira H, Nakashima K, et al. Crus incision without repair is a risk factor for esophageal hiatal hernia after laparoscopic

- total gastrectomy: A retrospective cohort study. *Surg Endosc* 2017;31(1):237–244. DOI: 10.1007/s00464-016-4962-2.
5. Santos Bdo N, de Oliveira MB, Peixoto RD. Hiatal hernia as a total gastrectomy complication. *Case Rep Oncol* 2016;9(1):100–105. DOI: 10.1159/000443633.
  6. Hertault H, Gandon A, Behal H, et al. Incidence and risk factors for diaphragmatic herniation following esophagectomy for cancer. *Ann Surg* 2021;274(5):758–765. DOI: 10.1097/SLA.0000000000005122.

## CASE REPORT

# Waltman Walter Syndrome—A Rare Postcholecystectomy Presentation: A Case Report

Lingam Sridhar<sup>1</sup>, Rohit Phadnis<sup>2</sup>, Faiz Hussain<sup>3</sup>, Subrahmanya Narayan Dora Kurumella<sup>4</sup>, Sarath Chandra Chappidi<sup>5</sup>, Sindhu Singareddy<sup>6</sup>

Received on: 24 November 2023; Accepted on: 20 December 2023; Published on: 14 February 2024

### ABSTRACT

Waltman Walter syndrome after laparoscopic cholecystectomy (LC) is rarely reported. However, it needs to be recognized promptly and managed as otherwise it can lead to further metabolic and infective complications. We present the case of a 42-year-old male who was admitted with ultrasound-proven cholelithiasis with no signs of cholecystitis and with a history of acute calculous cholecystitis. His total leukocytic count (TLC) and liver function tests (LFTs) were within normal limits. He underwent an uneventful LC with drain placement in Morrison's pouch. Postoperatively, he had complaints of pain in the abdomen and fever, clinically icterus was present, tachycardia and multiple fever spikes with persistent hypotension, and ultrasonography (USG) abdomen was suggestive of fluid collection of 214 cc noted tracking along the subdiaphragmatic region extending into the gallbladder fossa. Endoscopic retrograde cholangiopancreatography (ERCP) was done and was suggestive of a cystic stump leak for which biliary duct sphincterotomy + common bile duct (CBD) stenting was done. An USG-guided aspiration was done and bilious fluid was aspirated from subdiaphragmatic region. On postoperative day (POD) 10, the patients improved symptomatically, with a normal LFT, and the drain was removed; on follow-up after 4 weeks, he had no complaints, and stent removal was done. The main "take-home" message is that although rare, Waltman Walter syndrome is an unusual and rarely reported complication of post-LC particularly postdrain placement due to accumulation of bile in the subdiaphragmatic region. Timely response in diagnosing and bile drainage helps in the prevention of mortality and morbidity.

**Keywords:** Bile leak, Case report, Cystic duct stump leak, Endoscopic retrograde cholangiopancreatography, Laparoscopic cholecystectomy, Postlaparoscopic cholecystectomy complication, Subdiaphragmatic collection.

*World Journal of Laparoscopic Surgery* (2024): 10.5005/jp-journals-10033-1603

### INTRODUCTION

Laparoscopic cholecystectomy (LC) is the gold standard for gallstone disease. Biliary complications after LC are rare and can predispose to fatal sepsis. The incidence is between 0.3 and 3%.<sup>1</sup> Common causes of bile leak include cystic duct stump leak (CDSL), bile duct injury, duodenal injury, or bile leak from the duct of Luschka. Waltman Walter syndrome is a rare bile leak complication that requires prompt intervention due to the presence of accumulated bile in the subdiaphragmatic space.

### CASE DESCRIPTION

A 42-year-old male diagnosed with acute calculous cholecystitis underwent LC with drain placement in Morrison's pouch and intraoperative score Parkland classification – grade III (Fig. 1).<sup>2</sup>

On postoperative day 5, the patient had complaint of pain abdomen and fever, clinically icterus was present, tachycardia and multiple fever spikes with persistent hypotension; on examination, the patient was diagnosed with tenderness in the right hypochondrium, drain – 30 mL (Bilious), liver function test (LFT)-bilirubin – 3.23 (direct, 0.73; indirect, 2.5), total leukocytic count (TLC) – 15,000 and electrocardiography (ECG) was suggestive of no significant changes patient was clinically suspected to have biliary peritonitis. The patient was started on treatment accordingly.

An ultrasonography (USG) abdomen was suggestive of a fluid collection of 214 cc noted tracking along the subdiaphragmatic region extending into the gallbladder fossa (Fig. 2).

Endoscopic retrograde cholangiopancreatography (ERCP) was done and was suggestive of a cystic stump leak for which biliary

<sup>1–6</sup>Department of General Surgery, Apollo Institute of Medical Sciences and Research, Hyderabad, Telangana, India

**Corresponding Author:** Subrahmanya Narayan Dora Kurumella, Department of General Surgery, Apollo Institute of Medical Sciences and Research, Hyderabad, Telangana, India, Phone: +91 8978766781, e-mail: ksnarayanvirat@gmail.com

**How to cite this article:** Sridhar L, Phadnis R, Hussain F, et al. Waltman Walter Syndrome—A Rare Postcholecystectomy Presentation: A Case Report. *World J Lap Surg* 2024;17(1):58–60.

**Source of support:** Nil

**Conflict of interest:** None

**Patient consent statement:** The author(s) have obtained written informed consent from the patient for publication of the case report details and related images.

duct sphincterotomy + common bile duct (CBD) stenting was done (Fig. 3).

An USG-guided aspiration was done and bilious fluid was aspirated from subdiaphragmatic region and was sent for culture sensitivity which was suggestive of no growth.

On postoperative day (POD) 8, that is, 2 days after aspiration, patient condition improved clinically with zero drain output, and USG and liver function test (LFT) were repeated and were suggestive of normal findings.

The patient improved symptomatically and LFT and CBP were normal and was discharged on POD 10 with drain removal.

The patient was followed after 1 month. As clinically asymptomatic and normal LFT, stent removal was done.



## DISCUSSION

Laparoscopic cholecystectomy has revolutionized the treatment of cholecystitis and cholelithiasis. However, the incidence of rare but serious complications, such as bile duct injuries and vascular injury, is twice as high in LC than in open cholecystectomy.<sup>3</sup>

The incidence of CDSL is 0.12% following LC.<sup>4</sup>

Waltman Walter syndrome is characterized by a triad of lower chest pain, hypotension, and tachycardia which occurs postsurgery on the biliary tract. Diagnosis of myocardial ischemia is the differential diagnosis to this triad and on repeated electrocardiographs suggestive of ischemic changes. Waltman Walter syndrome is due to the subdiaphragmatic collection of

accumulated bile (Fig. 4) causing the liver to push downwards and medially. In the posterior aspect of the liver, the inferior vena cava gets compressed leading to decreased venous return, further leading to myocardial ischemia.<sup>5</sup>

Endoscopic stenting and sphincterotomy or percutaneous transhepatic biliary drainage are performed most commonly to deviate the bile past the defect, as CDSL heals spontaneously.<sup>6</sup>

Tzovaras et al.<sup>7</sup> reported that 80% of bile leaks are from CDSL post-LC. Furthermore, CDSL causes concluded from the study

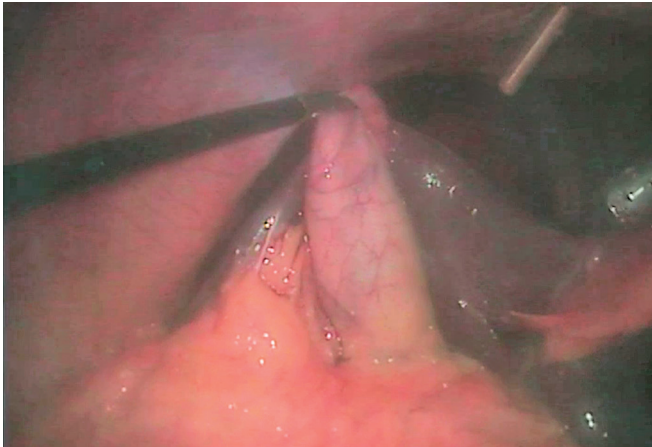


Fig. 1: Intraoperative image, Parkland classification – grade III

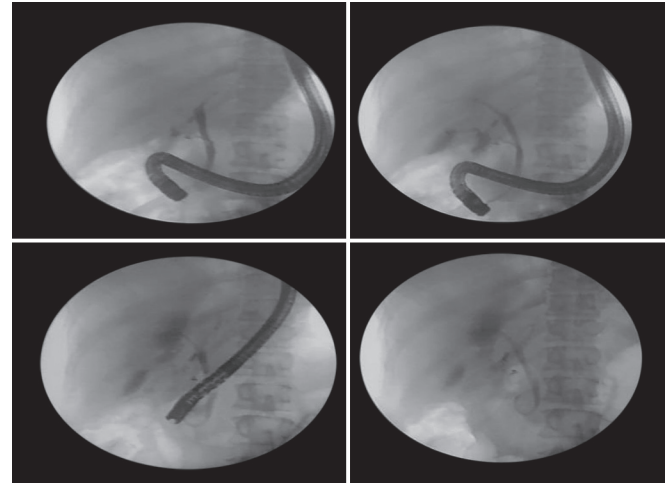


Fig. 3: Endoscopic retrograde cholangiopancreatography (ERCP) suggestive of cystic stump leak for which biliary duct sphincterotomy + CBD stenting done

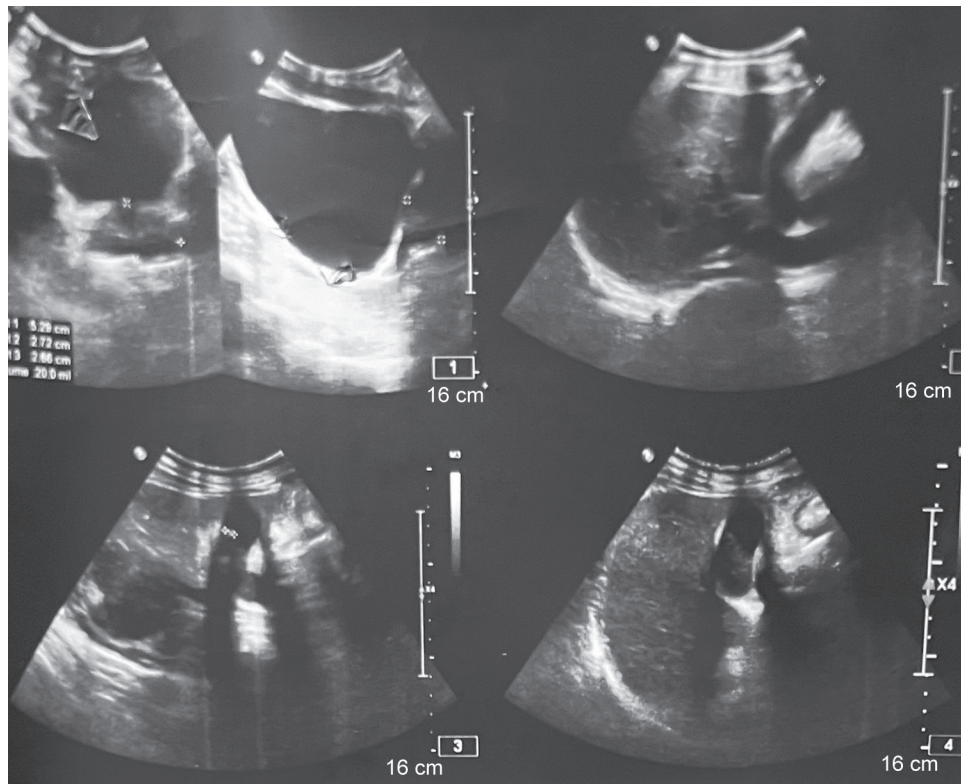
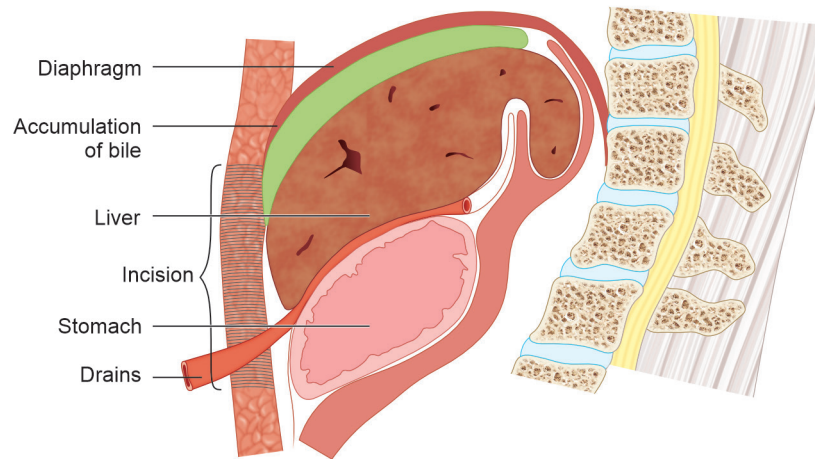


Fig. 2: Ultrasonography abdomen suggestive of fluid collection of 214 cc noted tracking along the subdiaphragmatic region extending into the gallbladder fossa



**Fig. 4:** Accumulation of bile in subdiaphragmatic space

**Table 1:** Possible causes and prevention of CDSL<sup>9</sup>

*Causes*

- Misplacement or displacement of cystic duct clips
- Injury to cystic duct proximal to the clip: Electrosurgery and ischemia
- Inadvertent injury to the cystic duct
- The presence of retained CBD stones if not addressed postoperatively
- Short and wide cystic duct
- Possible suctioning of clips during post-LC wash and suction

*Prevention*

- Caution in acute cholecystitis
- Caution in short and wide cystic duct
- Avoid cautery dissection at junction of cystic duct and bile duct

were due to displacement of clip, imperfect clip application, cystic duct stump necrosis, or injury related to electrosurgery. Also, CDSL is managed by endoscopic stent placement, endoscopic sphincterotomy, or combined.


Kaffes et al.<sup>8</sup> study reported that 83% of patients had a bile leak and CDSL was the cause for 60% of those. Ninety five percent of those patients underwent endoscopic stenting or sphincterotomy. The study concluded the removal of the stent 4 weeks postprocedure with no need for cholangiography poststent removal.

About 90% of patients are endoscopically managed and ERCP is the first line of management (Table 1). Percutaneous drainage is indicated in large biloma collection.<sup>9</sup>

## CONCLUSION

Waltman Walter syndrome is an unusual and rarely reported complication of post-LC particularly postdrain placement due to accumulation of bile in sub diaphragmatic region. Timely response in diagnosing and bile drainage helps in prevention of mortality and morbidity.

## ORCID

Subrahmanya Narayan Dora Kurumella  <https://orcid.org/0009-0002-3981-7766>

## REFERENCES

- Ahmad F, Saunders RN, Lloyd GM, et al. An algorithm for the management of bile leak following laparoscopic cholecystectomy. *Ann R Coll Surg Engl* 2007;89(1):51–56. DOI: 10.1308/003588407X160864.
- Madni TD, Nakonezny PA, Barrios E, et al. Prospective validation of the Parkland grading scale for cholecystitis. *Am J Surg* 2019;217(1):90–97. DOI: 10.1016/j.amjsurg.2018.08.005.
- Fletcher DR, Hobbs MS, Tan P, et al. Complications of cholecystectomy: Risks of the laparoscopic approach and protective effects of operative cholangiography: A population-based study. *Ann Surg* 1999;229(4):449–457. DOI: 10.1097/0000658-199904000-00001.
- Eisenstein S, Greenstein AJ, Kim U, et al. Cystic duct stump leaks: After the learning curve. *Arch Surg* 2008;143(12):1178–1183. DOI: 10.1001/archsurg.143.12.1178.
- The surgical management of conditions commonly associated with Jaundice by William James Irvine, B.Sc. (June 1958), pp. 39–49. Available from: <https://era.ed.ac.uk/handle/1842/34751>.
- Barkun AN, Rezieg M, Mehta SN, et al. Postcholecystectomy biliary leaks in the laparoscopic era: Risk factors, presentation, and management. *McGill Gallstone Treatment Group. Gastrointest Endosc* 1997;45(3):277–282. DOI: 10.1016/s0016-5107(97)70270-0.
- Tzovaras G, Peyser P, Kow L, et al. Minimally invasive management of bile leak after laparoscopic cholecystectomy. *HPB (Oxford)* 2001;3(2):165–168. DOI: 10.1080/136518201317077189.
- Kaffes AJ, Hourigan L, De Luca N, et al. Impact of endoscopic intervention in 100 patients with suspected postcholecystectomy bile leak. *Gastrointest Endosc* 2005;61:269–275. DOI: 10.1016/s0016-5107(04)02468-x.
- Shaikh IAA, Thomas H, Joga K, et al. Postcholecystectomy cystic duct stump leak: A preventable morbidity. *Journal of Digestive Diseases* 2009;10(3):207–212. DOI: 10.1111/j.1751-2980.2009.00387.x.

# Abnormally Located Benign Nerve Sheath Tumor—Retroperitoneal Schwannoma Managed Laparoscopically: A Case Report

B Ramesh<sup>1</sup>, Priyanka Sukumar<sup>2</sup>, Kiran R Konda<sup>3</sup>, Meghana Sreenivas<sup>4</sup>

Received on: 23 November 2023; Accepted on: 19 December 2023; Published on: 14 February 2024

## ABSTRACT

**Aim and background:** To demonstrate the clinical findings and management of a retroperitoneal Schwannoma, which presented as a gynecological mass. Nerve sheath tumors are benign tumors affecting the cranial and peripheral nerves. Schwannoma refers to tumors arising from the Schwann cells of neurons.

**Case description:** A 56-year-old female presented to us with vague lower abdominal pain since 3 months. It was initially diagnosed as a inclusion cyst. Intraoperatively diagnosed with retroperitoneal benign looking mass, which turned out to be a schwannoma. We present a case of left-sided retroperitoneal schwannoma which masqueraded as a gynecological mass and operated by laparoscopy.

**Conclusion:** Schwannomas are benign, encapsulated, slow-growing nerve sheath tumors. Rarely seen in the pelvis and retroperitoneum. Laparoscopy aids in better visualization with more accurate surgical removal of these masses and can be considered the treatment of choice for these tumors.

**Clinical significance:** Often asymptomatic and may go unnoticed, but when presenting with symptoms or when discovered incidentally on scans for other reasons, they are mistaken for gynecological or urological masses and are more often presented to gynecologist/urologist.

**Keywords:** Case report, Laparoscopy, Nerve sheath tumors, Retroperitoneal, Schwannoma.

*World Journal of Laparoscopic Surgery* (2024): 10.5005/jp-journals-10033-1608

## INTRODUCTION

Nerve sheath tumors are benign tumor affecting the cranial and peripheral nerves, schwannoma refers to tumors arising from the Schwann cells of neurons. Presence of these tumors are often seen in association with Von Recklinghausen's disease/Neurofibromatosis. Their occurrence in abdominal/retroperitoneal nerve is seldom seen, with only a few case reports worldwide.<sup>1</sup> Mostly asymptomatic, but when presenting with pain or bowel/bladder pressure symptoms, they are often misdiagnosed to be of gynecological or urological origin.<sup>2,3</sup> Due to a benign nature with rare local infiltration, a simple excision by laparoscopy suffices for complete management of these cases.<sup>4,5</sup>

## CASE DESCRIPTION

A woman aged 56 years, came to us complaining of vague lower abdominal pain since 3 months, it was not associated with any other symptoms. She had history of loss of appetite since few days, not associated with any weight loss or aggravated pain. Patient was on regular treatment for diabetes mellitus and asthma. No history of any familial cancers or tumors. She had a history of multiple abdominal surgeries in the past—appendectomy, abdominal hysterectomy with bilateral salpingo-oophorectomy, and cholecystectomy. The patient had also undergone diagnostic laparoscopy with adhesiolysis and stenting of ureters, 2 years prior for abdominal pain not relieving with medication where, no growth or mass was detected intra-abdominally except for omental adhesions. On examination, mild-left lower abdominal tenderness was present with distension. Per speculum examination and per vaginum were unremarkable.

<sup>1</sup>Chief Gynaecological Laparoscopic Surgeon, Altius Hospitals, Bengaluru, Karnataka, India

<sup>2-4</sup>Department of Minimal Invasive Surgery Gynaecology, Altius Hospitals, Bengaluru, Karnataka, India

**Corresponding Author:** Kiran R Konda, Department of Minimal Invasive Surgery Gynaecology, Altius Hospitals, Bengaluru, Karnataka, India, Phone: +91 9480507043, e-mail: kiran.rkonda@gmail.com

**How to cite this article:** Ramesh B, Sukumar P, Konda KR, *et al.* Abnormally Located Benign Nerve Sheath Tumor—Retroperitoneal Schwannoma Managed Laparoscopically: A Case Report. *World J Lap Surg* 2024;17(1):61–64.

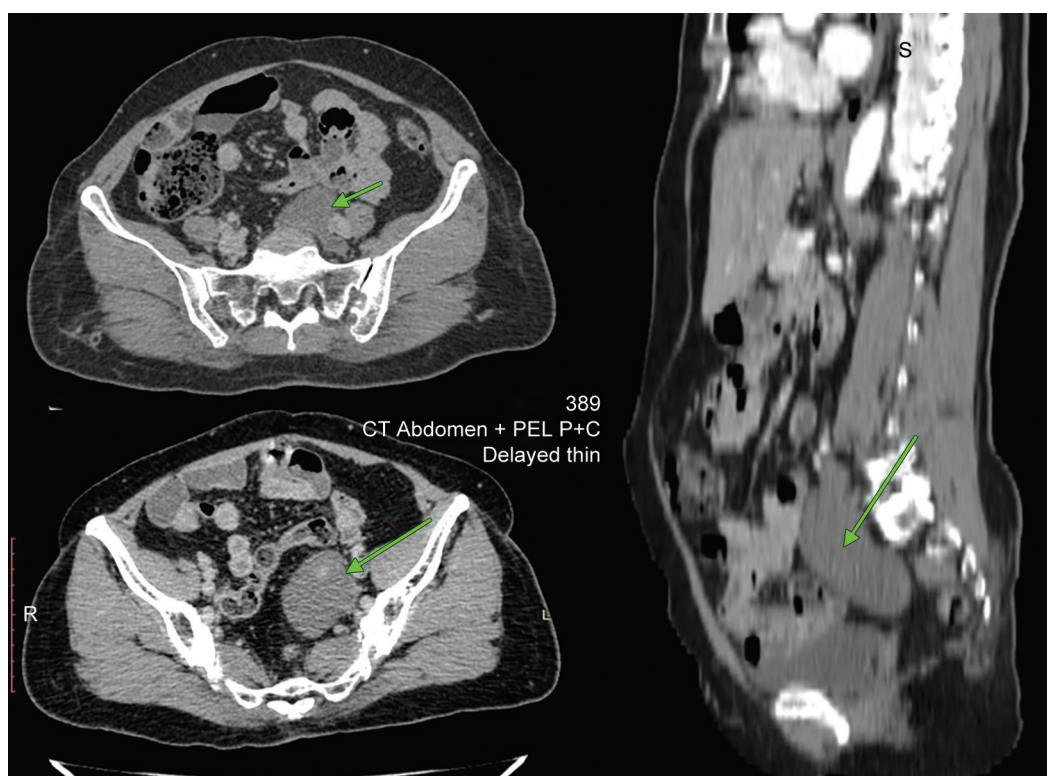
**Source of support:** Nil

**Conflict of interest:** None

**Patient consent statement:** The author(s) have obtained written informed consent from the patient for publication of the case report details and related images.

Ultrasonography revealed a pelvic cystic mass. She was then advised a contrast-enhanced computed tomography which showed a left adnexal 10 × 4 cm sized well-defined homogeneously hypoechoic cystic space occupying lesion which was suggestive of inflammatory/infective etiology (Fig. 1). In view of a cystic mass in the pelvis, all the relevant ovarian tumor markers were checked, which included cancer antigen-125 (CA-125), carcinoembryonic antigen (CEA), cancer antigen (CA 19-9), lactate dehydrogenase (LDH), inhibin, beta-human chorionic gonadotropin (β-HCG) and were found to be normal. With a history of bilateral oophorectomy and a differential





**Fig. 1:** Axial and sagittal sections of the contrast-enhanced computed tomography showing the mass in the left side of pelvis

diagnosis of peritoneal inclusion cyst, patient was counselled for laparoscopic exploration and excision of mass.

Intraoperatively, adhesions involved omentum to anterior abdominal wall near cholecystectomy site, to left lateral pelvic wall, and to uterosacrals. After adhesiolysis, a left retroperitoneal mass was identified after dissecting omental adhesions and left ureterolysis. It was present in front of the sacral promontory, with a smooth surface and a cystic consistency, and no signs of local invasion. All feeding vessels were cauterized and cut. The mass was excised with special care to avoid essential pelvic nerves and vessels. Uterus and adnexa were absent. The specimen was retrieved in bag to avoid spillage into upper abdomen and port site (Fig. 2). Cut section of the mass was homogenous grayish white with 3 mm thickness of the cyst wall.

Histopathology revealed fibrocollagenous tissue and fibroadipose tissue with tumor composed of cells diffuse sheets and fascicles of bland appearing spindle cells having elongated nucleus with moderate amount of eosinophilic cytoplasm. Stroma showed a myxoid and cystic change. The spindle cells were seen to be entrapping the lobules of mature adipose tissue at periphery. Few ganglion-like cells were seen. Mitotic activity was 0–2 per high power field and margins were free of tumor. This low-grade spindle cell neoplasm was reactive with S100 and SOX10 (SRY-Box Transcription Factor 10) and patchy reactivity with CD34 (Cluster of Differentiation 34). About 5% of the tumor cells had Ki67 (Antigen Kiel 67) reactivity and negative for epithelial membrane antigen (EMA) and smooth muscle actin (SMA) on immunohistochemistry (IHC), thus diagnosing nerve sheath tumor (Fig. 3).

Postoperatively the patient recovery was uneventful and was discharged at 48 hours. Patient had complete relief from pain on 1-month and 6-month follow-up with no signs of recurrence of mass on ultrasonography.

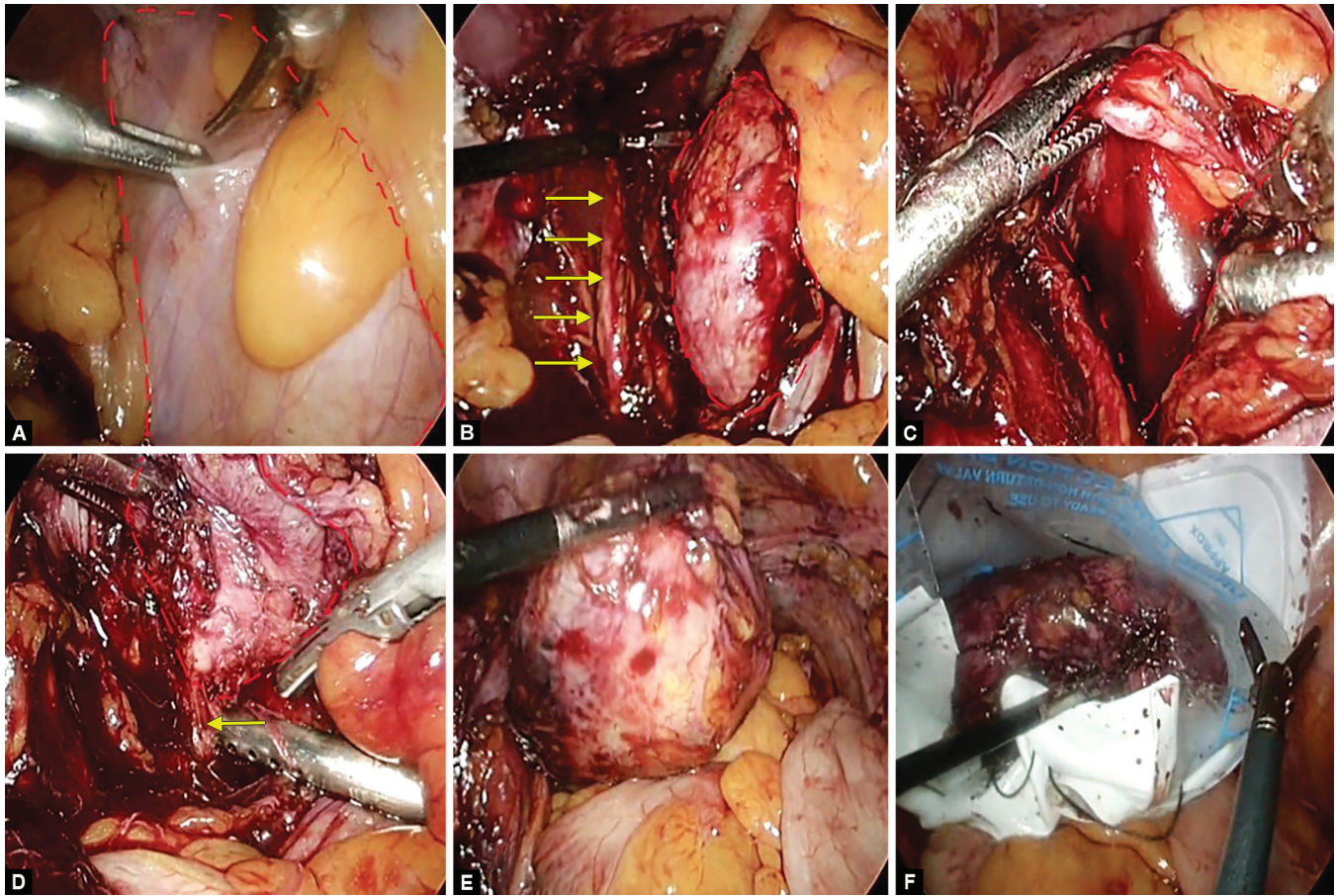
## DISCUSSION

Schwannomas, neurofibroma, solitary circumscribed neuroma, and perineuriomas are soft tissue tumors of the nerve sheath.<sup>2</sup> Benign peripheral nerve sheath tumors can occur sporadically or as manifestations of genetic syndromes, such as neurofibromatosis types 1/Von Recklinghausen's disease and neurofibromatosis 2. Schwannomas arise from the Schwann cells covering the neurons, most seen in peripheral and cranial nerve trunks (except cranial nerve 1 and 2) and rarely seen in retroperitoneal nerves (0.3–3.2%). They are mostly solitary tumors, well circumscribed with no local tissue invasion and multiple lesions only seen in association with neurofibromatosis 1.<sup>2,4</sup>

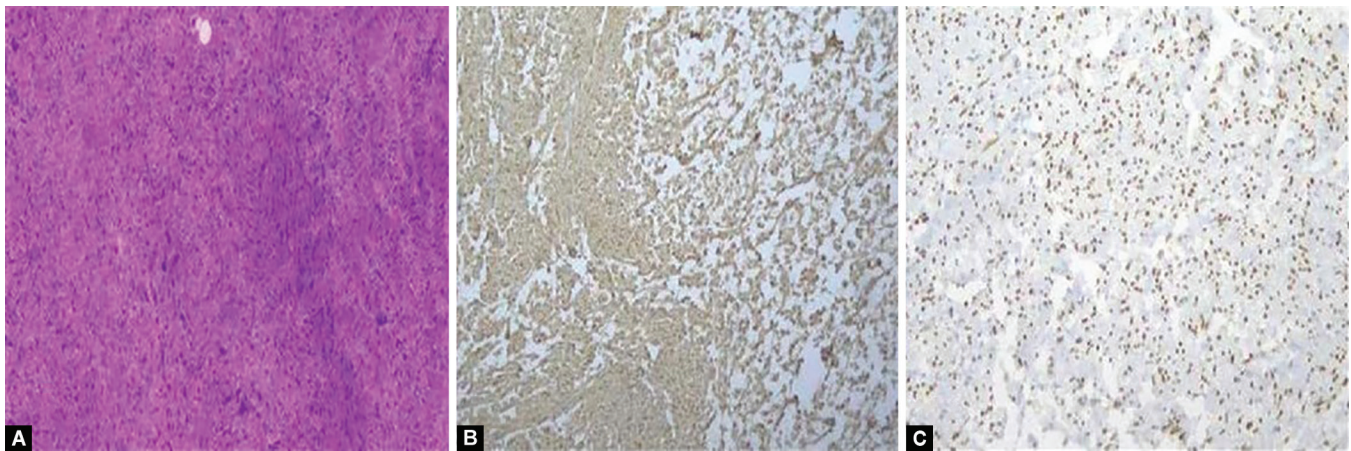Due to a slow growing and asymptomatic nature, patients rarely present for this condition, they are often discovered incidentally during investigation for other problems.<sup>2</sup> As seen in our patient, when symptomatic, they may present with chronic pelvic pain or pressure symptoms over bowel/bladder.<sup>3,6</sup> Local recurrence is prevented by complete resection and rarely transform to malignant mass.<sup>7</sup> They have been reported to be arising from pelvic nerves and retroperitoneal tissue with the involvement of broad ligaments and pressure symptoms.<sup>1</sup>

Ultrasonography as the first-line investigation is best for detecting cystic lesions. Therefore, computed tomography and magnetic resonance Imaging may be useful for distinguishing these masses. Although, the features of most retroperitoneal tumors are still non-specific.<sup>8</sup> As was seen in our case, a cystic mass was reported in the left adnexa on contrast-enhanced computed tomography, which intraoperatively turned out to be a retroperitoneal mass. Imaging-guided core needle biopsy by radiologists provides correct diagnosis.<sup>2</sup> However, Daneshmand S et al. reported that preoperative diagnosis of Schwannomas with





**Figs 2A to F:** Laparoscopic excision of the mass. (A) Initial visualization of a retroperitoneal swelling; (B) Close relation of ureter (Yellow arrows) on peritoneal dissection; (C) Excision of mass after adequate ureterolysis; (D) Devascularization of the mass with ultrasonic and bipolar energy (vascular connections-yellow arrow); (E) Mass visualized after complete excision; (F) Mass retrieved in bag through left lower port



**Figs 3A to C:** (A) Fibrocollagenous tissue and fibroadipose tissue with a tumor composed of cells diffuse sheets and fascicles of bland appearing spindle cells having elongated nucleus with moderate amount of eosinophilic cytoplasm; (B) S100 positivity on IHC; (C) SOX10 positivity on IHC

computed tomography-guided fine needle aspiration biopsy fails to provide accurate diagnosis.<sup>4</sup>

Histologically, encapsulated mass displays alternating areas of dense cellularity and areas of myxoid matrix (Antoni-A and Antoni-B regions). Antoni-A regions have dense aggregation

of spindle-shaped cells arranged in parallel configurations, palisades, or whorls. Antoni-B regions show hypocellularity with predominantly loose myxoid matrix. Immunohistochemistry is positive for S-100, Vimentin, and neuron-specific enolase. Smooth muscle actin and CD117 are negative. Ancient Schwannoma,

a variant characterized by degenerative features, such as cystic necrosis, stromal edema, fibrosis, perivascular hyalinization, calcification, and degenerative nuclei with pleomorphism, lobulation, and hyperchromasia.<sup>9</sup> S100 and SOX10 IHC markers which are more specific markers for Schwannomas and CD34 positivity usually seen in Antoni-A areas. Ki67 index is a marker for high replication rate and malignancy. Epithelial membrane antigen normally expressed in perineurial cells; therefore, it is positive stained in perineuriomas and malignant peripheral nerve sheath tumor (MPNST) with perineurial differentiation, but negative in schwannomas.<sup>10</sup> The IHC markers in our case were conclusive of a benign schwannoma.

Complete resection is the best treatment for schwannomas.<sup>11</sup> Research indicates an increased risk of neurologic deficit after complete excision with adjacent tissue. However, malignant transformation and local recurrence are very rare after complete resection.<sup>5</sup> Laparoscopy is safe and efficient option for approaching these schwannomas and it offers the advantage of better visualization of structures with magnification, especially in narrow anatomic spaces.<sup>12</sup> As seen in the present case report, laparoscopy allowed for better visualization of abdomen, with detailed pelvic anatomy and aided in fine dissection of the left ureter which was in close relation to the mass.

## CONCLUSION

Schwannomas are benign, encapsulated, slow-growing nerve sheath tumors. They are rarely seen in the pelvis and retroperitoneum. They are often asymptomatic and may go unnoticed, but when presenting with symptoms or when discovered incidentally on scans for other reasons, they are mistaken for gynecological or urological masses and are more often presented to gynecologist/urologist. Malignancy is very rare and often surgical excision of mass suffice and prevent further growth or recurrence. Laparoscopy aids in better visualization with more accurate surgical removal of these masses and can be considered the treatment of choice for these tumors.

## REFERENCES

1. Machairiotis N, Zarogoulidis P, Stylianaki A, et al. Pelvic schwannoma in the right parametrium. *Int J Gen Med* 2013;6:123. DOI: 10.2147/IJGM.S41224.
2. Strauss DC, Qureshi YA, Hayes AJ, et al. Management of benign retroperitoneal schwannomas: A single-center experience. *Am J Surg* 2011;202:194–198. DOI: 10.1016/j.amjsurg.2010.06.036.
3. Sinha R, Sundaram M, Hegde A, et al. Pelvic schwannoma masquerading as broad ligament myoma. *J Minim Invasive Gynecol* 2008;15:217–219. DOI: 10.1016/J.JMIG.2007.09.009.
4. Daneshmand S, Youssefzadeh D, Chamie K, et al. Benign retroperitoneal schwannoma: A case series and review of the literature. *Urology* 2003;62:993–997. DOI: 10.1016/s0090-4295(03)00792-1.
5. Deng C, Wang P, Liu Y, et al. Laparoscopic resection of pelvic schwannomas: A 9-year experience at a single center. *World Neurosurg* 2023;17:100150. DOI: 10.1016/j.wnsx.2022.100150.
6. Dawley B. A retroperitoneal femoral nerve schwannoma as a cause of chronic pelvic pain. *J Minim Invasive Gynecol* 2008;15:491–493. DOI: 10.1016/J.JMIG.2008.02.007.
7. McMenamin ME, Fletcher CDM. Expanding the spectrum of malignant change in schwannomas: Epithelioid malignant change, epithelioid malignant peripheral nerve sheath tumor, and epithelioid angiosarcoma: A study of 17 cases. *Am J Surg Pathol* 2001;25:13–25. DOI: 10.1097/00000478-200101000-00002.
8. Takahashi H, Hara M, Tsuboi K, et al. Laparoscopically resected obturator nerve schwannoma: A case report. *Asian J Endosc Surg* 2016;9:307–310. DOI: 10.1111/ases.12291.
9. Choudry HA, Nikfarjam M, Liang JJ, et al. Diagnosis and management of retroperitoneal ancient schwannomas. *World J Surg Oncol* 2009;7:12. DOI: 10.1186/1477-7819-7-12.
10. Guedes-Corrêa JF, Cardoso RSV. Immunohistochemical markers for schwannomas, neurofibromas and malignant peripheral nerve sheath tumors—what can the recent literature tell us? *Arquivos Brasileiros de Neurocirurgia: Brazilian Neurosurgery* 2018;37:105–112.
11. Goh BKP, Tan YM, Chung YFA, et al. Retroperitoneal schwannoma. *Am J Surg* 2006;192:14–18. DOI: 10.1016/J.AMJSURG.2005.12.010.
12. Konstantinidis K, Theodoropoulos GE, Sambalis G, et al. Laparoscopic resection of presacral schwannomas. *Surg Laparosc Endosc Percutan Tech* 2005;15:302–304. DOI: 10.1097/01.sle.0000183252.96808.78.