



# World Journal of Laparoscopic Surgery

*An Official Publication of the World Association of Laparoscopic Surgeons, UK*

*Editors-in-Chief*

**RK Mishra (India)**

**Jiri PJ Fronek (UK)**



**WJOLS**

Also available online at  
[www.jaypeejournals.com](http://www.jaypeejournals.com)  
[www.wjols.com](http://www.wjols.com)

Access Online Resources



For more details, visit  
[www.wjols.com](http://www.wjols.com)

*Bibliographic Listings:*

ProQuest, Scopus, Journals Factor,  
EBSCO, Genamics JournalSeek, Emcare, HINARI, Embase,  
J Gate, Google Scholar, Ulrich, CiteFactor, SIS,  
OAJI, MIAR, SIF, COSMOS, ESJI, SJIF, SJR, IJIF, ICI



**JAYPEE** Jaypee Journals

I am glad to present in front of our learned members the current Volume of World Journal of Laparoscopic Surgery.

Laparoscopic cholecystectomy is now the most frequently performed minimal access surgery by the general surgeon, but it has introduced a new spectrum of complications. Major biliary and vascular complications are life-threatening, while minor complications cause patient discomfort and prolongation of the hospital stay.

It is important to recognize intraoperative complications during the laparoscopic cholecystectomy surgery so they are taken care of in a timely manner during the surgical intervention. In this issue, we have an excellent article on cholecystectomy. One is regarding Nonbiliary Complications of Laparoscopic Cholecystectomy, and another is reporting Frequency, Complications, and Predictive Factors for Performing Subtotal Laparoscopic Cholecystectomy.

Subtotal laparoscopic cholecystectomy has potential advantages of shorter hospital stay, no wound infections, no biliary injury, and avoids conversion to open cholecystectomy. It is a useful and safe strategy in patients with an obscure Calot's anatomy during laparoscopic cholecystectomy. Another good case report in this issue is regarding the Danger of Laparoscopic Umbilical Port in Portal Hypertensive Cirrhotic Patient.

For our Gynaecologist readers, we have a helpful case report on Secondary Abdominal Pregnancy. Secondary abdominal pregnancy is a condition where the embryo or fetus continues to grow in the abdominal cavity after its expulsion from the fallopian tube or another seat of its initial development.

The safety and effectiveness of minimally invasive esophagectomy in comparison with the open esophagectomy, remain uncertain in esophageal cancer treatment. Total laparoscopic esophagectomy is a better choice for oesophageal cancer because patients undergoing this technique get benefit from reduced blood loss, fewer respiratory complications, and also improved overall survival conditions. To describe these advantages in this issue, we have an original article on this issue with an experience of 93 patients on Totally Laparoscopic vs. Open Transhiatal Esophagectomy.

I hope you will like this issue, and as usual, your comments and feedback are appreciated.



**RK Mishra**

Editor-in-Chief

Chairman

World Laparoscopy Hospital  
Gurugram, Haryana, India

# Nonbiliary Complications of Laparoscopic Cholecystectomy: A Single-center Experience

Mohit Sharma<sup>1</sup>, Rachhpal Singh<sup>2</sup>

## ABSTRACT

**Aim:** Bile duct injury is an important complication of laparoscopic cholecystectomy. Nonbiliary injuries after laparoscopic cholecystectomy can be fatal and source of considerable morbidity. In this study we intend to highlight the importance of nonbiliary complications sustained during laparoscopic cholecystectomy and their outcome.

**Materials and methods:** The study is analysis of patients managed in our unit with post-laparoscopic cholecystectomy nonbiliary complications from June 2010 to December 2018. Inclusion criteria—nonbiliary complications. Exclusion criteria—cases of bile duct injury, cases of surgical site infection, trocar-site hernia.

**Results:** A total of nine patients with nonbiliary complications were managed. Mean age of the patients was 51.1 years (range 38–65). There were five males and four females. Nonbiliary injuries were categorized into access-related and procedure-related complications. Three cases (two colonics, one inferior vena cava) were access related. Six cases (five duodenal, one ileal) were procedure related.

**Conclusion:** Nonbiliary injuries are of significant severity. Adequate attention in creating pneumoperitoneum and meticulous dissection helps in preventing complication. Timely detection and early therapeutic intervention can help reduce morbidity and mortality.

**Keywords:** Complications, Laparoscopic cholecystectomy, Nonbiliary injuries.

*World Journal of Laparoscopic Surgery* (2019): 10.5005/jp-journals-10033-1367

## INTRODUCTION

Laparoscopic cholecystectomy is the standard of care for symptomatic cholelithiasis. The bile duct injury during laparoscopic cholecystectomy is a well-known complication. The nonbiliary injuries do occur with equally significant severity but tend to be underreported in literature.<sup>1</sup> Nonbiliary complications can be procedure related or access related. This study describes our experience in managing nonbiliary complications after laparoscopic cholecystectomy. Various aspects like clinical presentation, severity, management and outcome has been discussed. Our study emphasizes the need to prevent such complications, which are cause of significant morbidity and mortality.

## MATERIALS AND METHODS

This study is retrospective analysis of prospectively collected data of patients with post-laparoscopic cholecystectomy complications. The study included patients sustaining injury while operated in our hospital and also those who were operated in other hospitals and were referred to us once the injury was detected. Inclusion criteria—nonbiliary complications. Exclusion criteria—cases of bile duct injury, cases of surgical site infection, trocar site hernia. From June 2010 to December 2018, a total of 60 patients with post-cholecystectomy complications were managed in our unit. Of these 60 patients, 51 were of biliary tract injury and 9 were nonbiliary injuries. Nonbiliary injuries were further categorized into access-related complications, procedure-related complications. Complete record of these nine patients were reviewed. Relevant points like difficulties encountered during surgery, conversion to laparotomy (done or not), clinical presentation, timing of referral, treatment and outcome were noted.

## RESULTS

Mean age of the patients was 51.1 (38–65 years). There were five males and four females. Three cases of nonbiliary injuries occurred

<sup>1,2</sup>Department of Surgery, Sri Guru Ram Das Institute of Medical Sciences and Research, Amritsar, Punjab, India

**Corresponding Author:** Mohit Sharma, Department of Surgery, Sri Guru Ram Das Institute of Medical Sciences and Research, Amritsar, Punjab, India, Phone: +91 9814651788, e-mail: drmohit.gis@gmail.com

**How to cite this article:** Sharma M, Singh R. Nonbiliary Complications of Laparoscopic Cholecystectomy: A Single-center Experience. *World J Lap Surg* 2019;12(2):49–52.

**Source of support:** Nil

**Conflict of interest:** None

in our own unit (one colonic, one duodenal, one ileum), rest six cases were referred from other hospitals.

The nonbiliary complications in decreasing order of frequency were duodenal (five cases), colonic (two cases), ileal (one case), inferior vena cava (one case). Three cases (two colonics, one inferior vena cava) were secondary to trocar insertion. Six cases (five duodenal, one ileal) occurred during dissection.

## Access-related Injuries

### Colon Injury

First case was 50 years old male. He sustained injury to transverse colon during insertion of first trocar in a city nursing home. Our team was called upon as rescue surgeons. Immediate laparotomy and repair of colon injury was done. He had uneventful outcome. Second case was 44 years old female. She had h/o abdominal sepsis following open hysterectomy in the past. Transverse colon got injured during insertion of first trocar. Immediate laparotomy, repair of colonic laceration was done. She had uneventful outcome (Table 1).

**Table 1:** Trocar-related injuries

No.	Site of injury	Age and sex	Presumed mechanism of injury	Presentation	Interval surgery	Type of surgery	Outcome
1	Transverse colon	50 male	Direct injury-trocar	Intraoperative	Immediate	Laparotomy, Repair of perforation	Survived
2	Transverse colon	44 female	Direct injury-trocar	Intraoperative	Immediate	Laparotomy, Repair of perforation	Survived
3	Inferior vena cava	38 male	Direct injury-trocar	Intraoperative	Immediate by primary surgeon reexploration after 24 hours	Laparotomy + hemostatic suturing	Death POD10

**Table 2:** Dissection-related injuries

No.	Site of injury	Age and sex	Presumed mechanism of injury	Presentation	Interval surgery	Type of surgery	Outcome
1	Duodenum	45 male	Dissection and adhesiolysis	Intraoperative	Immediate	Duodenorrhaphy with omental patch	Survived
2	Duodenum	48 male	Electrocautery	Septicemia peritonitis, duodenal fistula	10 days	Tube duodenostomy feeding jejunostomy	Death POD10
3	Duodenum	58 female	Electrocautery	Septic shock, peritonitis, biliary fistula	3 days	Duodenorrhaphy with omental patch	Death POD4
4	Duodenum	65 male	Electrocautery	Septicemia, peritonitis	7 days	Duodenorrhaphy with omental patch	Death POD4
5	Duodenum	57 female	Dissection and adhesiolysis	Septic shock, biliary fistula	4 days	Duodenorrhaphy with omental patch	Death POD1
6	Ileum	55 female	Electrocautery adhesiolysis	Peritonitis	5 days	Ileal resection and exteriorization	Death POD10

### *Inferior Vena Cava Injury*

A 38 years old male underwent laparoscopic cholecystectomy in a peripheral rural hospital. He sustained injury to inferior vena cava during primary insertion of trocar. Immediate laparotomy and repair of injury was done by primary surgeon, however he continued to have low blood pressure despite on table repair and multiple transfusion and was referred to our hospital after 14 hours for further management. At the time of admission, he was hemodynamically unstable. After further resuscitation with blood and fresh frozen plasma he was reexplored. Preoperatively active bleeding from sutured IVC was detected, hemostatic suturing was done. However, patient continued to be in shock, disseminated intravascular coagulopathy and died on postoperative day 10 (Table 1).

### **Dissection-related Injuries**

#### *Duodenal injury*

A total of five cases were of duodenal injury. In two cases duodenal injury was recognized intraoperatively by the primary surgeon. Of these two cases, one case was dealt with by primary surgeon with laparoscopic suturing. She developed duodenal fistula, septicemia and multiorgan failure and was referred to us with septicemia shock on day 3. She could not survive despite resuscitation and exploratory laparotomy. In second case, our team was called for intraoperative consult. In this patient duodenal repair was done after converting to laparotomy. Patient had uneventful outcome. In another three patients, it was difficult laparoscopic cholecystectomy due to adhesions in Calot's triangle, duodenal injury was not recognized intraoperatively. All of these three patients underwent delayed repair of duodenal perforation with duodenorrhaphy and omentopexy. However, all patients succumbed to persistent septicemia and multiorgan failure (Table 1).

### *Ileal Injury*

A 55-year-old female was taken up for laparoscopic cholecystectomy in our unit. She had past h/o laparotomy, preoperatively there were small bowel adhesions to parietal wall. Laparoscopic adhesiolysis of small bowel was done to access gallbladder, followed by laparoscopic cholecystectomy. On postoperative day 5, she developed diffuse abdominal pain, voluntary guarding and rigidity. Ultrasound abdomen revealed free fluid. Immediate exploration showed perforation of bowel from site of adhesiolysis, probably thermal injury. Resection and exteriorization of bowel was done. However patient developed multiorgan dysfunction and died on postoperative day 10 (Table 2).

## **DISCUSSION**

Laparoscopic cholecystectomy is the standard operation for gallstone disease. In comparison to open cholecystectomy laparoscopic approach has nearly two fold higher risk of major biliary, vascular and bowel complications.<sup>2</sup> The approximate incidence of major bile duct injury following laparoscopic cholecystectomy is 0.4–0.86%.<sup>3,4</sup> The incidence of major retroperitoneal vascular injury such as abdominal aorta, inferior vena cava, iliac vessels is reported to be 0.05%.<sup>5</sup> The incidence of bowel injury has been reported to be between 0.06% and 0.32%.<sup>6,7</sup>

In our study we have categorized nonbiliary injuries in two categories: (1) access-related injury, (2) dissection-related injury. The insertion of first trocar in laparoscopic cholecystectomy is dangerous step with potential of bowel and vascular complication. Secondary ports being placed under vision have lower risk of complications. The faulty technique, surgeon's inexperience, forceful thrust, obesity, extreme thinness, previous abdominal surgery are the predisposing factors for access-related complications.<sup>8,9</sup> In our case



series we had managed three cases of access-related complications. Two colonic and one inferior vena cava. Both the colonic injuries were dealt immediately by doing laparotomy and repair of colonic laceration. There was uneventful outcome in both the cases. Inferior vena cava injury patient was a young male. He sustained injury to inferior vena cava during primary port placement in a peripheral hospital. Despite immediate laparotomy by primary surgical team and re exploration at our center, patient succumbed secondary to disseminated intravascular coagulopathy. Roviario et al.<sup>10</sup> in a review of literature on major vascular injuries during laparoscopic surgery has quoted high mortality rate associated with this complication. Chandler et al.<sup>11</sup> has shown that delayed recognition of vascular injury is significantly associated with fatal outcome. Despite low incidence of vascular injuries, mortality has been reported in range of 8–17%.<sup>12</sup>

There are two methods of creating pneumoperitoneum for laparoscopy surgery—closed method technique, open access technique. Gaining access to peritoneal cavity is the most important step in laparoscopy, serious complications of laparoscopy surgery are related to needle or trocar insertion.<sup>13</sup> Though rare, potentially fatal complications reported in literature in closed method technique is—vascular 0.003–1.33%, visceral injuries 0.04–4%.<sup>14,15</sup> Open access technique (Hasson) is considered to be relatively safer than closed technique.<sup>16</sup> Optical trocar method has also shown reduction in incidence of trocar-related complications.<sup>17</sup> Adequate manual lifting during insertion of trocar, avoiding undue thrust during insertion, insertion of secondary ports under vision, Trendelenburg position, avoiding scar of previous laparotomy are some of the methods to minimize access-related complications.

We managed six cases of dissection-related injury. Of the six cases, five were duodenal, one ileal.

The approximate incidence of duodenal injury has been reported to be 0.04% (0.01–0.04%) in the literature.<sup>18</sup> Majority of duodenal injuries are as a result of dissection of gallbladder infundibulum from adherent duodenum. The sharp edge of suction device used for traction and thermal injury caused by electrocautery are some of the other important causes of duodenal injury.<sup>6,19,20</sup> In our series of five duodenal injury cases, three cases had dense adhesions in Calot's triangle with complete obliteration of Calot's in one case. In two cases infundibulum was adherent to duodenum. In a patient with ileal perforation, probable cause was electrocautery induced thermal injury. This patient had history of laparotomy, adhesiolysis of ileal loops from parietal wall was done using electrocautery. Our series of dissection-related injuries was associated with high mortality. Only one case of duodenal injury survived, in this case duodenal injury was recognized intraoperatively and was dealt with immediate laparotomy and repair of injury. In our series of dissection-related injuries mean duration of presentation was 4.83 days (range 0–10 days). Delayed recognition is significantly associated with mortality. Similar experience has been reported in other case series.<sup>21,22</sup>

Dissection-related injuries are more common in patients with history of repeated attacks of acute cholecystitis. Careful dissection with patience helps in avoiding injury. Early conversion to laparotomy should be considered rather than continuing in obscure field. Use of cautery should be done judiciously in Calot's triangle to minimize risk of thermal injuries. In case of uneventful recovery high index of suspicion should be maintained. Timely detection and early intervention are key to reduce morbidity and mortality.

## CONCLUSION

Nonbiliary injuries are not uncommon after laparoscopic cholecystectomy and are of significant severity. Adherence to basic principles of laparoscopic surgery with proper attention in creating pneumoperitoneum and meticulous dissection reduces the chances of complication. Early detection followed by therapeutic intervention can help to reduce morbidity and mortality.

## REFERENCES

1. Rajdeep S, Robin SK, Rajeev SK, et al. Non-biliary mishaps during laparoscopic cholecystectomy. *Indian J Gastroenterol* 2004;23(2): 47–49.
2. Fletcher DR, Hobb MS, Tan P, et al. Complications of cholecystectomy: risks of the laparoscopic approach and protective effects of operative cholangiography: a population-based study. *Ann Surg* 1999;229(4):449–457. DOI: 10.1097/0000658-199904000-00001.
3. Calvete J, Sabater L, Camps B, et al. Bile duct injury during laparoscopic cholecystectomy: myth or reality of the learning curve? *Surg Endosc* 2000;14(7):609–611. DOI: 10.1007/s004640000103.
4. Waage A, Nilsson M. Iatrogenic bile duct injury: a population-based study of 152 776 cholecystectomies in the Swedish Inpatient Registry. *Arch Surg* 2006;141(12):1207–1213. DOI: 10.1001/archsurg.141.12.1207.
5. Deziel DJ. Complications of laparoscopic cholecystectomy: a national survey of 4,292 hospitals and an analysis of 77,604 cases. *Am J Surg* 1993;165(1):9–14. DOI: 10.1016/S0002-9610(05)80397-6.
6. Huang X, Feng Y, Huang Z. Complications of laparoscopic cholecystectomy in China: an analysis of 39,238 cases. *Chin Med J* 1997;110(9):704–706.
7. Wherry DC, Marohn MR, Malanoski MP, et al. An external audit of laparoscopic cholecystectomy in the steady state performed in medical treatment facilities of the department of defense. *Ann Surg* 1996;224(2):145–154. DOI: 10.1097/0000658-199608000-00006.
8. Mases A, Montes A, Ramos R, et al. Injury to the abdominal aorta during laparoscopic cholecystectomy: an unusual presentation. *Anesth Analg* 2000;91(3):561–562. DOI: 10.1213/00000539-200009000-00011.
9. Voitk A, Rizoli S. Blunt hasson trocar injury: long intra-abdominal trocar and lean patient—a dangerous combination. *J Laparoendosc Adv Surg Tech A* 2000;11(4):259–262. DOI: 10.1089/109264201750539817.
10. Roviario GC, Varoli F, Saguatti L, et al. Major vascular injuries in laparoscopic surgery. *Surg Endosc* 2002;12(8):1192–1196. DOI: 10.1007/s00464-001-8238-z.
11. Chandler JG, Corson SL, Way LW. Three spectra of laparoscopic entry access injuries. *J Am Coll Surg* 2001;192(4):478–490. DOI: 10.1016/S1072-7515(01)00820-1.
12. Olsen DO. Laparoscopic cholecystectomy. *Am J Surg* 1991;16(3): 339–344. DOI: 10.1016/0002-9610(91)90592-2.
13. Hashizume M, Sugimachi K. Needle and trocar injury during laparoscopic surgery in Japan. *Surg Endosc* 1997;11(12):1198–1201. DOI: 10.1007/s004649900568.
14. Champault G, Cazacu F, Taffinder N. Serious trocar accidents in laparoscopic surgery: a French survey of 103,852 operations. *Surg Endosc* 1996;6(5):367–370.
15. Merlin TL, Hiller JE, Maddern GJ, et al. Systematic review of the safety and effectiveness of methods used to establish pneumoperitoneum in laparoscopic surgery. *Br J Surg* 2003;90(6):668–679. DOI: 10.1002/bjs.4203.
16. Bonjer HJ, Hazebrek EJ, Kazemier G, et al. Open versus closed establishment of pneumoperitoneum in laparoscopic surgery. *Br J Surg* 1997;84(5):599–602. DOI: 10.1002/bjs.1800840506.

17. Catarci M, Carlini M, Gentileschi P, et al. Major and minor injuries during the creation of pneumoperitoneum: a multicenter study on 12,919 cases. *Surg Endosc* 2001;15(6):566–569. DOI: 10.1007/s004640000381.
18. Testini M, Piccini G, Lissidini G, et al. Management of descending duodenal injuries secondary to laparoscopic cholecystectomy. *Dig Surg* 2008;25(1):12–15. DOI: 10.1159/000114196.
19. Croce E, Golia M, Russo R, et al. Duodenal perforations after laparoscopic cholecystectomy. *Surg Endosc* 1999;13(5):523–525. DOI: 10.1007/s004649901027.
20. Berry SM, Ose KJ, Bell RH, et al. Thermal injury of the posterior duodenum during laparoscopic cholecystectomy. *Surg Endosc* 1994;8(3):197–220. DOI: 10.1007/BF00591829.
21. Machado N. Duodenal injury post laparoscopic cholecystectomy: incidence, mechanism, management outcome. *World J Gastrointest Surg* 2016;8(4):335–344. DOI: 10.4240/wjgs.v8.i4.335.
22. El-Banna M, Abdel-Atty M, El-Meteini M, et al. Management of laparoscopic-related bowel injuries. *Surg Endosc* 2000;14(9):779–782. DOI: 10.1007/s004640000015.

# Frequency, Complications, and Predictive Factors for Performing Subtotal Laparoscopic Cholecystectomy in a Hepatobiliary Unit: A Comparative Cohort Study

Alexia Farrugia<sup>1</sup>, Niranjana Ravichandran<sup>2</sup>, Majid Ali<sup>3</sup>, Harry Blege<sup>4</sup>, Saboor Khan<sup>5</sup>, For Tai Lam<sup>6</sup>, Jawad Ahmad<sup>7</sup>, Gabriele Marangoni<sup>8</sup>

## ABSTRACT

**Aims:** Laparoscopic subtotal cholecystectomies (LSCs) are occasionally performed for difficult gallbladder (GB) surgery. The aim of this study is to determine the rate, complications, and factors predictive of performing LSC in a hepatobiliary (HPB) unit, in comparison to patients who have undergone a conventional operation.

**Materials and methods:** A 5-year retrospective review of laparoscopic cholecystectomies (LCs) was performed by HPB team at a tertiary center. Demographic, operative, and postoperative data were identified. A randomized group (generated using online randomization software Research Randomizer®) of LC patients was identified from the study cohort, who had the same data recorded for comparison. Significance level was set at  $p < 0.05$  when comparing the two groups of LC and LSC.

**Results:** A total of 1,613 patients underwent LC, of which, 102 (6.3%) underwent LSC. The complication rate was 12.7% in the LSC group, mainly consisting of bile leak (3.9%) and collection requiring drainage (0.98%). The LC group had a 4.9% complication rate, of which, one bile leak was reported, i.e., 1 (0.98%). The length of stay was significantly longer in the LSC group (2 days vs 0 days in the LC group), and this group also had a slightly higher readmission rate (8.8% vs 3.92%). Laparoscopic subtotal cholecystectomy was found to be more likely in patients with previous cholecystitis, thickened GB wall on imaging and previous endoscopic retrograde cholangiopancreatography (ERCP).

**Conclusion:** Laparoscopic subtotal cholecystectomy is a safe procedure and the above characteristics may be used to potentially predict who is more likely to undergo LSC. This may aid in the consenting process and also help to create a score that predicts the probability of undergoing LSC.

**Keywords:** Gallbladder, Laparoscopic cholecystectomy, Predictive factors, Subtotal cholecystectomy.

*World Journal of Laparoscopic Surgery* (2019): 10.5005/jp-journals-10033-1369

## INTRODUCTION

Since the 1980s, LC has been the gold standard procedure to treat benign gallbladder (GB) disease. This allows for a shorter hospital stay and operating time as well as quicker postoperative rehabilitation and lower wound infection rates.<sup>1</sup> However, in some cases, such as adhesion, fibrosis, Mirizzi's syndrome, biliary anomalies, empyema of the GB, or gangrene, dissection of Calot's triangle may be very difficult. Previously, this used to be dealt with by converting to an open procedure, which prolongs hospital stay and could be associated with higher complication rates.<sup>2</sup> This led to the development of laparoscopic cholecystectomies (LSC), which may be attempted to avoid injury to the bile ducts and, therefore, allow a difficult cholecystectomy to still be done as a day-case procedure or potentially with only overnight stay.<sup>3,4</sup>

There are several ways to perform LSC. One method is to excise the anterior wall of the GB with stone extraction and leave the posterior wall attached to the liver. Another method is fundus-first excision of the GB followed by division at the Hartmann's pouch. The cystic duct stump can be either left open or closed using endoloop, an intracorporeal stitch, or stapled. The mucosa of the posterior wall of the remnant GB is diathermied or left alone with or without a drain *in situ*.<sup>5</sup>

The LSC has been shown to reduce the need for conversion to an open procedure, thus reducing the length of stay and other complications associated with the open cholecystectomy.<sup>6</sup> Studies have also shown that this procedure decreases the bile duct injury rate<sup>3,7-9</sup> and is safe in cirrhotic patients.<sup>10</sup> The aim was to determine

<sup>1</sup>Department of HPB Surgery, University Hospitals Coventry and Warwickshire, Coventry, West Midlands, UK

<sup>2-8</sup>Department of Surgery, University Hospitals Coventry and Warwickshire, Coventry, West Midlands, UK

**Corresponding Author:** Gabriele Marangoni, Department of Surgery, University Hospitals Coventry and Warwickshire, Coventry, West Midlands, UK, Phone: +44 2476965269, e-mail: Gabriele.marangoni@uhcw.nhs.uk

**How to cite this article:** Farrugia A, Ravichandran N, Ali M, *et al.* Frequency, Complications, and Predictive Factors for Performing Subtotal Laparoscopic Cholecystectomy in a Hepatobiliary Unit: A Comparative Cohort Study. *World J Lap Surg* 2019;12(2):53-55.

**Source of support:** Nil

**Conflict of interest:** None

the rate of LSC and its associated complications in a HPB unit and also to determine the predictive factors for performing LSC, if any.

## MATERIALS AND METHODS

The study was registered with the local authorities (audit number 215). All patients who underwent LC between 2013 and 2017 at a tertiary center were retrospectively reviewed to determine the frequency of LSC. The data for the initial patient cohort was obtained from the hospital coding team, and patients who underwent LSC were extracted from the operation notes. The inclusion criteria were

patients over the age of 18, who had a cholecystectomy, however, excision of the GB was performed at the level of Hartmann's pouch or the posterior wall of the GB was left *in situ*. Patients under the age of 18 or in cases where method that had been used was unclear were excluded from the study. Data were collected from electronic patient records, regarding age, gender, indication for surgery, procedure done (either LC or LSC), preoperative liver function tests, ultrasound scan results, common bile duct (CBD) dilatation, BMI, GB thickness on ultrasound, other investigations such as endoscopic retrograde cholangiopancreatography (ERCP), magnetic resonance cholangiopancreatography (MRCP), or hepatobiliary iminodiacetic acid (HIDA) (scintigraphy) scans, intraoperative details, length of stay, and postoperative complications.

A matched, randomized sample was drawn from the LC cohort, using Research Randomizer®. The two groups, LSC and LC, were compared to determine that characteristics, if any, that could predict the need for LSC and whether the groups differed with respect to complications and length of stay. Odds ratios were calculated to assess the risk of patients having a subtotal cholecystectomy. These were assessed using IBM SPSS V23.

## RESULTS

A total of 1,613 patients underwent LC in the HPB unit during this period, of which, 102 (6.3%) had an LSC (55 females and 47 males) and 4 (0.24%) were converted to open surgery. Thirty-six (2.23%) of these LSCs were done in the acute setting for cholecystitis, while only 16 (15.7%) of the LC group were done acutely.

Indications for LSC were acute cholecystitis (56 patients, 54.9%), gallstones causing biliary colic (25 patients 24.5%), gallstone pancreatitis (10 patients, 9.8%), cholangitis (6 patients, 5.9%), Mirizzi's syndrome (2 patients, 1.96%), CBD stones (2 patients 1.96%), and acalculous cholecystitis (1 patient, 0.98%). Indications for LC were gallstones causing biliary colic (66 patients 64.7%), acute cholecystitis (21 patients, 20.6%), gallstone pancreatitis (13 patients, 12.7%), dyskinesia (1 patient, 0.98%), and GB polyp (1 patient, 0.98%). Complications in each group are shown in Table 1.

Odds ratios were calculated to assess the correlation between several characteristics and the likelihood of having LSC rather than LC. We can see that previous cholecystitis, thickened GB wall on ultrasound scan, and previous ERCP led to a higher likelihood that subtotal cholecystectomy would be required. These are shown in Table 2.

**Table 1:** Indication for LSC were acute cholecystitis are shown in each group

	LSC	LC	<i>p</i> value
Complications	13 (12.7%)	5 (4.9%)	<0.001
Bile leak	4 (3.9%)	1 (0.98%)	<0.001
Collection (with drainage)	1 (0.98%)	0	<0.001
CBD injury	0	1 (0.98%)	<0.001
Retained stone	1 (0.98%)	0	<0.001
Gastric ulcer	2 (1.96%)	0	<0.001
Hospital-acquired pneumonia	1 (0.98%)	0	<0.001
Ileus	1 (0.98%)	0	<0.001
Bleeding	0	2 (1.96%)	<0.001
Readmission	9 (8.8%)	4 (3.92%)	0.526
Other complications	3 (2.94%)	1 (0.98%)	<0.001
Median length of stay/days (IQR)	2 (2–3)	0 (0–1)	<0.001

LSC, laparoscopic subtotal cholecystectomy; LC, laparoscopic cholecystectomy; CBD, common bile duct; IQR, interquartile range. *p* < 0.05 was considered statistically significant

## DISCUSSION

The main use of a subtotal cholecystectomy is in the context of acute cholecystitis or repeated cholecystitis where inflammation and fibrosis may make safe dissection of Calot's triangle more difficult. In such a situation, conversion to open procedure is more common, and thus subtotal cholecystectomy may be of use in situations where cholecystectomy for acute inflammation is slightly delayed.<sup>11</sup> However, there have been reports of longer operating times<sup>12</sup> and more blood loss<sup>13,14</sup> as well as increased hospital stay<sup>14</sup> when compared to normal cholecystectomy. Our data confirms a slightly higher complication rate and longer hospital stay. However, other studies have shown no differences in complications and hospital stay,<sup>15</sup> and a meta-analysis has found that the complication rates for subtotal cholecystectomy are similar to total cholecystectomy, so that it can be made a simple and effective procedure for difficult GB.<sup>16</sup>

When compared with procedures converted to open cholecystectomy, patients with LSC had more bile duct injury, less wound infection, shorter hospital stay, more recurrent biliary events, more postoperative ERCP, and a higher reintervention rate.<sup>17</sup> It is, however, less complicated than open cholecystectomy and has decreased costs.<sup>18</sup> Another possible complication of LSC is retention of stone within the Hartmann's pouch, which may even require reoperation, though this was not seen in our cohort.<sup>19</sup>

No defined risk factors were reported for subtotal cholecystectomy, though there have been associations with high C-reactive protein (CRP) and Tokyo grading.<sup>20</sup> Shingu et al. attempted to create a predictive score for LSC which consisted of preoperative CRP elevation, wall thickened GB, atrophic GB, pericholecystic abscess, and structure of the hepatic bile duct. Mean of the predictive score in LSC was 8.2, and ideal cutoff point for score was 8; specificity and sensitivity toward LSC was 76.0% and 77.0%, respectively.<sup>21</sup> However, the use of such a score has not been widely implemented. We have seen that our study partially corroborates this, as patients who had previous cholecystitis, thickened GB wall on imaging, and previous ERCP (*p* < 0.01) were more likely to require subtotal cholecystectomy. This may be related to increased local inflammation in the area causing difficulty in dissecting Calot's triangle in patients with several episodes of cholecystitis and those requiring ERCP.

## CONCLUSION

Laparoscopic subtotal cholecystectomy is a safe procedure to perform in cases of difficult cholecystectomy, despite a slightly higher length of stay and complication rate than LC. It is more likely in patients with repeated episodes of cholecystitis, requiring previous ERCP or having a thickened GB wall. In the future, these characteristics may be used in the formation of a predictive score

**Table 2:** Predictive factors for subtotal cholecystectomy

Preoperative characteristic	Odds ratio (95% CI)
Jaundice	1.8 (0.9–3.6)
Pancreatitis	0.8 (0.4–1.9)
Cholecystitis	4.3 (2.3–8.0)
Thickened gallbladder wall	6.1 (3.3–11.1)
ERCP	4.7 (2.2–9.9)
BMI > 30	1.2 (0.7–2.1)

CI, confidence interval; BMI, body mass index



for subtotal cholecystectomy, also allowing the surgeon to obtain patient's consent prior to the operation; however, more work is required for such a score to be finalized.

## CLINICAL SIGNIFICANCE

An LSC may be a way to avoid converting to an open procedure, as the complication rate and length of stay are only slightly higher than a normal LC. Certain factors such as previous inflammation and ERCP may mean that a patient may be more likely to need a laparoscopic subtotal cholecystectomy. With more data, a predictive score may be formed.

## REFERENCES

1. Vracko J, Hunt MY, Wiechel KL. Safe laparoscopic cholecystectomy. *Surg Endosc* 2005;19(12):1666. DOI: 10.1007/s00464-004-2138-y.
2. Wolf AS, Nijssen BA, Sokal SM, et al. Surgical outcomes of open cholecystectomy in the laparoscopic era. *Am J Surg* 2009;197(6):781–784. DOI: 10.1016/j.amjsurg.2008.05.010.
3. Beldi G, Glatli A. Laparoscopic subtotal cholecystectomy for severe cholecystitis. *Surg Endosc* 2003;17(9):1437–1439. DOI: 10.1007/s00464-002-9128-8.
4. Krahenbuhl L, Sclabas G, Wente MN, et al. Incidence, risk factors, and prevention of biliary tract injuries during laparoscopic cholecystectomy in Switzerland. *World J Surg* 2001;25(10):1325–1330. DOI: 10.1007/s00268-001-0118-0.
5. Henneman D, da Costa DW, Vrouwenraets BC, et al. Laparoscopic partial cholecystectomy for the difficult gallbladder: a systematic review. *Surg Endosc* 2013;27(2):351–358. DOI: 10.1007/s00464-012-2458-2.
6. Michalowski K, Bornman PC, Krige JE, et al. Laparoscopic subtotal cholecystectomy in patients with complicated acute cholecystitis or fibrosis. *Br J Surg* 1998;85(7):904–906. DOI: 10.1046/j.1365-2168.1998.00749.x.
7. Sinha I, Smith ML, Safranek P, et al. Laparoscopic subtotal cholecystectomy without cystic duct ligation. *Br J Surg* 2007;94(12):1527–1529. DOI: 10.1002/bjs.5889.
8. Nakajima J, Sasaki A, Obuchi T, et al. Laparoscopic subtotal cholecystectomy for severe cholecystitis. *Surg Today* 2009;39(10):870–875. DOI: 10.1007/s00595-008-3975-4.
9. Harilingam MR, Shrestha AK, Basu S. Laparoscopic modified subtotal cholecystectomy for difficult gall bladders: A single-centre experience. *J Minim Access Surg* 2016;12(4):325–329. DOI: 10.4103/0972-9941.181323.
10. Palanivelu C, Rajan PS, Jani K, et al. Laparoscopic cholecystectomy in cirrhotic patients: the role of subtotal cholecystectomy and its variants. *J Am Coll Surg* 2006;203(2):145–151. DOI: 10.1016/j.jamcollsurg.2006.04.019.
11. Horiuchi A, Watanabe Y, Doi T, et al. Delayed laparoscopic subtotal cholecystectomy in acute cholecystitis with severe fibrotic adhesions. *Surg Endosc* 2008;22(12):2720–2723. DOI: 10.1007/s00464-008-9879-y.
12. Singhal T, Balakrishnan S, Hussain A, et al. Laparoscopic subtotal cholecystectomy: initial experience with laparoscopic management of difficult cholecystitis. *Surgeon* 2009;7(5):263–268. DOI: 10.1016/S1479-666X(09)80002-4.
13. Tamura A, Otsuka Y, Tsuchiya M, et al. Perioperative and long follow up evaluation of laparoscopic subtotal cholecystectomy. *HPB* 2012;2:338.
14. Ali L, Bashir T, Bashir S. Laparoscopic subtotal cholecystectomy in difficult cholecystitis - our experience. *Pak J Med Health Sci* 2015;9(3):917–919.
15. Peker KD, Alis H. Laparoscopic subtotal cholecystectomy could be an alternative to conversion. *Med J Bakirkoy* 2017;13(3):113–117. DOI: 10.5350/BTDMJB201713301.
16. Elshaer M, Gravante G, Thomas K, et al. Subtotal cholecystectomy for "difficult gallbladders": systematic review and meta-analysis. *JAMA Surg* 2015;150(2):159–168. DOI: 10.1001/jamasurg.2014.1219.
17. van Dijk AH, Donkervoort SC, Lameris W, et al. Short- and long-term outcomes after a reconstituting and fenestrating subtotal cholecystectomy. *J Am Coll Surg* 2017;225(3):371–379. DOI: 10.1016/j.jamcollsurg.2017.05.016.
18. Kim Y, Wima K, Jung AD, et al. Laparoscopic subtotal cholecystectomy compared to total cholecystectomy: a matched national analysis. *J Surg Res* 2017;218:316–321. DOI: 10.1016/j.jss.2017.06.047.
19. Chowbey P, Sharma A, Goswami A, et al. Residual gallbladder stones after cholecystectomy: a literature review. *J Minim Access Surg* 2015;11(4):223–230. DOI: 10.4103/0972-9941.158156.
20. Jeong IO, Kim JY, Choe YM, et al. Efficacy and feasibility of laparoscopic subtotal cholecystectomy for acute cholecystitis. *Korean J Hepatobiliary Pancreat Surg* 2011;15(4):225–230. DOI: 10.14701/kjhbps.2011.15.4.225.
21. Shingu Y, Sakamoto E, Norimizu S. Preoperative prediction of laparoscopic subtotal cholecystectomy for severe cholecystitis. *Am J Gastroenterol* 2015;110(5):S27. DOI: 10.14309/00000434-201510001-00064.

# Totally Laparoscopic vs Open Transhiatal Esophagectomy: Our Experience in 93 Patients

Ali Jangjoo<sup>1</sup>, Sadjad Noorshafiee<sup>2</sup>, Ehsan Alaei<sup>3</sup>, Yasaman Navari<sup>4</sup>, Mahdi Jabbari Nooghabi<sup>5</sup>

## ABSTRACT

**Introduction:** The incidence of esophageal cancer has been increasing in the last decade. Different types of treatments are available, including minimally invasive esophagectomy (MIE). The aim of this study was to compare the early outcomes of the open vs totally laparoscopic transhiatal esophagectomy.

**Materials and methods:** This case-control study was conducted between May 2012 and January 2014. Patients with esophageal cancer who presented to Imam Reza Hospital, Mashhad, Iran, were assessed and their eligibility for the surgery type was investigated.

**Results:** Ninety-three esophagectomies performed. The open group comprised 57 patients and the laparoscopic group consisted of 36 patients. Mortality occurred in three patients in the open group and seven patients in the laparoscopic group ( $p < 0.05$ ). Chylothorax happened in four patients in the open group and only in one patient in the laparoscopic, which showed no significant difference. The mean operating time was  $75 \pm 16$  minutes in the open group and  $125 \pm 25$  minutes in the laparoscopic group ( $p < 0.05$ ).

**Conclusion:** Minimally invasive transhiatal esophagectomy is an available option for treatment of esophageal cancer, but our results should be interpreted with caution due to low sample size and our primary experience in patient selection.

**Keywords:** Esophageal cancer, Esophagectomy, Laparoscopy, Transhiatal.

*World Journal of Laparoscopic Surgery* (2019): 10.5005/jp-journals-10033-1370

## INTRODUCTION

The incidence of esophageal cancer has been increasing in the last decades.<sup>1</sup> In the United States, 17,000 new cases are diagnosed and 15,000 cases die annually.<sup>2</sup> In our region in the north of Iran, this disease is endemic with a prevalence rate of 180/1,00,000 population. The mean age of the patients is 60 years. Different types of therapy are available for this cancer, but there is a general agreement that surgery could be the best option.<sup>1-10</sup> Surgical treatments consist of different types of methods that are used today. Most types of current surgical approaches are invasive and harsh and have multiple complications especially respiratory one. Today, minimally invasive methods, including laparoscopy, have progressively improved.<sup>5,10,11</sup> The aim of this study was to compare the early outcomes of the open vs totally laparoscopic transhiatal esophagectomy.

## MATERIALS AND METHODS

This pilot case-control study was conducted between May 2012 and January 2014 after obtaining the approval of the Ethics Committee of Mashhad University of Medical Sciences, Mashhad, Iran. Study population included 93 patients, after excluding patients with missing data; the study participants consisted of patients who presented with esophageal cancer to Imam Reza Hospital and were candidates for surgery after preoperative workup and approval of their eligibility by a multidisciplinary team. Patients with cervical esophagus tumor, prior open upper abdominal surgeries, and tumor higher than carina level were excluded from the study. All patients underwent neoadjuvant chemoradiotherapy at least 4 weeks before surgery. The procedures were described and an informed consent was obtained from all patients. They were randomly assigned to two groups, namely, open and laparoscopy groups. Patients underwent either open or laparoscopic transhiatal

<sup>1,3</sup>Surgical Oncology Research Center, Mashhad University of Medical Sciences, Mashhad, Iran

<sup>2,4</sup>Endoscopic and Minimally Invasive Surgery Research Center, Mashhad University of Medical Sciences, Mashhad, Iran

<sup>5</sup>Department of Statistics, Faculty of Mathematical Sciences, Ferdowsi University of Mashhad, Mashhad, Iran

**Corresponding Author:** Sadjad Noorshafiee, Endoscopic and Minimally Invasive Surgery Research Center, Mashhad University of Medical Sciences, Mashhad, Iran, Phone: +98 513-8402972, e-mail: emis@mums.ac.ir

**How to cite this article:** Jangjoo A, Noorshafiee S, Alaei E, *et al.* Totally Laparoscopic vs Open Transhiatal Esophagectomy: Our Experience in 93 Patients. *World J Lap Surg* 2019;12(2):56-58.

**Source of support:** Research Department of Mashhad University of Medical Sciences (ID: 940066)

**Conflict of interest:** None

esophagectomy. The data concerning the type of operation, type of conduit, pylorus drainage procedures, intraoperative complications, chest tube insertion and amount and type of drained fluid, postoperative complications, operative time, and the need for reoperation were recorded. Then the data were analyzed using SPSS version 16 with Fisher's exact test and Pearson's Chi-square test.  $p$  value  $< 0.05$  was set as statistically significant.

## Surgical Technique

Patients were operated on under general anesthesia in supine position with legs apart. The surgeon stands between the patient's legs. The peritoneal cavity was explored for metastasis or any finding that precludes safe surgery via 10 mm infraumbilical port. Another 10 mm port was inserted for ligature device (10 × 35; Covidien, USA) for dissection in left subcostal area in the region

nearest to the neck. The 5 mm ports were placed in subxiphoid for liver retractor, right subcostal region in midclavicular line, for the left hand of the surgeon, and left subcostal anterior axillary line for the assistant. Then the left lobe of the liver was retracted and dissection began by dividing the phrenoesophageal ligament. The esophagus was dissected from the adjacent crura. The abdominal esophagus was handled with a surgical tape encircling it for different maneuvers for dissection of the mediastinal part of the esophagus. Then the esophagus was dissected up as high as possible to the neck, under the direct vision of the scope. Thereafter, gastrolysis was performed by preserving the right gastric and right gastroepiploic arcades using a  $10 \times 35$  ligature. Kocher maneuver and pyloroplasty were not performed. After dissecting the left gastric artery lymph nodes, the gastroesophageal junction was stapled and divided to make a conduit. Then a suture was tied between the conduit and the esophagus to pull the stomach up through the neck. An oblique incision was made parallel and anterior to the left sternocleidomastoid muscle and the cervical esophagus was explored, dissected, and brought to the incision. In this step, care was taken to avoid recurrent laryngeal nerve injury. The stomach was brought up to the neck via esophagus traction and the suture between them was cut and a hand-sewn single-layer end-to-side esophagogastric anastomosis was performed. No nasogastric tube was used. Then the anastomosis was drawn back to the neck and the incision was closed with simple nylon sutures. No feeding jejunostomy was used. If required, the chest tube was inserted at the end of the operation. All patients were transferred to the intensive care unit.

The open procedure was performed in the same manner but via midline laparotomy.

### Statistical Analysis

The data concerning the type of operation, type of conduit, pylorus drainage procedures, intraoperative complications, chest tube insertion, and amount and type of drained fluid, postoperative complications, operative time, and need for reoperation were recorded. Then the data were analyzed using SPSS version 16 with Fisher's exact test and Peterson's Chi-square test.  $p$  value  $< 0.05$  was set as statistically significant.

### RESULTS

Totally, 93 patients were enrolled in the study. Of the 93 patients, 57 had open procedure and 36 had laparoscopic esophagectomy. The mean age was  $60 \pm 11$  and male to female (M:F) ratio was 1.5:2 in open group and the mean age was  $57 \pm 15$  and M:F ratio was 1.4:2 in laparoscopic group without significant difference. Mortality occurred in 3 (5.3%) patients in the open group and 7 (19.4%) patients in the laparoscopic group ( $p = 0.037$ ). Four (7%) patients had chylothorax in the open group and 1 (2.8%) patient in laparoscopic group ( $p = 0.354$ ). Other morbidities happened in both groups but without statistically significant difference, consisting of one recurrent laryngeal nerve palsy in open group and two case of neck fistula in laparoscopic group. Fifteen (26.3%) patients had chest tube in open group and 8 (22.2%) patients in laparoscopic group ( $p = 0.425$ ). Three categories of chest tube drainage were considered, namely, more than 400 cc, less than 400 cc, and no drainage. In the open group, 10 patients had more than 400 cc (17.5%), 4 patients had less than 400 cc (7%), and 43 had no drainage. In the laparoscopic group, 3 patients had more than

400 cc and 33 (91.7%) patients had no drainage. The two groups showed no significant difference in term of the drainage volume ( $p = 0.087$ ).

Regarding mortality and morbidity, no intraoperative death, and no major bleeding occurred; packed cell transfusion was also not required.

The mean operative time was  $75 \pm 16$  minutes in the open group and  $125 \pm 25$  minutes in the laparoscopic group ( $p < 0.05$ ).

Two laparoscopic procedures were converted to open, i.e., one patient due to tumor invasion to aorta and one due to invasion to carina. In another case, the lack of vision and inability to dissect the esophagus led to open surgery. Hospital staying was  $8 \pm 1.7$  days in open group and  $7 \pm 1.9$  days in laparoscopic group ( $p > 0.05$ ).

### DISCUSSION

According to the literature, minimally invasive esophagectomy (MIE) is usually a combination of laparoscopy, thoracoscopy, laparotomy or thoracotomy, with or without cervical anastomosis.<sup>1-3</sup> In the study by Luketich et al.<sup>1</sup> which was performed on more than 1,000 MIEs, two groups were compared in terms of laparoscopic-thoracoscopic MIE (Ivor Lewis MIE) and thoracoscopy-laparoscopy neck anastomosis (McKeown MIE or neck MIE). In the view of the complications and mortality, the total 30-day in-hospital mortality in both the groups was 1.68%. In our study, a 10% mortality rate was observed in hospital, with no out-hospital mortality in the 30-day period after surgery. Their study indicated no difference in mortality in two MIE groups, but in our study the mortality was statistically higher in the laparoscopic group. This can be partially attributed to the learning curve issues with minimally invasive approaches and poor patient selection. We should mention that their technique is completely different. In another study by Meng et al.,<sup>2</sup> open transhiatal esophagectomy was compared to MIE using thoracoscopic combined with minilaparotomy in 183 patients. Total mortality was five patients, which was lower than ours. Postoperative complications including anastomosis leakage (8 vs 2 in ours) and recurrent laryngeal nerve injury (8 vs 2 in ours) were similar in both groups. They reported chylothorax in 7 (3%) patients, but in our study it occurred in 5 (7%) patients. But these complications were the same in both groups in their study. Another study<sup>12</sup> compared the results of open vs laparoscopic transhiatal esophagectomy. The only difference in laparoscopic technique was abdominal phase of the operation which was performed in epigastrium with a 7-cm minilaparotomy. Just like our study, no pyloroplasty was performed in the laparoscopic group; but unlike our study, only 36 patients had neoadjuvant chemoradiotherapy. They had 9 (18%) conversions to open surgery, but we had 2 conversions. Similar to our study, laparoscopic group had longer operative time (300 minutes). No mortality was reported in MIE group, but one was reported in the in open group. In our study, three patients who underwent open surgery died and seven patients in the laparoscopy group. This difference may be due to patient selection or tumor location. Compared with our study, they had more morbidity, recurrent laryngeal nerve palsy (8 vs 1 in our study) and neck fistula (7 vs 2 in our study), but they reported less chylothorax (3 vs 5 in our study). In another study by Rodham et al.,<sup>13</sup> patients were studied in view of hospital stays. They reviewed 24 studies and concluded that patients underwent MIE by any method had lower hospital stay (mean of 3 days). In our study, the two groups showed no statistically significant difference in terms of hospital stay.

In an review article by Herbella et al.,<sup>14</sup> different types of MIE and conventional open surgery were compared and finally they concluded that MIE has less mortality and morbidity with the same oncologic results, but in our study mortality was higher and morbidity was lower in MIE.

In a study by Khithani et al.,<sup>15</sup> no mortality was observed after performing MIE using minilaparotomy. Interestingly, the major morbidity was pneumonia in 8 (24%) patients compared with 0 in our study. But they had no cervical leak. A study by Lee et al.<sup>16</sup> demonstrated that the only difference between MIE and open surgery is the abdominal operative time ( $90 \pm 27.6$  minutes in the laparoscopic group vs  $162 \pm 97.3$  minutes in the open group;  $p < 0.001$ ), which is consistent with our finding ( $76 \pm 15$  minutes vs  $125 \pm 25$  minutes, respectively, in laparoscopic and open group;  $p < 0.05$ ). They had a patient with pneumonia. Their mortality was 3 in MIE group and 2 in the open group. Their results were better than ours in terms of mortality. In another study by Gao et al.,<sup>17</sup> they compared the MIE (thoracoscopy, minilaparotomy, and cervical anastomosis) to open surgery. The operative time was higher in MIE group. They observed more pulmonary complications and anastomosis leakage in MIE group but mortality did not differ statistically in two groups.

## CONCLUSION

In summary, previous studies demonstrated heterogeneous results, which may result from different patient selections, different techniques, and study designs. Overall, we can conclude that there are reports on MIE with more patients undergoing unique techniques and involving better clarified patient selection to prevent mortality, morbidity, and heterogeneity of results.

Preoperative location of tumor should be defined by barium swallow and computed tomography scan. Endoscopic ultrasonography for clarifying the T stage of tumor is advocated for all patients. We also advocate using total laparoscopic transhiatal esophagectomy in tumors distal to carina level and early stage tumors. Preoperative chemoradiotherapy may decrease the bulk of tumor, thus optimizing the handling of tumor in the narrow space of mediastinum though it may obscure the dissection planes.

## COMPLIANCE WITH ETHICAL STANDARDS

### Informed Consent

Informed consent was obtained from all individual participants included in the study.

### Ethical Approval

All procedures performed in studies involving human participants were in accordance with the ethical standards of ethics Committee of Mashhad University of Medical Sciences, Mashhad, Iran.

## ACKNOWLEDGMENTS

The results described in this paper formed part of a thesis submitted by the third author for a postgraduate degree in surgery. The authors hereby wish to thank the Research Department of Mashhad University of Medical Sciences for its support and approval of the

proposal number 940066 and Ms. S Beigoli and Ms. M Hassanpour for their kind assistance in preparing the paper.

## REFERENCES

1. Luketich JD, Pennathur A, Awais O, et al. Outcomes after minimally invasive esophagectomy: review of over 1000 patients. *Ann Surg* 2012;256(1):95–103. DOI: 10.1097/SLA.0b013e3182590603.
2. Meng F, Li Y, Ma H, et al. Comparison of outcomes of open and minimally invasive esophagectomy in 183 patients with cancer. *J Thorac Dis* 2014;6(9):1218–1224. DOI: 10.3978/j.issn.2072-1439.2014.07.20.
3. Biere SS, Maas KW, Bonavina L, et al. Traditional invasive vs. minimally invasive esophagectomy: a multi-center, randomized trial (TIME-trial). *BMC Surg* 2011;11:2. DOI: 10.1186/1471-2482-11-2.
4. Puntambekar S, Kenawadekar R, Pandit A, et al. Minimally invasive esophagectomy in the elderly. *Indian J Surg Oncol* 2013;4(4):326–331. DOI: 10.1007/s13193-013-0263-6.
5. Santin BJ, Price P. Laparoscopic transhiatal esophagectomy at a low-volume center. *JSL* 2011;15(1):41–46. DOI: 10.4293/108680811X13022985131138.
6. Smithers BM, Gotley DC, Martin I, et al. Comparison of the outcomes between open and minimally invasive esophagectomy. *Ann Surg* 2007;245(2):232–240. DOI: 10.1097/01.sla.0000225093.58071.c6.
7. Avery KN, Metcalfe C, Berrisford R, et al. The feasibility of a randomized controlled trial of esophagectomy for esophageal cancer—the ROMIO (Randomized Oesophagectomy: Minimally Invasive or Open) study: protocol for a randomized controlled trial. *Trials* 2014;15:200. DOI: 10.1186/1745-6215-15-200.
8. Beigoli S, Sharifi Rad A, Askari A, et al. Isothermal titration calorimetry and stopped flow circular dichroism investigations of the interaction between lomefloxacin and human serum albumin in the presence of amino acids. *J Biomol Struct Dyn* 2019;37(9):2265–2282. DOI: 10.1080/07391102.2018.1491421.
9. Briez N, Piessen G, Bonnetain F, et al. Open versus laparoscopically-assisted oesophagectomy for cancer: a multicentre randomised controlled phase III trial—the MIRO trial. *BMC Cancer* 2011;11:310. DOI: 10.1186/1471-2407-11-310.
10. Luketich JD, Alvelo-Rivera M, Buenaventura PO, et al. Minimally invasive esophagectomy: outcomes in 222 patients. *Ann Surg* 2003;238(4):486–494; discussion 94–95. DOI: 10.1097/01.sla.0000089858.40725.68.
11. Wallner G, Zgodzinski W, Masiak-Segit W, et al. Minimally invasive surgery for esophageal cancer—benefits and controversies. *Kardiochir Torakochirurgia Pol* 2014;11(2):151–155. DOI: 10.5114/kitp.2014.43842.
12. Maas KW, Biere SS, Scheepers JJ, et al. Laparoscopic versus open transhiatal esophagectomy for distal and junction cancer. *Rev Esp Enferm Dig* 2012;104(4):197–202. DOI: 10.4321/S1130-01082012000400005.
13. Rodham P, Batty JA, McElnay PJ, et al. Does minimally invasive oesophagectomy provide a benefit in hospital length of stay when compared with open oesophagectomy? *Interact Cardiovasc Thorac Surg* 2016;22(3):360–367. DOI: 10.1093/icvts/ivv339.
14. Herbella FA, Patti MG. Minimally invasive esophagectomy. *World J Gastroenterol* 2010;16(30):3811–3815. DOI: 10.3748/wjg.v16.i30.3811.
15. Khithani A, Jay J, Galanopoulos C, et al. Zero leaks with minimally invasive esophagectomy: a team-based approach. *JSL* 2009;13(4):542–549. DOI: 10.4293/108680809X12589998404326.
16. Lee JW, Sung SW, Park JK, et al. Laparoscopic gastric tube formation with pyloromyotomy for reconstruction in patients with esophageal cancer. *Ann Surg Treat Res* 2015;89(3):17–23. DOI: 10.4174/astr.2015.89.3.117.
17. Gao Y, Wang Y, Chen L, et al. Comparison of open three-field and minimally-invasive esophagectomy for esophageal cancer. *Interact Cardiovasc Thorac Surg* 2011;12(3):366–369. DOI: 10.1510/icvts.2010.258632.



# A Randomized Clinical Trial of Laser Hemorrhoidoplasty vs Milligan and Morgan Hemorrhoidectomy

Hossein Shabahang<sup>1</sup>, Ghodrattollah Maddah<sup>2</sup>, Ahmadali Mofidi<sup>3</sup>, Mahdi Jabbari Nooghabi<sup>4</sup>, Saeedeh Hajebi Khaniki<sup>5</sup>

## ABSTRACT

**Introduction:** Hemorrhoidectomy is one of the most common surgical procedures, and other treatments such as laser hemorrhoidectomy had been used as an alternative. The aim of this study was to determine the outcome and postoperation complications of treatment by laser compared with open hemorrhoidectomy.

**Materials and methods:** In this randomized clinical trial (RCT), 85 cases with a second or third degree of hemorrhoids were assigned to two groups at random and followed for 6 months. Those patients in the intervention group were treated by laser hemorrhoidoplasty (LHP) and those in the control group underwent Milligan and Morgan hemorrhoidectomy. At the end of follow-up, 80 cases remained in the trial on whom postoperative pain [visual analog scale (VAS)], complications, and quality of life according to the 36-item Short Form Health Survey (SF-36) questionnaire were studied. Data were analyzed using R 3.5.1 software and  $p$  value  $<0.05$  was considered significant.

**Results:** The most common complaints were bleeding (57%) and pain (41%). Postoperative pain immediately and after 6 months was not significantly different between the two groups ( $p > 0.05$ ). No complications were seen in any groups in follow-up. All eight scales of SF-36 questionnaire, except general health, were significantly different in the two groups. Physical functioning was lower in patients who underwent LHP, whereas the patients' quality of life in other scales was better in the laser group. The total score of SF-36 was  $66.1 \pm 3.6$  and  $56.0 \pm 3.3$  in laser and surgery groups, respectively ( $p < 0.001$ ).

**Conclusion:** Laser hemorrhoidectomy is a safe procedure, not associated with any excessive postoperative complications. It improves patients' quality of life and can be a substitution of other surgical methods.

**Keywords:** Complications, Hemorrhoidectomy, Laser, Quality of life.

*World Journal of Laparoscopic Surgery* (2019); 10.5005/jp-journals-10033-1373

## INTRODUCTION

Hemorrhoid is one of the most common side effects of urbanization. More than 50% of people are affected by this disease over the past 50 years, and the disease has been seen in both sexes and across wide age ranges. As of today, signs of hemorrhoids are seen in 4.4% of the American population.

Hemorrhoid is a familiar cause of admission to surgical clinics and its treatment requires medical and surgical procedures, many of which are performed for hemorrhoids of grades II, III, and IV. One of the most prominent surgical procedures for hemorrhoids is Milligan and Morgan hemorrhoidectomy. Other techniques of hemorrhoid surgery involve using devices such as stapler or procedures such as laser therapy.<sup>1</sup>

Using lasers was primarily recognized by Maymen in 1960 upon the construction of the ruby laser. In the following years, various types of lasers were designed and built, and with the discovery of laser, a remarkable revolution was created in industrial, military, and medical world.

The laser was first used in medicine and ophthalmology. Today, laser treatment is not uncommon in the treatment of hemorrhoids for outpatients. During the treatment process, the arterial blood flow of hemorrhoids is halted using Doppler laser coagulation. In another method, laser is projected into the hemorrhoidal packet, causing subsequent fibrosis upon which the hemorrhoidal packet shrinks and sticks to the anal canal wall to prevent its prolapse.

Various types of lasers are of great benefit in the field medicine. Their different wavelengths can exert different effects in the tissues. The most popular lasers are the carbon dioxide laser, argon laser, and neodymium: yttrium–aluminum garnet.

<sup>1–3</sup>Endoscopic and Minimally Invasive Surgery Research Center, Mashhad University of Medical Sciences, Mashhad, Iran

<sup>4</sup>Department of Statistics, Ferdowsi University of Mashhad, Iran

<sup>5</sup>Student Research Committee, Department of Epidemiology and Biostatistics, Mashhad University of Medical Sciences, Mashhad, Iran

**Corresponding Author:** Saeedeh Hajebi Khaniki, Student Research Committee, Department of Epidemiology and Biostatistics, Mashhad University of Medical Sciences, Mashhad, Iran, Phone: +98 5138012806, e-mail: Hajebis951@mums.ac.ir

**How to cite this article:** Shabahang H, Maddah G, Mofidi A, *et al.* A Randomized Clinical Trial of Laser Hemorrhoidoplasty vs Milligan and Morgan Hemorrhoidectomy. *World J Lap Surg* 2019;12(2):59–63.

**Source of support:** Mashhad University of Medical Sciences, Iran

**Conflict of interest:** None

Using lasers in the treatment of hemorrhoid leads to minimal tissue damage and good hemostasis, and it can also reduce the duration of surgery and hospital stay. However, against all the benefits, specific training and precaution measurements are required to use lasers in therapy. Moreover, to protect their eyes from invisible lights produced by laser, it is a must that the surgeons use goggles.<sup>2,3</sup>

In this study, the effects of two surgical methods of Milligan and Morgan and the use of lasers in the treatment of hemorrhoids were evaluated in terms of the effectiveness of the treatment, the duration of surgery, and the possible complications caused by such medical methods.

## MATERIALS AND METHODS

This study was a phase 3, randomized open blind trial. It consisted of two parallel groups. Eighty patients were studied between



March 2011 and March 2013 and followed for 6 months at Ghaem and Sina Hospitals in Mashhad, Iran. Inclusion criteria are having been diagnosed with hemorrhoids grade II or III. Those who refused to follow-up were excluded from the study. The estimation of sample size was done using the result of Palper et al., type I error of 5%, power of 90%, and statistical software of PASS version 11.0.4 (Fig. 1).

Based on permuted block randomization with block size of four, patients were randomly assigned to two groups with an allocation ratio of 1. The intervention patient groups underwent LHP and those in control group were treated with Milligan and Morgan hemorrhoidectomy by the same surgeon (Flowchart 1).

In LHP, Diode Laser 1470 (CERALAS model; Biolitec Company) was used. In this method, the patient was first put under general anesthesia. After prep and drep (decrease the number of microorganisms at the operative site), special optical fiber entered the hemorrhoidal packet.

Then the hemorrhoidal packet was measured from the proximal part to the distal part using the LHP technique. In the next step, hemorrhoidopexy was done with running suture using 2.0 vicryl (absorbable sutures catgut sutures 0–4 Turkey) performed from the proximal to the distal part of the packet. At the end of the procedure, two or three packets were treated at a time. After performing the LHP, cold compression was done by placing ice over each packet for 3 minutes.

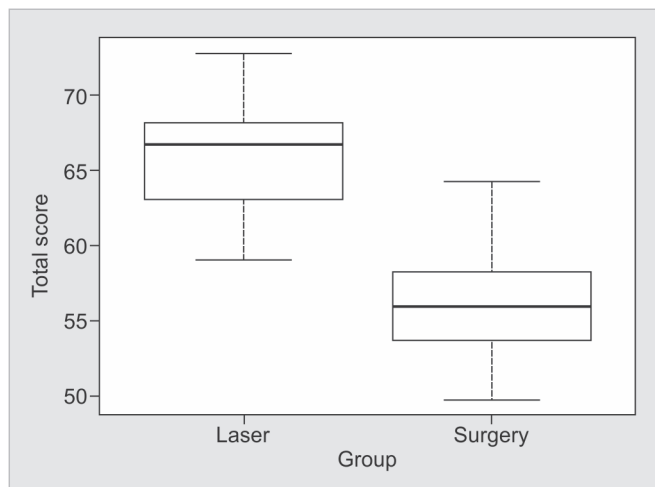
In the Milligan and Morgan method, after prep and drep, the patients were under either general or spinal anesthesia. Afterward, they were placed in the lithotomy position. By this method, three hemorrhoid packets with at an angle of about 60° were selected. Then the packet had to be eliminated below the tooth line of the anus while the skin and the mucous bridges between the packets stayed preserved.

The main outcome variables included pain, delayed bleeding, the presence of urinary retention, painful defecation, fistula, acute infection fissure, anal stenosis, fecal incontinence, and postoperative thrombosis. The length of hospitalization and quality of life of patients 6 months after operation were evaluated using SF-36 questionnaire. The 36-item SF-36 includes several domains of health-related quality of life, namely, general health, limitations of activities, physical health problems, emotional health problems, social activities, pain, and energy and emotions. A higher score indicates a better quality of life. The validity and reliability of the questionnaire were approved in Iranian population.<sup>4</sup>

This study had been approved by the ethics committee and the institutional review board of Mashhad University of Medical Sciences (IR.MUMS.REC.1391.93), and informed consent was obtained before enrollment. Registration ID of this study in the Iranian Registry of Clinical Trial is "IRCT20180204038605N1."

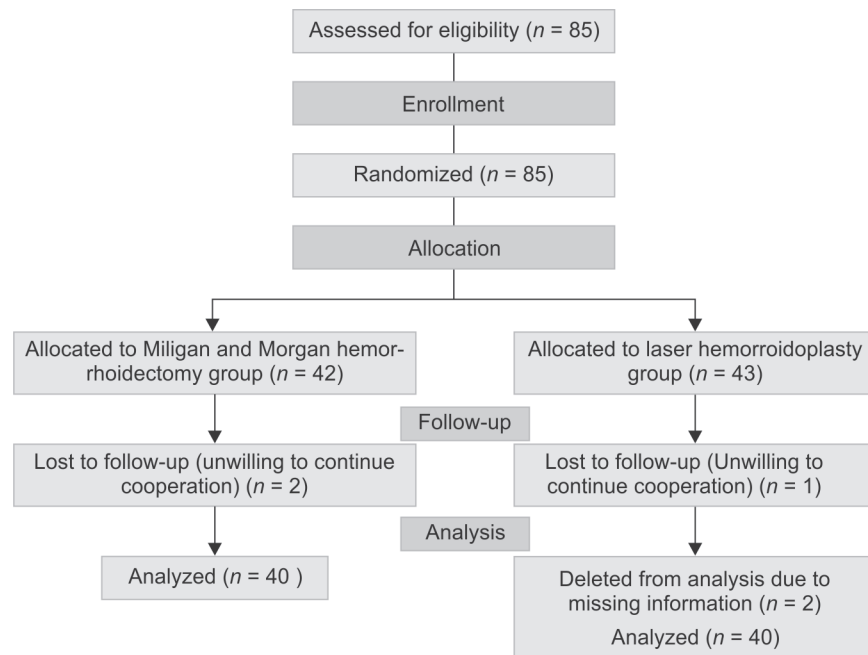
### Statistical Analysis

Data were analyzed by R software version 3.5.1. The differences among groups in terms of ordinal or scale variables were analyzed using the Mann–Whitney nonparametric test or independent *t* test.



**Fig. 1:** Box plot for total score of 36-item Short Form Health Survey (SF-36) questionnaire for two groups

**Flowchart 1:** CONSORT flow diagram: laser hemorrhoidoplasty vs Milligan and Morgan hemorrhoidectomy



The Chi-square or Fisher's exact test was used for comparison of the categorical variables between groups. The  $p$  value  $<0.05$  was considered as statistically significant.

## RESULTS

The mean age of the patients in the laser and the surgery groups was  $38.13 \pm 8.29$  years and  $38.73 \pm 9.53$  years, respectively. Thirty-six (45%) patients were male [18 patients (45.0%) in the surgery group and 18 patients (45.0%) in the laser group]. The main cause of referring to hospital in both groups was bleeding (65% vs 50%) and hemorrhoids of grade II was more common. No significant difference was observed between the two groups regarding sex, grade of hemorrhoid, and cause of referring to hospital (Table 1).

The pain severity based on VAS score immediately after surgery for half of the patients was more than 3 of 10 and for laser group 2 of 10. The median pain in laser and surgery groups was 2 and 3, respectively, which were not statistically different ( $p = 0.198$ ). 6 months after surgery the pain intensity reduced dramatically, resulting in the median pain of 1 of 10 in both the groups, but the mean of pain was  $1.20 \pm 0.40$  in the laser group and  $1.37 \pm 0.58$  in those who underwent Milligan and Morgan surgery (Table 2).

The length of hospitalization after surgery was  $1.70 \pm 0.65$  days for the surgery group and  $1.50 \pm 0.55$  days for the laser group. According to the result, no statistically significant difference was found between the two groups in this regard ( $p = 0.142$ ).

**Table 1:** Demographic characteristics of patients

Variable	Group		<i>p</i> value
	Laser ( <i>n</i> = 40)	Milligan and Morgan ( <i>n</i> = 40)	
Gender <sup>a</sup>			
Male	18 (45%)	18 (45%)	0.99 <sup>‡</sup>
Age (year) <sup>b</sup>	$38.12 \pm 8.29$	$38.72 \pm 9.52$	0.76 <sup>†</sup>
Cause of referring <sup>b</sup>			
Pain	14 (35%)	19 (47.5%)	0.26 <sup>§</sup>
Bleeding	26 (65%)	20 (50%)	
Itching	0	1 (2.5%)	
Grade of hemorrhoid <sup>b</sup>			
II	29 (72.5%)	25 (62.5%)	0.34 <sup>‡</sup>
III	11 (27.5%)	15 (37.5%)	

<sup>a</sup>Frequency, %

<sup>b</sup>Mean  $\pm$  standard deviation (SD)

<sup>‡</sup>Based on Pearson's Chi-square test

<sup>†</sup>Based on independent *t* test

<sup>§</sup>Based on Fisher's exact test

**Table 2:** Visual analog scale (VAS) pain immediately and 6 months after operation

VAS pain <sup>a</sup>	Group		<i>p</i> value <sup>‡</sup>
	Laser ( <i>n</i> = 40)	Milligan and Morgan ( <i>n</i> = 40)	
Immediately after operation	$2.35 \pm 0.80$ 2 (1–4)	$2.57 \pm 0.93$ 3 (1–5)	0.198
6 months postoperative	$1.20 \pm 0.40$ 1 (1–2)	$1.37 \pm 0.58$ 1 (1–3)	0.174

<sup>a</sup>Mean  $\pm$  standard deviation (SD), median (min–max)

<sup>‡</sup>Based on Mann–Whitney test

In addition, we evaluated the health of patients through the study of emotions and their ability to perform daily tasks by means of SF-36 questionnaire 6 months after operation. In the first step, patients were asked how they feel now and in comparison to the past year. In the laser group, 87.5% answered they are excellent or good now, while 47.5% of patients in the surgery group felt good. Nonetheless, the general health of patients regarding how they feel about 1 year ago and how they seem to be were the same ( $p = 0.094$ ). The total score of role limitations due to physical health scale was higher in those patients who were treated with laser ( $63.4$  vs  $56.9$ ) ( $p = 0.002$ ). In the field of physical health problem, patients evaluated in the terms of having difficulty with their work or other regular daily activities during the 4 last weeks, which was  $84.5 \pm 10.5$  in the surgery group and  $80.2 \pm 4.3$  in the laser group ( $p < 0.001$ ). Moreover, emotional health problems were less in laser group ( $p < 0.001$ ). In the seventh scale of questionnaire, two groups were compared regarding the pain of patients during the past 4 weeks and how much this pain interfered with their normal work, and it was revealed that pain in surgery group was significantly much more than that in the laser group ( $p < 0.001$ ), and two groups were not comparable in the field of energy and emotions ( $p < 0.001$ ). Finally, contrary to all other scales, the mean of physical functioning was higher in the surgery group and this difference was significant ( $p < 0.001$ ) (Table 3).

To sum up, the difference between two groups concerning mental component summary (MCS) was higher than the physical component summary (7.5 and 12.6). However, both were meaningful ( $p < 0.001$ ). The difference in total score of quality of life was  $2.2 \pm 1.0$ , which is in favor of the laser group ( $p = 0.037$ ) (Fig. 1).

## DISCUSSION

An uncomplicated hemorrhoidectomy is desirable for both the patient and the surgeon. Almost all the proposed hemorrhoidectomy techniques are expected to reduce postoperative pain, bleeding,

**Table 3:** Comparison of patient's quality of life 6 months after operation

Scale <sup>a</sup>	Group		<i>p</i> value <sup>‡</sup>
	Laser ( <i>n</i> = 40)	Milligan and Morgan ( <i>n</i> = 40)	
Physical functioning	$80.2 \pm 4.3$ 80 (70–87)	$84.5 \pm 10.5$ 86.7 (47–93)	$<0.001$
Role limitations due to physical health	$63.4 \pm 9.1$ 62.5 (50–75)	$56.9 \pm 9.4$ 50 (50–75)	0.002
Role limitations due to mental health	$81.2 \pm 14.2$ 83 (50–100)	$57.9 \pm 8.4$ 50 (50–67)	$<0.001$
Energy/fatigue	$57.5 \pm 10.6$ 58 (37–97)	$47.9 \pm 5.2$ 50 (37–67)	$<0.001$
Emotional well-being	$57.7 \pm 10.4$ 60 (40–77)	$48.3 \pm 5.5$ 47 (40–63)	$<0.001$
Social functioning	$72.5 \pm 10.8$ 70 (50–90)	$64.5 \pm 10.1$ 60 (40–80)	0.002
Pain	$57.5 \pm 11.2$ 59 (27–82)	$31.6 \pm 10.3$ 27 (18–54)	$<0.001$
General health	$58.7 \pm 6.6$ 58 (43–73)	$56.7 \pm 3.1$ 57 (50–63)	0.094

<sup>a</sup>Mean  $\pm$  standard deviation (SD), median (min–max)

<sup>‡</sup>Based on Mann–Whitney test

and length of stay and facilitate the timely return of the patient to daily activities and, thus, enhance the quality of life for the patients after surgery. Since the complications of such surgeries might be quite destructive and cause severe bleeding, using these techniques requires high proficiency and training. While selecting the surgical procedure, the skills and experiences of the surgeon need to be taken into account, so that the results of the surgery could be satisfactory and healthful.<sup>5</sup> In addition, the most common problem among patients after the surgery of hemorrhoidectomy is the acute pain during the first and second days after surgery. It is likely for the pain to trouble the patient for some days and this can be a matter of concern for the patient.<sup>6</sup>

Pain is a major cause that puts off patients from undergoing a hemorrhoidectomy. Beside the fact that pain itself is annoying, it is likely to cause certain problems such as urinary retention and fecal compaction. On the other hand, because postoperative pain is a very common side effect of hemorrhoidectomy, not many patients consider it as a surgical complication, but they see it as a predictable consequence of the surgery.<sup>7,8</sup>

We evaluated the postoperative pain in two time points which were immediately and 6 months after surgery based on VAS. The mean VAS score in patients who were treated with laser was 0.22 and 0.17 after surgery and in the 6 months follow-up, respectively. Moreover, these differences were not considered statistically significant.

Similar to our result, Arbman et al. claimed no significant differences between the two groups in terms of VAS.<sup>9</sup> Also in the study by Walfisch, no differences with regard to postoperative pain were observed between the laser-based method and hemorrhoidectomy or any other nonlaser methods.<sup>10</sup> In another experiment by Zahir on 50 patients treated with laser-based techniques, the pain alleviation frequency was reported to be as much as up to 65% compared to the control group.<sup>11</sup> However, in the study by Sankar, postoperative pain was significantly lower than that of other surgical procedures such as open surgery.<sup>12</sup> In another study by Masson, hemorrhoidectomy with lasers is known to cause less postoperative pain compared to other surgical methods such as open hemorrhoidectomy.<sup>13</sup> Besides in the study by Plapler, the mean pain severity has been reported as 1.13 (of 10) that was significantly lower than that in the control group who underwent Milligan and Morgan method or cold scalpel method.<sup>14</sup>

In our study, the length of hospitalization after surgery in the patients was  $1.70 \pm 0.65$  days for the surgery group and  $1.5 \pm 0.55$  for the laser group, and the two groups were not significantly different in terms of the time they were hospitalized. Nonetheless, in the study by Sankar, the lower length of hospitalization in the laser group was significant.<sup>12</sup> Also in the study by Masson, it was concluded that hemorrhoidectomy patients treated with laser-based methods had none or minimal need for hospitalization and lower costs, and they made a faster return to daily tasks.<sup>13</sup>

Our finding revealed that the quality of life in the LHP group in terms of both physical and MCS was relatively better ( $p < 0.05$ ). These results were similar to other studies.<sup>5,15</sup> Erdoğan et al. also evaluated the quality of life after stapler hemorrhoidectomy by using SF-36 questionnaire. They demonstrated that physical health (physical functioning, physical role restriction, and bodily pain) scores significantly improved after surgery.<sup>16</sup> Bouchard et al. in a multicenter trial followed patients who underwent hemorrhoidectomy for 1 year and reported that all physical and mental domains of quality of life significantly improved, and 88% of patients were satisfied or very satisfied by the surgery.<sup>15-18</sup>

The common postoperative complications in laser surgeries include delayed bleeding, presence of urinary retention, painful defecation, fistula, acute infection fissure, anal stenosis, fecal incontinence, and postoperative thrombosis. None of mentioned complications were observed in any of our patients within 6 months after surgery. Many studies support our findings. Sowula reports no cases of postoperative bleeding during the follow-up. He states that the patients who were treated with laser therapy had a much more facilitated postoperative period and that the complications of these methods were very rare.<sup>17</sup> Also Leff claimed that wound healing was observed in all cases, and it was inferred that hemorrhoidectomy with lasers did not promote any adverse effects of surgery on the patients.<sup>15</sup> In another experiment performed by Zahir on 50 patients treated by laser therapy, pain alleviation was reported to be up to 65%.<sup>11</sup> On the contrary, the result of some RCTs demonstrated the lower frequency of well treated by laser. As an example, in the study by Arbman, 86% of the hemorrhoidectomy patients who were treated with lasers had complete healing of their wounds within a follow-up of 3 weeks and no one developed symptoms of any sorts of infection. Of those patients who had a surgery with Milligan and Morgan method, only 18% had complete healing of wounds and symptoms of delayed improvement were detected in several cases. One of their patients had a minor wound infection, and even after 1 year, more than 10% of the hemorrhoid patients still showed symptoms of the disease.<sup>9</sup> In addition, Plapler counts a number of side effects for laser-based therapy. For instance, burning lesions and residual plicoma (skin tag) were detected in five patients under treatment with lasers due to the impairment of the laser system. However, even in this study practical and complete improvements were reported within a short period compared to hemorrhoidectomy.<sup>14</sup>

In the present study, redoing the operation was not required in any of patients in either group during the 6-month follow-up. Moreover, there was no recurrence of the disease during the 6 months and a complete remission was observed in all cases. However, Skobelkin pointed out that the recurrence was two times more in open surgery of Milligan and Morgan.<sup>18</sup>

Clearly, those patients in the laser group had an easier recovery. Similar to our study, in the study by Sankar, postoperative recovery period was significantly lower than other surgical procedures such as open surgery.<sup>12</sup>

## CONCLUSION

Hemorrhoidectomy through laser-based methods does not aggrandize the side effects of surgery in the patients. Furthermore, due to the ease of implementation and not imposing any additional risks to the patient at the time of performing and because of the possibility of performing it as outpatient surgery, these methods can be greatly beneficial and practical. They can be an alternative to the usual hemorrhoidectomy. Lasers are effective and safe in case of anal lesions and are comparable with other conventional methods of surgery. Effective methods with lasers, along with other available treatments, could expand new horizons in the treatment of anorectal diseases like hemorrhoidectomy. Nonetheless, further studies in this field are to be done.<sup>19</sup>

## COMPLIANCE WITH ETHICAL STANDARDS

### Informed Consent

Informed consent was obtained from all individual participants included in the study.

## Ethical Approval

All procedures performed in studies involving human participants were in accordance with the ethical standards of ethics Committee of Mashhad University of Medical Sciences, Mashhad, Iran.

## THIS PILOT CASE

This study was a phase 3, randomized open blind trial. It consisted of two parallel groups. Eighty patients were studied between March 2011 and March 2013 and followed for 6 months on Ghaem and Sina Hospitals in Mashhad, Iran, and approved by the ethics committee and the institutional review board of Mashhad University of Medical Science (IR.MUMS.REC.1391.93) and informed consent was obtained before enrollment. Registration ID of this study in Iranian Registry of Clinical Trial is "IRCT20180204038605N1."

## REFERENCES

1. Corman ML. Colon & rectal surgery 5th ed., vol. 12. Lippincott Williams & Wilkins; 2005. pp. 177–248.
2. Schwesinger WH, Hunter JG. Laser in general surgery. Surgical Clinics of North America 1992.
3. Andersen K. Laser technology—a surgical tool of the past, present, and future. AORN J 2003;78(794–802):805–807. DOI: 10.1016/S0001-2092(06)60639-X.
4. Montazeri A, Goshtasebi A, Vahdaninia M, et al. The short form health survey (SF-36): translation and validation study of the Iranian version. Qual Life Res 2005;14(3):875–882. DOI: 10.1007/s11136-004-1014-5.
5. MacRae HM, McLeod RS. Comparison of hemorrhoidal treatment modalities. a meta-analysis. Dis Colon Rectum 1995;38(7):687–694. DOI: 10.1007/BF02048023.
6. Balfour L, Stojkovic SG, Botterill ID, et al. A randomized double-blind trial of the effect of metronidazole on pain after closed hemorrhoidectomy. Dis Colon Rectum 2002;45(9):1186–1190. DOI: 10.1007/s10350-004-6390-y.
7. Bonica J. The management of pain. Philadelphia: Lea & Febiger; 1990. p. 26–27.
8. Chung YC, Hou YC, Pan AC, et al. CD105 expression in the development of haemorrhoids. Eur J Clin Invest 2004;34(2):107–112. DOI: 10.1111/j.1365-2362.2004.01305.x.
9. Arbmán G, Krook H, Haapaniemi S. Closed vs. Open hemorrhoidectomy is there any difference? Dis Colon Rectum 2012;43(1):31–34. DOI: 10.1007/BF02237240.
10. Walfisch S, Ohana N, Charuzi E. Nd: YAG laser for anorectal surgery: initial experience in Israel. Harefuah 2010;126(1–4):56.
11. Zahir KS, Edwards RE, Vecchia A, et al. Use of the nd-YAG laser improves quality of life and economic factors in the treatment of hemorrhoids. Conn Med 2007;64(4):199–203.
12. Sankar MY, Joffe SN. Laser surgery in colonic and anorectal lesions. Surg Clin North Am 2012;68(6):1447–1469. DOI: 10.1016/S0039-6109(16)44700-6.
13. Masson JL. Outpatient hemorrhoidectomy using the CO<sub>2</sub> laser. Wiad Lek 2010;63:27–32.
14. Plapler H, Hage R, Duarte J, et al. A new method for hemorrhoid surgery: intrahemorrhoidal diode laser, does it work? Photomed Laser Surg 2009;27(5):819–823. DOI: 10.1089/pho.2008.2368.
15. Leff EI. Hemorrhoidectomy—laser vs. nonlaser: outpatient surgical experience. Dis Colon Rectum 2011;35(8):743–746. DOI: 10.1007/BF02050322.
16. Erdoğan A, Sipahioglu NT, Erginoz E, et al. Quality of life after stapler haemorrhoidectomy evaluated by SF-36 questionnaire. Ulusal cerrahi dergisi 2013;29(2):59–62. DOI: 10.5152/UCD.2013.37.
17. Sowula A. The role of laser CO<sub>2</sub> in proctology. J Chir (Paris) 2010;127(4):227–229.
18. Skobelkin OK, Brekhov EI, Ul'ianov VI, et al. Experience in the use of laser instruments in surgery of the anorectal region. Khirurgiia (Mosk) 2008;10:65–68.
19. Bouchard D, Abramowitz L, Castinel A, et al. One-year outcome of haemorrhoidectomy: a prospective multicentre French study. Colorectal Dis 2013;15(6):719–726. DOI: 10.1111/codi.12090.

# Appendicular Stump Closure by Polymer Clip vs Endoloop in Laparoscopic Appendectomy

Vishal P Bhabhor

## ABSTRACT

**Introduction:** Several techniques are used to close the appendicular stump during laparoscopic appendectomy. This is especially important in developing countries where resources for training with endoloop are insufficient, and the simplicity of application of polymer clips can enable easy acceptance of laparoscopic appendectomy as a method in the treatment of acute appendicitis.

**Aim:** The aim of the study was to compare results of appendicular stump closure by polymer clip and endoloop with reference to

- Days of hospitalization,
- Infection rate, and
- Ease of application

**Materials and methods:** This is a prospective study of 70 cases of laparoscopic appendectomy operated in the Department of General Surgery, SSG Hospital, Vadodara, from October 2016 to October 2017 (35 patients in each group i.e., polymer clip application group and endoloop application group). Operative data were recorded, and the patients were followed up accordingly. Independent assessors were assigned to obtain days of hospitalization, infection rate, ease of application, and other secondary outcomes.

**Results:** It is more feasible for surgeons to use polymer clip than endoloop to close appendicular stump as per the surgeon's opinion taken after each surgery. However, days of hospitalization and postoperative complication rates were not statistically significant in both groups.

**Conclusion:** Closure of appendix stump with a polymer clip is a simple and safe method in laparoscopic appendectomy and is comparable with other methods of appendicular stump closure.

**Keywords:** Appendectomy, Ease of application, Endoloop, Polymer clip.

*World Journal of Laparoscopic Surgery* (2019): 10.5005/jp-journals-10033-1374

## INTRODUCTION

Laparoscopic appendectomy is superior or comparable to open appendectomy in terms of several surgical outcome measures for both uncomplicated and complicated appendicitis across most illness severity groups. Thus, laparoscopic appendectomy may be the preferred technique, irrespective of appendicitis diagnosis or disease severity.<sup>1</sup> Several techniques are used to close the appendicular stump during laparoscopic appendectomy.

The most commonly used surgical methods are associated with the use of endoloop ligature, laparoscopic staplers, metal or polymer clips, or application of purse-string suture with the invagination of the base of the appendix into the cecum, as in the classic surgery.<sup>2</sup>

However, the application of the endoloop demands dexterity and short training, while polymer clips may be more advantageous to use due to their easy of application and low cost.<sup>3</sup>

This is especially important in developing countries where resources for training with endoloop are insufficient, and the simplicity of application of polymer clips can enable easy acceptance of laparoscopic appendectomy as a method in the treatment of acute appendicitis.<sup>3</sup>

The objective of this study was to evaluate the technical feasibility and eventual advantages of this way of securing the base of the appendix.

## MATERIALS AND METHODS

This is a prospective study of 70 cases of laparoscopic appendectomy operated in the Department of General Surgery, SSG Hospital,

Department of General Surgery, Baroda Medical College, SSG Hospital, Maharaja Sayajirao University of Baroda, Vadodara, Gujarat, India

**Corresponding Author:** Vishal P Bhabhor, Department of General Surgery, Baroda Medical College, SSG Hospital, Maharaja Sayajirao University of Baroda, Vadodara, Gujarat, India, Phone: +91 7600543427, e-mail: bhabhorvishal33@gmail.com

**How to cite this article:** Bhabhor VP. Appendicular Stump Closure by Polymer Clip vs Endoloop in Laparoscopic Appendectomy. *World J Lap Surg* 2019;12(2):64–67.

**Source of support:** Nil

**Conflict of interest:** None

Vadodara from October 2016 to October 2017 (35 patients in each group, i.e., polymer clip application group and endoloop application group).

Patients were included in the study after proper clinical examination, laboratory findings, and ultrasonographic evidence of acute appendicitis in the outpatient department and emergency. The surgeon was the deciding method for closing appendicular stump by viewing the appendicular base and its diameter (by endoloop or by polymer clip).

All laparoscopic appendectomy was done by a consultant surgeon of different units of Surgery Department of SSG Hospital, Vadodara. Patients scheduled for laparoscopic appendectomy were administered antibiotics intravenously in the form of single-dose ceftriaxone just before the start of the surgery.



## Operative Technique

Pneumoperitoneum was established using a Veress needle inserted from the infraumbilical region. The first 10 mm trocar was introduced in the abdomen just below the umbilicus.

The second 5 mm trocar was placed just above the pubic symphysis and the third trocar of 5 mm in the left lower abdomen below the level of the umbilicus in the line of the anterior axillary fold. From 10 mm scope, 30° telescope was inserted and from 5 mm port dissection was performed.

After viewing the abdominal organs and confirming the diagnosis of acute appendicitis, the appendix was mobilized and skeletonized by cutting its mesoappendix using a harmonic scalpel or cautery. Further procedure to apply clips or endoloop was decided by the operating surgeon.

### For Polymer Clip Application

A 30° telescope was inserted from 5 mm scope, and from 10 mm trocar polymer clip applicator was inserted. The appendicular base was seen intraoperatively and an idea about diameter was made by the surgeon. If the diameter of the appendicular base was less than or equal to 10 mm approximately than it is easily closed by polymer clips. First clip was applied at the base of the appendix using clip applicator (Fig. 1), and a second clip was applied above the first clip using clip applicator. Then the appendix was cut with a harmonic scalpel or scissor above the second clip, and it was removed from 10 mm port. Ethicon HEM-O-LOK clip (polymer clip, Fig. 2) was used in this study. Polymer clip which was slipped or not covering appendicular stump was considered as a wasted clip.

### For Endoloop Application

Three endoloops were applied on appendicular base (Fig. 3) and the appendix was cut between the second and third loop by harmonic scalpel or scissors. The appendix was removed by a 10 mm port. Endoloop was made outside from chromic catgut and introduced by knot pusher from the trocar. Endoloop which was slipped and not covering appendicular stump was considered as wasted endoloop. In both groups, 10 mm port incision was closed with port vicryl and other port incisions were closed by ethilon 2-0. After the appendectomy appendix was sent for histopathologic examination in both groups.

Endoloop and clips are equally cost-effective, but the clip appears to be simpler in handling than the endo-loop and, like the stapler, offers closing, and cutting the appendix before dissecting

the mesoappendix. However, only appendices up to 16 mm in diameter can be clipped, a disadvantage not shared with the loop.<sup>4</sup>

Ease of application for endoloop and polymer clips was decided by the surgeon's opinion that was obtained by giving surgeon opinion form having options mentioned below

- Poor
- Good
- Excellent.

### Ease of Application

It was feasibility to close appendicular stump by polymer clip and endoloop, which was decided by the surgeon.

Ease of application measures feasibility for the surgeon that includes the time taken for closing appendicular stump, the proper closure of appendicular stump, and handling of endoloop and polymer clip intraoperative, which was decided by the surgeon; and he gives opinion accordingly. Time taken for closure of appendicular stump was time taken after skeletonization of appendix up to the closure of appendicular stump. After all this, considering the surgeon had given his opinion regarding "ease of application" in this study.

### Postoperative Care and Follow-up

Intravenous antibiotic (injection ceftriaxone 1 g 12 hourly) was given for 1 day than patients shifted on an oral antibiotics (tablet cefixime 200 mg 1BD). The first dressing was done after 48 hours, and further dressing was done only when there was soakage.

Discharge from the wound was sent for culture and sensitivity test and then patients treated accordingly. Temperature more than 98.6°F was considered as fever in this study. If a patient had a fever or wound discharge, then the total count was done. Ultrasonography (USG) was done in all cases after 48 hours. If the total count was more than 11,000/mm<sup>3</sup>, then it was considered as wound infection.

Patients having no complaint of fever or wound discharge, then they were discharged after 48 hours with 5 days of oral antibiotic (tablet cefixime 200 mg 1BD); the same for both groups. The patient was not discharged when there were complaints, such as fever and wound discharge. Patients having fever given oral paracetamol (500 mg) as and when required.

Patients having wound discharge were given antibiotics according to culture and sensitivity report and sutures were removed after control of infection. If a patient had no complications,

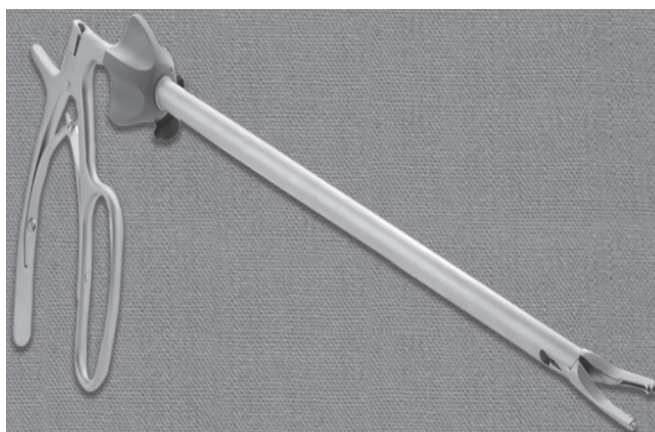

Fig. 1: Polymer clip applicator

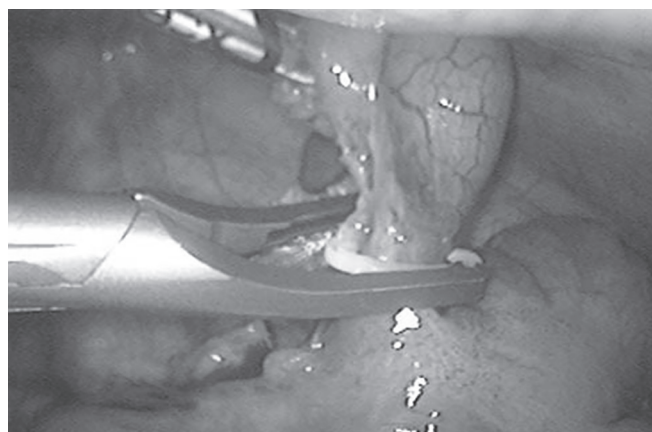


Fig. 2: Polymer clips

then sutures were removed on the seventh postoperative day in the follow-up.

Patients had come for follow-up in the outpatient department after 1 week, 2 weeks, and 1 month of surgery. Ultrasonography was done 1 month after surgery in all cases. In follow-up, the patient was clinically examined for complications, such as wound discharge, swelling over the local site, tenderness on the abdomen, and fever.

### Statistical Analysis

Data analysis was performed using MedCalc version 17.9.5 software. Categorical variables were analyzed with the Chi-squared test and continuous variables were analyzed with "*t*" test. Values were reported as mean  $\pm$  standard deviation or median (extremes) or percentages as and when required. *p* value of less than 0.05 was considered significant.

### RESULTS

A total of 70 patients with laparoscopic appendectomy were included in this study. Adequacy of randomization was evident from the similarity in patient characteristics in both the groups (Table 1). No protocol violations were recorded during the study.

One extra endoloop was used in four cases due to improper closure of appendicular stump. One extra polymer clip was used in

two cases due to improper closure of appendicular stump. These extra used polymer clips and endoloops were counted as wasted polymer clip or endoloop.

In the surgery of 21 patients, time taken for appendicular stump closure was between 10 minutes and 15 minutes and for 14 patients, it was between 15 minutes and 20 minutes in polymer clip group. In the surgery of 12 patients, the time taken for appendicular stump closure was between 10 minutes and 15 minutes, and for 23 patients it was between 15 minutes and 20 minutes in endoloop group. Surgeon had given opinion regarding the ease of application as excellent in 21 patients of polymer clip group and 12 patients of endoloop group.

The surgeon had given opinion regarding the ease of application as good in 14 patients of polymer clip group and 23 patients of endoloop group (Table 2). None of the operating surgeons given a poor opinion for endoloop group or polymer clip group. This measurement (ease of application) is statistically significant in our study (*p* value is 0.032, Table 2).

Three patients were discharged on the fifth postoperative day in the polymer clip group, and 32 patients were discharged on the third postoperative day. Three patients were discharged on the fifth postoperative day, two patients were discharged on the seventh postoperative day, and 30 patients were discharged on the third postoperative day in endoloop group (Table 3). It is not statistically significant in our study (*p* value 0.144, Table 3).

In three cases of endoloop group, there was a serous discharge present from the wound after the first dressing. The daily dressing was done with proper asepsis in all three cases. Culture and sensitivity for wound discharge sent and according to per the sensitivity antibiotics were started. The total count was sent but in all three cases it was below 11,000 mm<sup>3</sup>. In this study, patients having wound discharge and fever in polymer clips and endoloop groups were compared, and it was not statistically significant (*p* value 0.45, Table 4).

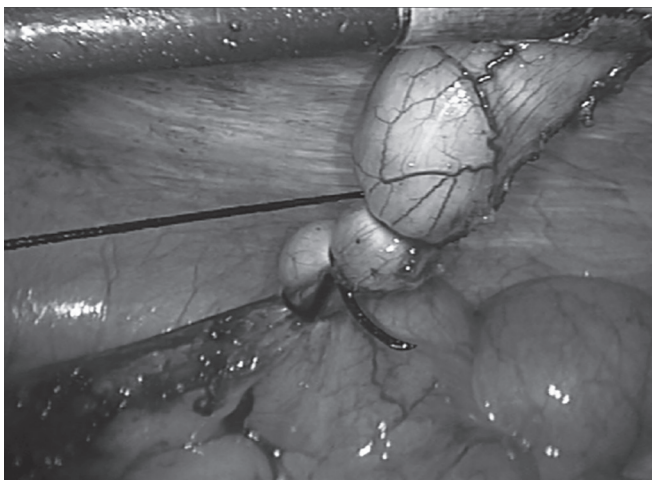


Fig. 3: Endoloop

Table 1: Comparison of present study, study done by Polat and Kinaci and study done by Osman for sex-wise distribution of patients

Different studies	Polymer clip group		Endoloop group		Total
	Male	Female	Male	Female	
In present study	20	15	24	11	70
Polat and Kinaci	23	25	20	24	92
Şimşek	18	12	16	14	60

Table 3: Correlation of present study, study done by Polat and Kinaci and study done by Şimşek for hospital stay

Different studies	Polymer clip group (in days)	Endoloop group (in days)	<i>p</i> value
In present study	3.1 $\pm$ 0.56	3.4 $\pm$ 1.06	0.144
Polat and Kinaci	1.1 $\pm$ 0.6	1.4 $\pm$ 0.9	0.061
Şimşek	2.2 $\pm$ 1.3	1.97 $\pm$ 1.4	>0.05

Table 4: Correlation of present study, study done by Polat and Kinaci and study done by Şimşek for postoperative complications

Different studies	Polymer clip group			Endoloop group			<i>p</i> value
	Wound infection (number of patients)	Fever (number of patients)	Total patients	Wound infection (number of patients)	Fever (number of patients)	Total patients	
In present study	0	3	35	3	2	35	0.45
Polat and Kinaci	1	1	48	4	6	44	0.051
Şimşek	0	0	30	0	0	30	>0.05

Ultrasonography findings of three patients in endoloop group showed minimal collection after 48 hours. In all other patients in endoloop group and polymer clip group, USG was normal. It was not statistically significant. Ultrasonography report was normal in all patients after 1 month in follow-up in endoloop and polymer clip group.

## DISCUSSION

Laparoscopic appendectomy is expected to increase gradually and become the gold standard for the treatment of acute appendicitis because laparoscopic appendectomy has advantages similar to laparoscopic cholecystectomy.

Despite differences in various laparoscopic techniques, the most important concern in laparoscopic appendectomy is the safety of the method used for the closure of appendicular stump. Therefore, there have been many defined methods with some superiority to others. Operative time, hospital stay, and postoperative complications are widely used parameters to compare the benefits of these methods.

In our conducted comparison regarding hospital stay, postoperative complications, and ease of application for appendicular stump closure polymer clip and endoloop group.

In a study by Polat and Kinaci<sup>5</sup> in 2015 comparison done regarding operating time, hospital stay, and postoperative complications in appendicular stump closure by endoloop and polymer clip groups. In a study by Şimşek et al.,<sup>6</sup> in 2014, comparison done regarding operating time, hospital stay, cost, and postoperative complications in appendicular stump closure by endoloop and polymer clip groups.

In our study, polymer clip was found to be a more feasible technique to use for appendicular stump closure compared to endoloop as per surgeon's opinion, and it is statistically significant in our study ( $p$  value is 0.032). The opinion regarding the ease of application in our study was given by operating surgeon, and he was considered the time taken for stump closure, proper covering of appendicular stump and intraoperative handling of endoloop or polymer clips for giving his opinion.

In our study, operating time was considered as the time taken from skeletonization of the appendix to the closure of the appendicular stump. In a study by Polat and Kinaci and a study by Şimşek, operating time was taken from the insertion of the first port to the closure of appendicular stump.

Hospital stay is directly associated with postoperative complications,<sup>7</sup> therefore, we detected similar results in these two parameters. Hospital stay and postoperative complication rates were low in polymer clip group, but it was not statistically significant for both in our study ( $p$  value for hospital stay 0.144 and postoperative complications 0.45).

In a study by Polat and Kinaci<sup>5</sup> in 2015, hospital stay and postoperative complication rates were better in polymer clip group, but it was not statistically significant. However, the  $p$  value was close to 0.05 (0.061 for the hospital stay and 0.051 for postoperative complications). In another study by Şimşek et al.<sup>6</sup> in 2014, hospital

stay and postoperative complication rates were not statistically significant.

As the study conducted on a small number of patients so it needs further evaluation involving a large population. In the present study, cases having intraoperative complicated appendix were not included. So to use polymer clips in such situations requires further study. The availability of polymer clip and its applicator is a major limitation for this study. The availability of a 5 mm telescope is also a limiting factor.

## CONCLUSION

This is a prospective study of 70 patients operated for laparoscopic appendectomy in the Department of General Surgery, Medical College Baroda and Sir Sayajirao Gaekwad General Hospital in the period from October 2016 to October 2017.

Acute appendicitis is more common in men compared with women with a ratio of 1:1.7 (62.8% patients were male). The use of polymer clip is well tolerated in appendicular stump closure. It is more feasible for surgeons to use polymer clip than endoloop to close appendicular stump as per the surgeon's opinion taken after each surgery.

There are early discharge and less chance of postoperative complications with the use of polymer clip in appendicular stump closure compared with endoloop. Polymer clips can be used in place of endoloop in the closure of appendicular stump with more ease and it is beneficial to the patient.

## ETHICAL APPROVAL

The study was approved by the institutional ethics committee.

## REFERENCES

1. Tiwari MM, Reynoso JF, Tsang AW, et al. Comparison of outcomes of laparoscopic appendectomy in management of uncomplicated and complicated appendicitis. *Ann Surg* 2011;254(6):927–932. DOI: 10.1097/SLA.0b013e31822aa8ea.
2. Strzalka M, Matyja M, Rembiesz K. Comparison of the results of laparoscopic appendectomies with application of different techniques for closure of the appendicular stump. *World J Emerg Surg* 2016;11:4. DOI: 10.1186/s13017-015-0060-3.
3. Delibegovic S, Matovic E. Hem-O-lok plastic clips in securing of the base of the appendix during laparoscopic appendectomy. *Surg Endosc* 2009;23(12):2851–2854. DOI: 10.1007/s00464-009-0493-4.
4. Partecke LI, Kessler W, Patrzyk M, et al. Comparison among different closure during laparoscopic appendectomy. *Surg Technol Int* 2011;21:85–91.
5. Polat Y, Kinaci E. Comparison of intra corporeal knot-tying suture and hem-o-lok clip for closure of appendix stump in laparoscopic appendectomy: a retrospective study. *Firat Tip Derg/Firat Med J* 2015;20(2):107–109.
6. Şimşek O, Bilgin IA, Uludag S, et al. Comparison of endo-loop and polymer locking clip in ligating appendiceal stump during laparoscopic appendectomy. *Eur J Endosc Laparosc Surg* 2014;1(3):124–127.
7. Fischer JE, McDermott WV, Holmes CR, et al. *Fischer's mastery of surgery*. 6th ed., Wolters Kluwer; 2012. pp. 280–282.



# Laparoscopic Herniotomy in Female Children: Our Experience in 110 Patients

Chalapathi Gontumukkala<sup>1</sup>, Ramana NG Venkata<sup>2</sup>, Rajeev K Golimi<sup>3</sup>, Veera S Javvadi<sup>4</sup>

## ABSTRACT

**Aim of the study:** To assess the results and complications of laparoscopic herniotomy in female children using percutaneous internal ring suturing (PIRS).

**Materials and methods:** One hundred and ten consecutive female children who were admitted with a unilateral or bilateral inguinal hernia from January 2015 to June 2018 to a medical college referral hospital were included in the study. The technique used was PIRS, using spinal needle 23 gaze and 3.0 prolene. All patients were followed up postoperatively. Babies with recurrent hernias and complicated inguinal hernia were excluded from this study.

**Results:** A total of 110 female children with unilateral or bilateral inguinal hernia were included in the study. Age ranged from 1 month to 15 years with a mean age of 3 years. The clinically unilateral hernia was present in 80 children but the patent internal ring was present on the contralateral side in 25 children and was repaired simultaneously. The bilateral inguinal hernia was present in 30 children. The total number of hernia units was 165. The mean operative time was 15 minutes, ranging from 12 minutes to 20 minutes for unilateral hernia and 15–30 minutes for a bilateral hernia. The mean postoperative stay was 1 day. The follow-up period ranged from 7 days to 2 years. Two babies had hematoma at the internal ring during the procedure, subsided with no postoperative sequel. One child developed hernia on contralateral side, who was operated for contralateral patent ring during repair of an ipsilateral clinical hernia. None other children who were operated for clinical hernia had a recurrence.

**Conclusion:** Laparoscopic herniotomy using the technique of PIRS is safe, quick with minimal postoperative pain, and short hospital stay, and had a very low incidence of recurrence.

**Keywords:** Hernia, Laparoscopy, Percutaneous internal ring suturing.

*World Journal of Laparoscopic Surgery* (2019): 10.5005/jp-journals-10033-1375

## INTRODUCTION

Inguinal hernias in children are due to the protrusion of viscera through persistent process vaginalis. Conventional open therapy includes ligation of the sac at the internal ring. The same basic principle is used in laparoscopy also. Conventional open therapy has a high success rate and acceptable cosmetic results with few complications.<sup>1</sup> The main drawbacks of conventional open therapy are the inability to rule out the contralateral patent processes vaginalis and synchronous hernia. Nowadays, laparoscopy in children is increasingly used to repair inguinal hernias. Several laparoscopic techniques have developed over the past two decades aimed at improving the outcome.<sup>2</sup> This study is to assess the technique, results, complications of percutaneous internal ring suturing (PIRS) with the help of spinal needle 23 gaze, and 3.0 prolene.

## MATERIALS AND METHODS

This was a prospective study conducted in the department of pediatric surgery. A total of 1,100 children with inguinal hernia were admitted for surgery from January 2015 to June 2018 to a medical college referral hospital. Out of the total 1,100 children with inguinal hernia, male children were 990 and female children were 110. These 110 female children with unilateral or bilateral inguinal hernia were chosen for this procedure. Consent was taken from all parents before the procedure. The technique used was PIRS using spinal needle 23 gaze and 3.0 prolene. All patients were followed up postoperatively. Male children with inguinal hernias and female babies with recurrent hernias and complicated inguinal hernias were excluded from this study.

<sup>1-4</sup>Department of Paediatric Surgery, Kurnool Medical College, Kurnool, Andhra Pradesh, India

**Corresponding Author:** Veera S Javvadi, Department of Paediatric Surgery, Kurnool Medical College, Kurnool, Andhra Pradesh, India, Phone: +91 9440439674, e-mail: chalagontu@gmail.com

**How to cite this article:** Gontumukkala C, Venkata RNG, Golimi RK, et al. Laparoscopic Herniotomy in Female Children: Our Experience in 110 Patients. *World J Lap Surg* 2019;12(2):68–72.

**Source of support:** Department of Paediatric Surgery, Kurnool Medical College, Kurnool, Andhra Pradesh, India


**Conflict of interest:** None

## Procedure

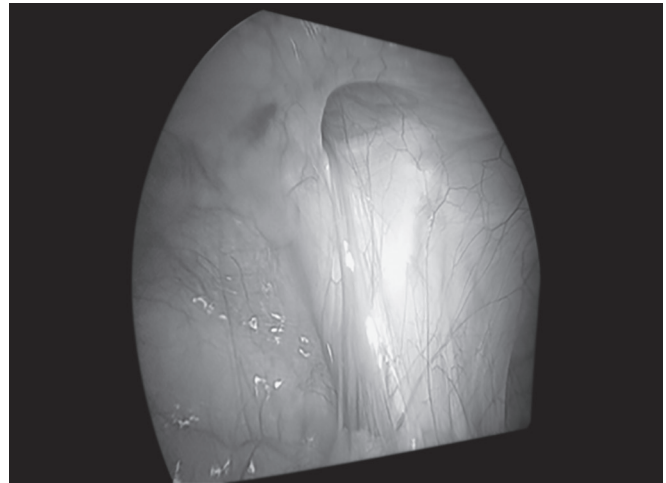
Laparoscopic repair is performed under general anesthesia. The patient is positioned supine, often in the Trendelenburg position. The surgeon stands on the side contralateral to the hernia with the monitor on the ipsilateral side. The instruments used are 5 mm umbilical port for the camera and 3 mm port on the contralateral iliac fossa for manipulation. The abdomen is insufflated through the umbilicus, to a pressure of 8–12 mm Hg depending on the size of the child. Any hernia contents are reduced before beginning the repair of the hernia. With laparoscopy, the contralateral side can be evaluated and bilateral repair performed when necessary.

Following are the steps of the procedure:

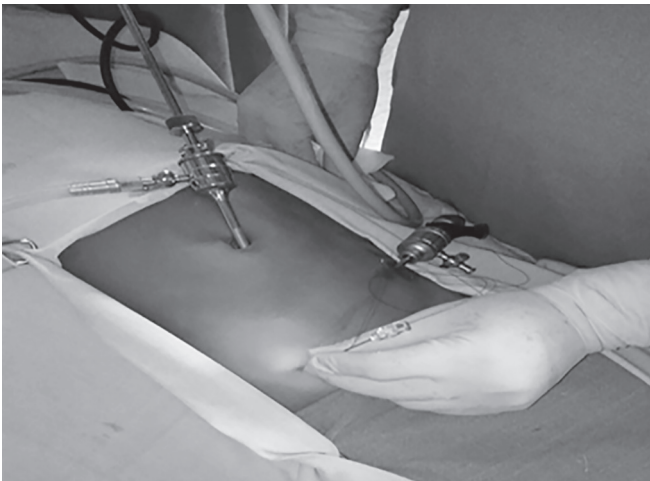
- Introduce the 3.0 prolene suture through the barrel of the 22 or 23 gauge spinal needle (Fig. 1).



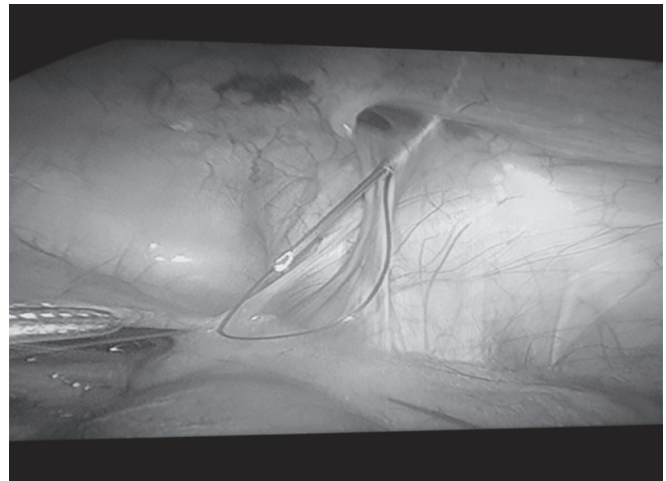
**Fig. 1:** Preloaded prolene into the spinal needle to make a loop



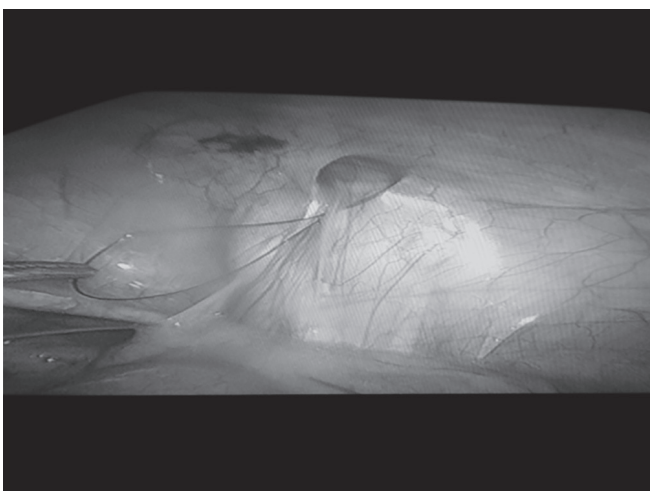
**Fig. 2:** Laparoscopic view of patent internal ring



**Fig. 3:** Insertion of preloaded suture loop into the pre peritoneum from outside




**Fig. 4:** Needle along with suture loop advanced under the peritoneum around the lateral half of ring and entered the peritoneum at midpoint



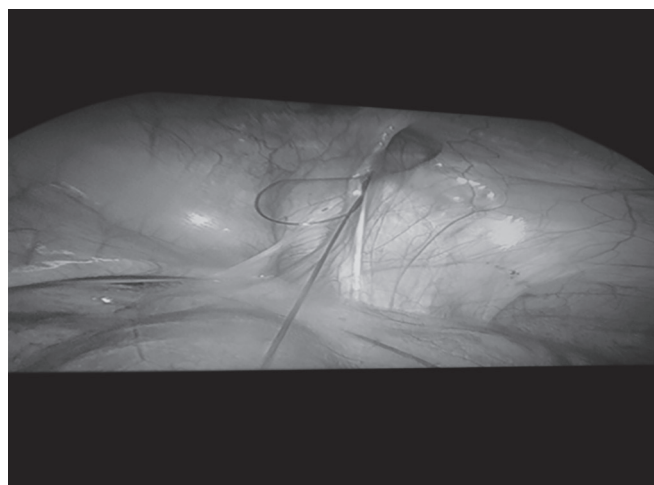
**Fig. 5:** Needle is withdrawn leaving the suture loop *in situ*

- Maintaining both ends of the preloaded suture extraperitoneal, advance the needle under the peritoneum around the lateral half of the internal ring (Figs 2 to 4).
- Enter the peritoneum and advance the suture into the abdominal cavity, creating a loop (Fig. 4).
- Remove the needle, leaving the loop in place (Fig. 5).
- Advance the needle through the same skin puncture site around the medial half of the ring and enter the peritoneum at the same site of previous loop and pass the needle into the loop of previous suture (Fig. 6).
- Pass prolene suture through barrel needle into the loop (Fig. 6).
- Withdraw the needle leaving prolene suture in the loop (Fig. 7).
- Catch the suture end of the loop outside the abdomen and withdraw them together, now the prolene thread is all around the internal ring (Fig. 8).
- The abdomen is desufflated and any air or fluid in the sac is manually expressed with external compression and tie suture extracorporeally (Fig. 9).
- Now the internal ring is reinspected (Figs 10 and 11).

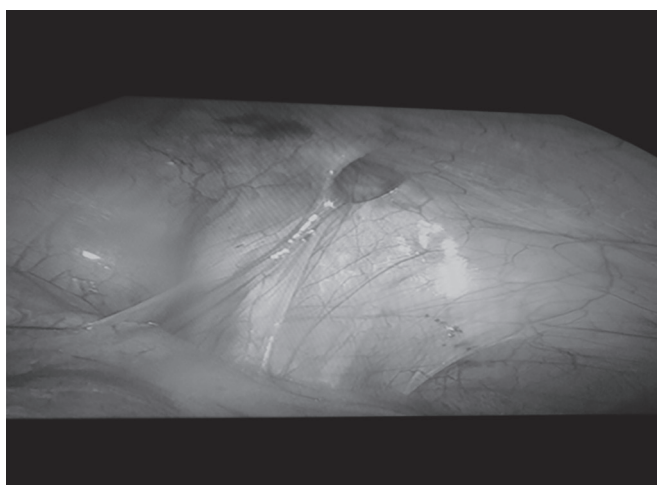




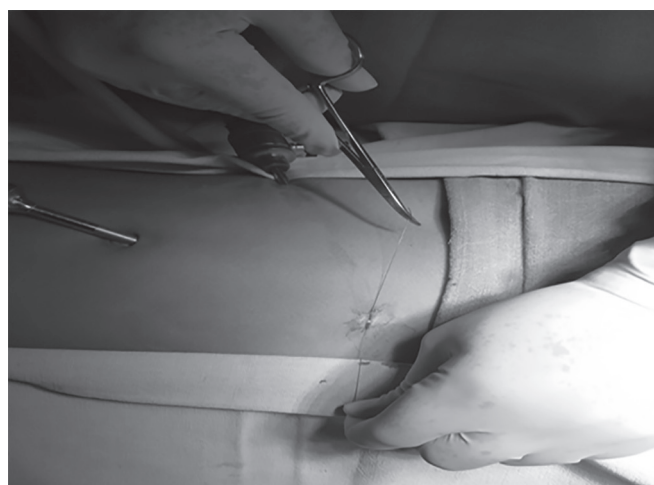
**Fig. 6:** Now the needle reinserted through the same skin puncture site and advanced around the medial half of the ring and entered the peritoneum at the same site of previous loop and pass the needle and thread into the loop of previous suture



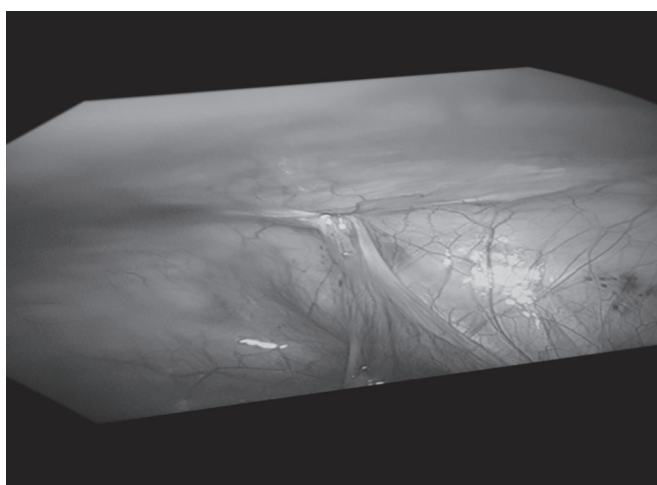
**Fig. 7:** The needle is withdrawn leaving the thread *in situ*



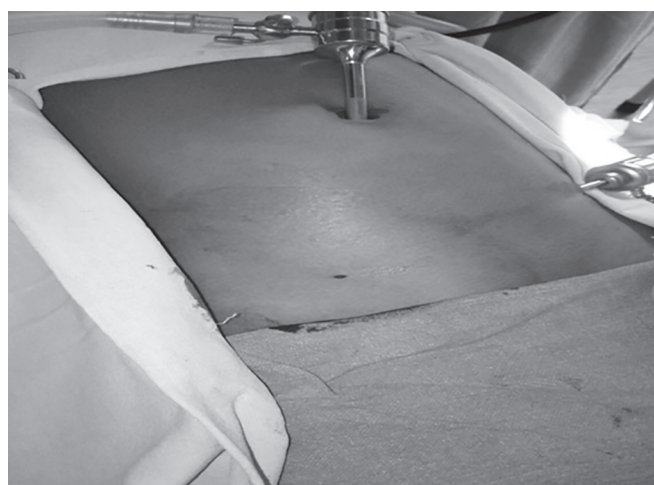**Fig. 8:** Loop is pulled from outside, now the prolene thread is all around the internal ring



**Fig. 9:** Pneumoperitoneum deflated and thread is tied outside the abdomen



**Fig. 10:** The internal ring is reinspected



**Fig. 11:** Appearance after the procedure

## RESULTS

A total of 110 female children with unilateral or bilateral inguinal hernia were included in the study. Age ranging from 1 month to 15 years. The mean age of 3 years. The clinically unilateral hernia was present in 80 children. The right inguinal hernia was seen in 50 and left inguinal hernia was seen in 30 children. During laparoscopy for unilateral hernias, the patent internal ring was present on the contralateral side in 25 children (31.25%) and was repaired simultaneously. The bilateral inguinal hernia was present in 30 children. A total number of hernia units was 165. Preoperative ultrasonography was done in all patients to confirm the diagnosis. The mean operative time was 15 minutes, ranging from 12 to 20 minutes for unilateral hernia and 15 to 30 minutes for a bilateral hernia. The mean postoperative stay was 1 day, ranging from 1 day to 3 days. All patients were followed up postoperatively. The follow-up period ranged from 7 days to 2 years. Two babies had hematoma at the internal ring during the procedure and subsided with no postoperative complications. One child had prolene stitch granuloma during follow-up 2 months postoperatively which was removed. One baby developed hernia on the contralateral side who was operated for the contralateral patent ring during the repair of ipsilateral clinical hernia (0.6%). None other children who were operated for clinical hernia had a recurrence.

## DISCUSSION

The incidence of indirect inguinal hernia in careful controlled population studies is 1–5%<sup>3</sup> with male-to-female ratio is 8:1–10:1. The incidence of bilateral inguinal hernia is greater in female patients in all age groups with a reported incidence of 20–50%.<sup>4</sup> Injury to the reproductive organs during herniotomy in female patients is extremely low so some surgeons advocate bilateral exploration in all female patients.

Laparoscopic repair for inguinal hernias in pediatric patients was first described by El-Gohary.<sup>5</sup> Laparoscopy-assisted extracorporeal suturing was first described by Prasad et al.<sup>6</sup> Lee and Yeung used a specially designed herniotomy hook to place suture extraperitoneal around the internal ring and tie it subcutaneously.<sup>7</sup> Percutaneous internal ring suturing (extracorporeal) was first described by Patkowski et al.<sup>8</sup> They used 18 gauge needle and 2.0 nonabsorbable suture to accomplish the procedure. We have modified this technique that we use 23 gauge spinal needle and 3.0 prolene. The main advantage of laparoscopy is the inspection of contralateral ring and the diagnosis of ipsilateral hernia and repair of both simultaneously.

A contralateral patent process vaginalis was seen in 31.25% of our children in contrast with Rathauer and Rowe et al. who have reported contralateral patent process vaginalis in 50–90% of their patients.<sup>9,10</sup> Two babies had hematoma during the procedure but subsided postoperatively without any complications.

The reported recurrence rates after conventional open herniorrhaphy among children range from 0.8 to 3.8%.<sup>11</sup> The technical errors for the recurrence are (1) failure to find the hernial sac, (2) insufficient low-level ligation of the sac, (3) injury to the floor of the inguinal canal due to operative trauma, (4) failure to close the internal ring in girls, and (5) postoperative wound infection and hematoma.<sup>11,12</sup> All these technical problems for recurrence can be avoided by laparoscopy.<sup>13</sup>

Though laparoscopic herniotomy theoretically provides high ligation of the hernia sac more proximally than does open repair,

higher rates of recurrence have been reported with a laparoscopic procedure. Schier et al. and Chinnaswamy et al. reported the recurrence rate of 3.1–4.4% after intraperitoneal Z-type suture or with simple purse-string suture.<sup>14–16</sup> This is in contrast with our low recurrence rate of 0.6% after laparoscopic PIRS. We had one baby developing clinical hernia (0.6%) who was operated for contralateral patent ring during ipsilateral clinical hernia. The reason for recurrence may be due to a small patent contralateral ring and was technically difficult to encircle ring completely with suture.

Verma et al.<sup>17</sup> operated 150 cases of inguinal hernias and hydroceles using laparoscopic herniotomy performing at the neck of the sac. The proximal part of peritoneum was closed with nonabsorbable suture. The mean operative time was 25 minutes for unilateral and 34.8 minutes for bilateral hernias. They have reported the recurrence rate of 1.33% and a conversion rate of 0.66%.

Spurbeck et al., Kastenberget al., and others<sup>8,18–21</sup> used laparoscopic-assisted extraperitoneal circuit suture and reported the recurrence rate ranging from 0 to 4.3%. Some other authors<sup>22–25</sup> claim the lowest rate of recurrence with a laparoscopic technique involving complete division and then stitching of the hernia sac at an internal inguinal ring. They have reported a recurrence rate ranging from 0% to 1.3% which is comparable with our recurrence rate of 0.6%. The low incidence rate in children with PIRS is due to tying the knot outside the peritoneal cavity more securely after desufflation, when compare with intracorporeal suturing in an insufflated abdomen where the positive pressure is working against the closure of the ring.

## CONCLUSION

Laparoscopic herniotomy using the technique of PIRS using spinal needle 23 gauge is safe, quick with minimal postoperative pain and short hospital stay, had the least rate of complications and associated with a very low incidence of recurrence.

## REFERENCES

1. Kapur P, Caty MG, Glick PL. Pediatric hernias and hydroceles. *Pediatr Clin North Am* 1998;45(4):773–789. DOI: 10.1016/S0031-3955(05)70044-4.
2. Lukong CS. Surgical techniques of laparoscopic inguinal hernia repair in children: a critical appraisal. *J Surg Tech Case Rep* 2012;4(1):1–5. DOI: 10.4103/2006-8808.100343.
3. Cox JA. Inguinal hernia of childhood. *Surg Clin North Am* 1985;65(5):1331–1342. DOI: 10.1016/S0039-6109(16)43742-4.
4. Tackett LD, Breuer CK, Luks FL, et al. Incidence of contralateral inguinal hernia: a prospective analysis. *J Pediatr Surg* 1999;34(5):684–687. DOI: 10.1016/S0022-3468(99)90356-1.
5. El-Gohary MA. Laparoscopic ligation of inguinal hernia in girls. *Pediatr Endosurg Innov Tech* 1997;1(3):185–188. DOI: 10.1089/pei.1997.1.185.
6. Prasad R, Lovvorn HN, Wadie GM, et al. Early experience with needleoscopic inguinal herniorrhaphy in children. *J Pediatr Surg* 2003;38(7):1055–1058. DOI: 10.1016/S0022-3468(03)00191-X.
7. Lee KH, Yeung CK. Laparoscopic surgery in newborns and infants: an update. *HK J Paediatr* 2003;8:327–335.
8. Patkowski D, Czernik J, Chrzan R, et al. Percutaneous internal ring suturing: a simple minimally invasive technique for inguinal hernia repair in children. *J Laparoendosc Adv Surg Tech A* 2006;16(5): 513–517. DOI: 10.1089/lap.2006.16.513.
9. Rathauer F. Historical overview of the bilateral approach to pediatric inguinal hernias. *Am J Surg* 1985;150(5):527–532. DOI: 10.1016/0002-9610(85)90430-1.
10. Rowe MI, Copelson LW, Clatworthy HW. The patent process vaginalis and the inguinal hernia. *J Pediatr Surg* 1969;4(1):102–107. DOI: 10.1016/0022-3468(69)90189-4.

11. Steinau G, Treutner KH, Feeken G, et al. Recurrent inguinal hernias in infants and children. *World J Surg* 1995;19(2):303–306. DOI: 10.1007/BF00308645.
12. Grosfeld JL, Minnick K, Shedd F, et al. Inguinal hernia in children: factors affecting recurrence in 62 cases. *J Pediatr Surg* 1991;26(3):283–287. DOI: 10.1016/0022-3468(91)90503-L.
13. Chan KL, Hui WC, Tam KH. Prospective, randomized, single-center, single-blind comparison of laparoscopic vs open repair of pediatric inguinal hernia. *Surg Endosc* 2005;19(7):927–932. DOI: 10.1007/s00464-004-8224-3.
14. Schier F, Montupet P, Esposito C. Laparoscopic inguinal herniorrhaphy in children: a three-center experience with 933 repairs. *J Pediatr Surg* 2002;37(3):395–397. DOI: 10.1053/jpsu.2002.30842.
15. Chinnaswamy P, Mallabiv V, Jani KV, et al. Laparoscopic inguinal hernia repair in children. *JSLs* 2005;9(4):393–398.
16. Schier F. Laparoscopic inguinal hernia repair - a prospective personal series of 542 children. *J Pediatr Surg* 2006;41(6):1081–1084. DOI: 10.1016/j.jpedsurg.2006.02.028.
17. Verma D, Ram D, Gupta M, et al. Laparoscopic herniotomy-A single centre study of 150 cases. *Am J Clin Exp Med* 2017;5(5):181–185. DOI: 10.11648/j.ajcem.20170505.15.
18. Spurbeck WW, Prasad R, Lobe TE. Two-year experience with minimally invasive herniorrhaphy in children. *Surg Endosc* 2005;19(4):551–553. DOI: 10.1007/s00464-004-8922-x.
19. Kastenbergs Z, Bruzoni M, Dutta S. A modification of the laparoscopic transcuteaneous inguinal hernia repair to achieve transfixation ligature of the hernial sac. *J Pediatr Surg* 2011;46(8):1658–1664. DOI: 10.1016/j.jpedsurg.2011.03.022.
20. Ozgediz D, Roayaie K, Lee H, et al. Subcutaneous endoscopically assisted ligation (SEAL) of the internal ring for repair of inguinal hernias in children: report of a new technique and early results. *Surg Endosc* 2007;21(8):1327–1331. DOI: 10.1007/s00464-007-9202-3.
21. Takehara H, Yakabe S, Kameoka K. Laparoscopic percutaneous extraperitoneal closure for inguinal hernia in children: clinical outcome of 972 repairs done in 3 pediatric surgical institutions. *J Pediatr Surg* 2006;41(12):1999–2003. DOI: 10.1016/j.jpedsurg.2006.08.032.
22. Becmeur F, Philippe P, Lemandat-Schultz A, et al. A continuous series of 96 laparoscopic inguinal hernia repairs in children by a new technique. *Surg Endosc* 2004;18(12):1738–1741. DOI: 10.1007/s00464-004-9008-5.
23. Giseke S, Glass M, Tapadar P, et al. A true laparoscopic herniotomy in children: evaluation of long-term outcome. *J Laparoendosc Adv Surg Tech A* 2010;20(2):191–194. DOI: 10.1089/lap.2009.0069.
24. Wheeler AA, Matz ST, Schmidt S, et al. Laparoscopic inguinal hernia repair in children with transperitoneal division of the hernial sac and proximal purse string closure of peritoneum: our modified new approach. *Eur J Pediatr Surg* 2011;21(2):381–385. DOI: 10.1055/s-0031-1291181.
25. Endo M, Watanabe T, Nakano M, et al. Laparoscopic completely extraperitoneal repair of inguinal hernia in children: a single-institute experience with 1,257 repairs compared with cut-down herniorrhaphy. *Surg Endosc* 2009;23(8):1706–1712. DOI: 10.1007/s00464-008-0300-7.

# Comparative Study of Veress Needle and Visiport in Creating Pneumoperitoneum in Laparoscopic Surgery

Sheela Prince<sup>1</sup>, Packirisamy Kannan<sup>2</sup>, RK Mishra<sup>3</sup>

## ABSTRACT

**Introduction:** In minimal access surgery, the technique of first entry in the human body with the telescope and instruments is called the access technique. Laparoscopic access is of two types: closed and open access.<sup>1,2</sup> Here we are analyzing the merits and demerits of two entry techniques and the incidence of complications in both techniques. Comparison is between the blind technique by using the Veress needle and the undervision technique by using Visiport.

**Aim of study:** To assess, evaluate, and compare the incidence of complications in blind and clear view access techniques in laparoscopic surgery.

**Materials and methods:** A total of 150 cases of laparoscopic surgeries using the Veress needle and 150 cases of laparoscopic surgeries done by Visiport have been reported. (All laparoscopic surgeries were done in the General Surgery Department in Rashid Hospital from January 1, 2015 to December 12, 2015.)

**Result:** In this study of comparison, both techniques were seen to have been associated with their own complications. But Visiport is a safe and faster method of creating pneumoperitoneum, though there was a statistically insignificant major vascular injury. It happened with an inexperienced surgeon.

**Conclusion:** Visiport is a safe and faster method of creating pneumoperitoneum in laparoscopic surgery.

**Keywords:** Laparoscopic access, Pneumoperitoneum, Veress needle, Visiport.

*World Journal of Laparoscopic Surgery* (2019): 10.5005/jp-journals-10033-1368

## INTRODUCTION

In minimal access surgery, the technique of first entry in the human body with the telescope and instruments is called the access technique.<sup>3</sup> It is important to know that 20% of laparoscopic complications are caused at the time of initial access. Developing access skill is one of the important achievements for the surgeons practicing minimal access surgery. First entry access in laparoscopy is of two types: closed and open access.

In the closed technique, a Veress needle is commonly used by minimal access surgeons worldwide but it is a blind technique. Nowadays, an entry technique with optical trocars is used for visual guided access into the abdomen. Here we are analyzing the merits and demerits of two entry techniques and the incidence of complications in both techniques. Comparison is between the blind technique by using the Veress needle and the undervision technique by using Visiport.

## MATERIALS AND METHODS

### Study Area

Rashid Hospital, General Surgery Department.

### Study Population

All the patients who underwent laparoscopic surgery in Rashid Hospital in General Surgery Department from January 1, 2015 to December 12, 2015.

### Sample Size

One hundred fifty Veress needle, blind access technique cases of laparoscopic surgery and 150 Visiport, clear-view access technique cases of laparoscopic surgery.

<sup>1</sup>Department of General Surgery, Zulekha Hospital, Dubai, United Arab Emirates

<sup>2</sup>Department of General Surgery, Rashid Hospital, Dubai, United Arab Emirates

<sup>3</sup>Department of General Surgery, World Laparoscopy Hospital, Gurugram, Haryana, India

**Corresponding Author:** Sheela Prince, Department of General Surgery, Zulekha Hospital, Dubai, United Arab Emirates, Phone: +971 567600373, e-mail: sheelaprinced8@gmail.com

**How to cite this article:** Prince S, Kannan P, Mishra RK. Comparative Study of Veress Needle and Visiport in Creating Pneumoperitoneum in Laparoscopic Surgery. *World J Lap Surg* 2019;12(2):73–75.

**Source of support:** Nil

**Conflict of interest:** None

## Selection Criteria

- Inclusion criteria—all the patients who underwent laparoscopic surgery in General Surgery Department of Rashid Hospital from January 1, 2015 to December 12, 2015, were included.
- Exclusion criteria—patients with more than one abdominal surgeries earlier and medically unfit patients with multiple comorbidities were excluded.

## Data Collection

Record-based, crossover study, collected patients' details from the case file, time out sheets, operation notes, and follow-up files. Details of all variables entered in a particular proforma for data collection.



## Data Analysis

Data obtained from the proforma were entered in the Excel format; the data presented in appropriate charts, tables, graphs, and figures.

## Statistical Procedure

Analysis in which qualitative variables were expressed as mean, standard deviation, and median. Quantitative variables were expressed as proportion. Comparison quantitative data between two groups were analyzed by the independent samples *t* test. Comparison of qualitative variables between two groups was analyzed by the Chi-square test, association A. *p* value <0.05 was considered statistically significant. Data analysis was performed using SPSS version 22.0.

## OBSERVATION AND RESULTS

The average age of the subjects in the Veress needle group was  $33.1 \pm 12.8$  years and that of the Visiport group was  $35.4 \pm 10.6$  years. Both group were comparable according to age.

36.0% of the Veress needle group and 60.7% of the Visiport group were female.

100.0% of the Veress needle group and 98.7% of the Visiport group have no vascular injury.

98.0% of the Veress needle group and 99.3% of the Visiport group have no visceral injury.

96.7% of the Veress needle group and 100% of the Visiport group have no preparational insufflation.

0.7% of the Veress needle group and none of the Visiport group have failure of technique.

0.7% of the Veress needle group and 0.7% of the Visiport group have port site.

Average time required to induce pneumoperitoneum among the Veress needle group was  $3.1 \pm 0.7$  minutes and that of the Visiport group was  $2.1 \pm 0.4$  minutes. The observed difference was statistically significant (*p* < 0.05). Time required to induce pneumoperitoneum among the Veress needle group was significantly greater than the Visiport group.

Average duration of hospital stay among the Veress needle group was  $83.5 \pm 36.1$  hours and that of the Visiport group was  $62.8 \pm 34.3$  hours. The observed difference was statistically significant (*p* < 0.05). Duration of hospital stay among the Veress needle group was significantly greater than the Visiport group.

Average duration of surgery among the Veress needle group was  $56.7 \pm 17.2$  minutes and that of the Visiport group was  $59.6 \pm 26.0$  minutes. The observed difference was not statistically significant (*p* > 0.05). Duration of surgery among the Veress needle group was significantly greater than the Visiport group.

## DISCUSSION

Ever since the first laparoscopy performed by Jacobeus of Sweden in 1925, different techniques, technologists, and evidence-based guidelines have been introduced to eliminate the risk associated with laparoscopic entry, whatever be the method adopted for first port entry into the abdomen.<sup>4</sup>

From studies, it has been proved that in 50% of laparoscopic surgeries, major complications occur prior to the commencement of surgery and a delay in diagnosis of visceral injury will lead to increased morbidity and mortality.<sup>4</sup>

Regardless of the methods used, gaining access to the abdomen and initiating pneumoperitoneum remains a source of

morbidity and mortality with most common complications being visceral and vascular injuries. Over the last three decades, rapid advances have made laparoscopic surgery a well-established entity. However, laparoscopy being relatively new, there are controversies regarding the best method of creating pneumoperitoneum.<sup>5</sup>

To establish pneumoperitoneum, access to the peritoneal cavity can be gained through different ways that include Veress/trocar (blind technique), the open technique (Hassons method), direct trocar insertion, disposable shielded trocars, radially expanding trocars, and the visual entry system.<sup>6</sup> Related to this present study, we have reviewed and compared 37 similar studies related to different access techniques in creating pneumoperitoneum in various laparoscopic surgeries.

Laparoscopic surgery will only continue to expand in terms of procedures, which can be performed using technology. Regardless of the procedure, the first step being induction of pneumoperitoneum; all surgeons need to achieve competence in the technique.<sup>7</sup>

In our study, 150 cases of Veress needle and 150 cases of Visiport were compared and analyzed. This included appendectomy, cholecystectomy, laparoscopic inguinal and ventral hernia repair, laparoscopic sleeve gastrectomy, laparoscopic mini gastric bypass and diagnostic laparoscopy, and laparoscopic closure of perforated duodenal ulcer.

In this study, there were two vascular injuries, both of them happened to the same surgeon who created pneumoperitoneum through the optiview trocar while attempting to do mini gastric bypass. Those two cases were converted to open and vascular surgeon was called in and repaired. This happened to the surgeon who was inexperienced with the technique. The rest of all the Visiport cases were safe and faster in creating pneumoperitoneum during the surgery; there was no statistical significance on comparison of both the techniques. There were three omental injuries with the Veress needle (2%). There was one omental tear among the Visiport group (0.7%). There were five cases of preperitoneal insufflation among the Veress group (3.3%); no preperitoneal insufflation was noted in the Visiport group. There was one failure of technique in the Veress group (0.7%). No failure of technique was noted in the Visiport group. There was one port site hematoma in the Veress needle group (0.07%) and four cases of port site hematoma in the Visiport group (2.7%).

Time required to induce pneumoperitoneum using Veress needle was  $3.1 \pm 0.7$  minutes and that of Visiport was  $2.1 \pm 0.4$  minutes. *p* value is 0.001. The observed difference was statistically significant. Time required to induce pneumoperitoneum among the Veress needle group was significantly greater than the Visiport group.

Duration of surgery: average duration of surgery among Veress needle was  $56 \pm 17.2$  minutes and that of Visiport was  $60 \pm 25.6$  minutes. Observed difference was not statistically significant (*p* > 0.05).

Duration of surgery among Veress needle was significantly greater than Visiport.

In the 5-year study of Lapham et al. from 2001 to 2006 using Visiport, 1,623 out of 1,626 cases were successful in inducing pneumoperitoneum.<sup>8</sup> There were three (0.2%) retroperitoneal vascular injuries. In the study of Dunne et al., there was visceral injury with the Veress needle (0.1%) but there was no vascular injury with the Veress needle technique.<sup>7</sup>

In Struge et al.'s 4-year study, there were only (0.3%) complications with Visiport in creating pneumoperitoneum.



In Berch et al.'s 4-year study in optical trocar, there were no trocar-related bowel or vascular injuries with Visiport.

## DEMOGRAPHIC DATA OF PATIENTS AND RESULTS

Demographic data	Veress needle	Visiport	
	VN group	Optical trocar	p value
Number of cases	150	150	
Mean age (years)	33.1 ± 10.4	35.4 ± 10.6	0.09
Male/female	96/54	59/91	0.001
Time for creating pneumoperitoneum (minutes)	3.1 ± 0.7	2.1 ± 0.4	0.001
Duration of surgery (minutes)	56.7 ± 17.2	60 ± 25.6	0.204
Duration of hospital stay (hours)	83.5 ± 36.1	62.8 ± 34.3	0.001
Aortic injury	0	1	0.365
IVC injury	0	1	0.365
Visceral injury			
Omental injury	3	0	0.109
Omental tear	0	1	
Preperitoneal insufflation	5	0	0.024
Failure of technique	1	0	0.317
Port-site hematoma	1	4	0.176
Gas embolism	0	0	

## COMPLICATIONS

Complications	Veress needle (150) (%)	Visiport (150) (%)	Total (%)
Vascular injuries	0.0	0.3	0.3
Visceral injuries	2	0.7	1.3
Preperitoneal insufflation	3.3	0.0	1.7
Failure of technique	0.7	0.0	0.3
Port-site hematoma	0.7	2.7	1.7

## Hospital Stay

Average duration of hospital stay among the Veress needle group was 83.3 ± 36.1 hours and that of the Visiport group was 62.8 ± 34.3 hours. The observed difference was statistically significant ( $p < 0.05$ ). Duration of hospital stay among the Veress needle group was significantly greater than the Visiport group. This difference is due to the difference in cases; most of the cases under the Veress group were infective cases like appendicitis with perforation, collection, abscess formation, and acute cholecystitis, blunt abdominal trauma cases for diagnostic laparoscopy, and all these needed more hospital stay. However, those under Visiport were bariatric surgery and hernia cases; these were all clean cases and needed less duration stay in the hospital.

## CONCLUSION

In this study of comparison, both techniques were seemed to have been associated with their own complications. But Visiport is a safe and faster method of creating pneumoperitoneum, though there was statistically insignificant major vascular injury. It happened with an inexperienced surgeon. There is no strong evidence of superiority of one technique over the other.

Even though both techniques are associated with potential danger of perforating injuries on inserting the first trocar, the undervision technique allows early recognition of injuries and immediate repair. No single technique and instrument has been accepted as the "gold standard" for creating pneumoperitoneum in laparoscopic surgery.<sup>9,10</sup>

Good surgical skills and proper evaluation of the patient are important for safe access in minimal access surgery.<sup>11</sup> The surgeon should be competent in both the techniques. Regardless of the technique that has been chosen, one must abide by the safe general principles of surgery, be meticulous, take your own time, and be highly alert for appearance of signs of injury.

With further research and development, an optimal form of the laparoscopic entry technique for creating and maintaining pneumoperitoneum in laparoscopic surgery needs to be designed.

The surgeons should be familiar with both the techniques and adapt their entry technique to individual patient's circumstances.

## REFERENCES

- Mishra RK. Textbook of practical laparoscopic surgery. 2009. pp. 67–94.
- Opilka MN, Lorenc Z, Starzewski J. Laparoscopic access techniques. J Silesian Med Univ. Poland, ch. 6.
- Akbar M, Khan IA, Naveed D, et al. Comparison of closed and open methods of pneumoperitoneum in laparoscopic cholecystectomy. J Ayub Med Coll 2008;20(2):85–89.
- Kumar R, Hastir A, Bandlish MK, et al. Pneumoperitoneum by direct trocar insertion: safe laparoscopic access. J Evol Med Dent Sci 2015;4(15):2432–2437. DOI: 10.14260/jemds/2015/352.
- Toro A, Mannino M, Cappello G, et al. Comparison of two entry methods for laparoscopic port entry: technical point of view. Diagn Ther Endosc 2012;2012:305428. DOI: 10.1155/2012/305428.
- Vilos GA, Teernamian A, Dempster J, et al. Laparoscopic entry: a review of techniques, technologies and complications. J Obstet Gynaecol Can 2007;29(5):433–465. DOI: 10.1016/S1701-2163(16)35496-2.
- Dunne N, Booth MI, Dehn TCB, et al. Establishing pneumoperitoneum: Veress or Hasson? The debate continues. Ann R Coll Surg Engl 2011;93(1):22–24. DOI: 10.1308/003588411X12851639107557.
- Lapham T, Tarnoff M, Kim J, et al. Five-year experience with a bladed optical trocar in an unsufflated abdomen in bariatric surgery. J Tufts-N Engl Med Cent 2007.
- Berch BR, Torquati A, Lutfi RE, et al. Experience with the optical access trocar for safe and rapid entry in the performance of laparoscopic gastric bypass. Surg Endosc 2006;20(8):1238–1241. DOI: 10.1007/s00464-005-0188-4.
- Access to the Abdomen, Manual of Strategic Decision Making, SAGES Manual page 1–3.
- Hashizume M, Sugimachi K. Needle and trocar injury during laparoscopic surgery in Japan. Surg Endosc 1997;11(12):1198–1201. DOI: 10.1007/s004649900568.

# Laparoscopic Choledochal Cyst Resection with Simplified Common Bile Duct Reconstruction in an Adult Population: A Case Series

Daniel Gomez<sup>1</sup>, Luis F Cabrera<sup>2</sup>, Mauricio Pedraza<sup>3</sup>, Sebastian Sanchez<sup>4</sup>, Jean A Pulido<sup>5</sup>, Ricardo Villarreal<sup>6</sup>, Andres C Mendoza<sup>7</sup>, Daniela Moreno<sup>8</sup>, Natan Zundel<sup>9</sup>

## ABSTRACT

**Introduction:** Choledochal cysts (CC) are rare congenital pathology in adult population. Since 1995, laparoscopic management has been described for this entity. Nevertheless, its management is considered to be a controversial matter due to the augmented risk of associated cholangiocarcinoma.

**Materials and methods:** A retrospective, observational, and descriptive study was conducted considering patients diagnosed with CC who were operated at a hepatobiliary surgery referral center from January 2013 to June 2018. Patients were taken to simplified laparoscopic hepaticojejunostomy with a Roux-en-Y reconstruction. A retrospective analysis of the data obtained is presented.

**Results:** Ten adult patients with CC underwent surgical biliary reconstruction at a mean age of 34.5 years; 75% had Todani type I CC and 25% Todani type IV-B CC. About 50% of the patients were diagnosed via endoscopic retrograde cholangiopancreatography (ERCP) and 50% of them via magnetic resonance cholangiopancreatography. None required re-intervention, no mortality was reported; and the mean hospital stay was 5 days, no patient had postoperative biliary leakage, none was converted to open surgery, and all patients had adequate oral feeding tolerance 2 days postoperative. Long-term follow-up showed no incidence of cholangiocarcinoma after 2-year follow-up.

**Conclusion:** Choledochal cysts in adults is a rare pathology that has a high probability of developing malignancy when not adequately surgically managed and because of secondary bile reflux. These factors make surgical management a critical decision. The simplified laparoscopic approach presented in this paper seems to be an effective and safe alternative to biliary duct reconstructive surgery.

**Keywords:** Biliary duct surgery, Biliary reconstruction, Choledochal cyst, Laparoscopic approach.

*World Journal of Laparoscopic Surgery* (2019): 10.5005/jp-journals-10033-1366

## INTRODUCTION

Choledochal cysts are congenital dilatations of the intrahepatic or extrahepatic biliary ducts.<sup>1-5</sup> They are associated with the development of cholangiocarcinoma. Their incidence predominates in eastern population where it is reported to be approximately 0.00769% higher than western population where the incidence is around 0.000666%. These are estimated numbers; the real incidence of CCs in adult population has not been established so far, since in most cases they are incidentally diagnosed on images or during surgery.<sup>1,2,6</sup>

The first case of laparoscopic approach for CC resection was published by Farello et al. in 1995, since then, different studies have shown that minimally invasive techniques can reduce surgical time, postoperative morbidity, postoperative pain control, and incidence of surgical site infections (SSI). Better results with laparoscopy are reported on patients who have CC Todani type I, II, and IVb compared with the results with open approaches.<sup>2,6,7</sup>

We present our experience with laparoscopic CC resection and simplified bile duct reconstruction in an adult population, analyzing the technical aspects of a novel procedure, postoperative clinical evolution of the patients involved in the study, and the incidence of cholangiocarcinoma in a 2-year postoperative follow-up.

## MATERIALS AND METHODS

### Design

We conducted a retrospective, observational, and descriptive study with a population of 10 adult patients diagnosed with CC who

<sup>1</sup>Department of Advanced Laparoscopic Surgery, Universidad Militar Central, Bogotá, Colombia

<sup>2</sup>Department of General Surgery, Universidad El Bosque, Bogotá, Colombia; Department of General Surgery, Fundacion Santa Fe de Bogotá, Bogotá, Colombia

<sup>3,5,7,8</sup>Department of General Surgery, Universidad El Bosque, Bogotá, Colombia

<sup>4</sup>Department of General Surgery, Pontificia Universidad Javeriana, Bogotá, Colombia

<sup>6</sup>Department of General Surgery, Universidad El Bosque, Bogotá, Colombia; Department of Gastrointestinal Surgery, Los Cobos Medical Center, Bogotá, Colombia

<sup>9</sup>FIU Herbert Wertheim College of Medicine, Miami, Florida, USA; Minimally Invasive and Bariatric Surgery, Fundacion Santa Fe de Bogota University Hospital, Bogotá, Colombia

**Corresponding Author:** Mauricio Pedraza, Department of General Surgery, Universidad El Bosque, Bogotá, Colombia, Phone: +57 301370957, e-mail: mpedraza93@gmail.com

**How to cite this article:** Gomez D, Cabrera LF, Pedraza M, et al. Laparoscopic Choledochal Cyst Resection with Simplified Common Bile Duct Reconstruction in an Adult Population: A Case Series. *World J Lap Surg* 2019;12(2):76-82.

**Source of support:** Nil

**Conflict of interest:** None

underwent laparoscopic CC resection and simplified common bile duct reconstruction at a hepatobiliary referral center in Bogota, Colombia between January 2013 and June 2018.

The following variables were evaluated: age, sex, CC type (according to Todani classification), diagnosis, surgery time, bleeding, biliary leakage, conversion rates, oral feeding tolerance, Intensive care unit (ICU) stay, hospital stay time, need of reintervention, incidence of stenosis, mortality and incidence of cholangiocarcinoma with a postoperative follow-up of at least 2 years.

All patients had a pre-surgical multidisciplinary team assessment performed by gastroenterology and general surgery. Patient consent for laparoscopic choledochal cyst resection and simplified common bile duct reconstruction was obtained before the procedure was started. The study protocol was approved by the ethics committee at our institution and it was implemented in accordance with the Declaration of Helsinki and good clinical practice guidelines.

## INDICATIONS

In order to include patients in this study, the following criteria were evaluated. Only patients over 18 years of age, who had a diagnosis of CC (Todani type I, II, and IVb) (Fig. 1) and Table 1 who were taken to laparoscopic CC resection and simplified common bile duct reconstruction were selected. Patients with the following characteristics were excluded from the study: those diagnosed with CC type III, IVa, V, and Child Pugh B (or higher) hepatic cirrhosis,

**Table 1:** Todani classification of the bile duct cyst

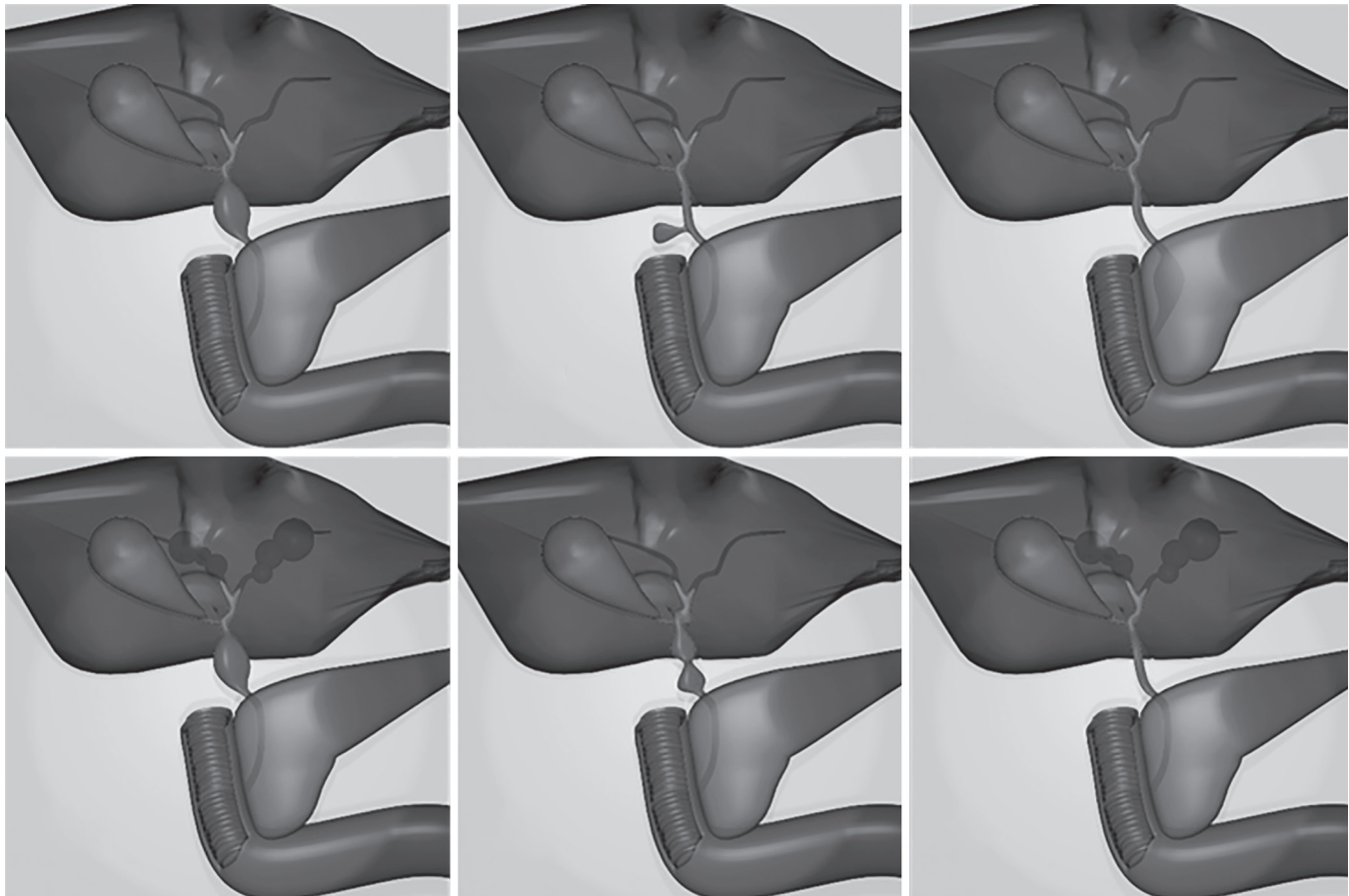
Type	Characteristics
I	Solitary extrahepatic cyst
II	Extrahepatic diverticulum
III	Intraduodenal diverticulum (Choledochocele)
IVa	Extra- and intrahepatic cyst
IVb	Multiple extrahepatic cyst
V	Multiple intrahepatic cyst (Caroli's disease)

extrinsic bile duct compression (e.g., periampullary tumors), or cholangiocarcinoma, patients who had already been treated surgically for CC at another center, patients who were coursing with cholangitis and patients had a contraindication for laparoscopic surgery.

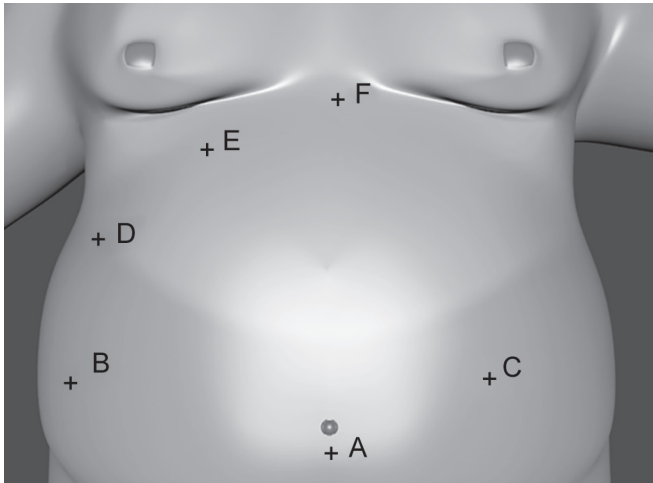
## SURGICAL TECHNIQUE

### Patient Preparation

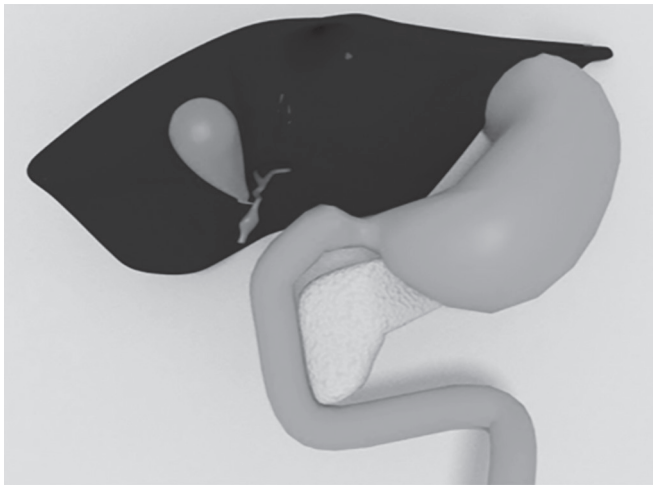
All patients prepared for laparoscopic choledochal cyst resection and simplified common bile duct reconstruction were prepared as if they had an open operation, 8-hour fasting and antibiotic prophylaxis were indicated according to the latest good clinical practice guidelines. Patients and their families were informed of the surgical risk, possible complications, such as bleeding, infection, the need for additional trocars, open conversion, and mortality.



**Fig. 1:** Todani classification in 3D-model by Pulido J



**Figs 2A to F:** Surgical port sites (A) To applied pneumoperitoneum using an open Hasson umbilical approach; (B and C) 12 mm port; (D, E, and F) Are optional ports and could be used at 5 mm port



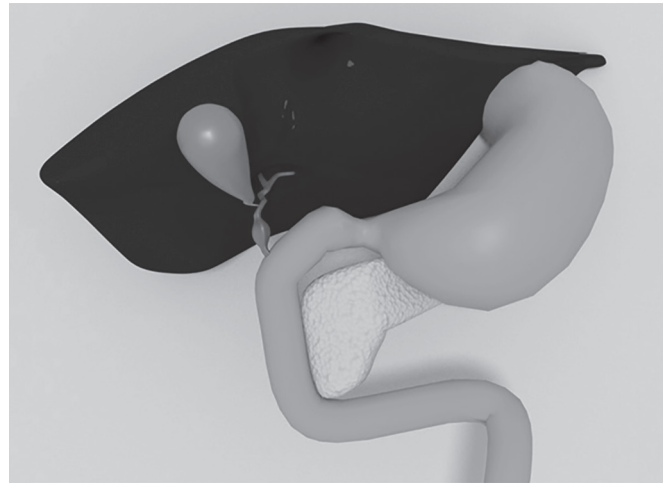
**Fig. 4:** Section of the choledochal cyst—distal portion

### Equipment and Room Set-up

Under general anesthesia, all patients were placed in the supine position with both arms tucked along their sides with their legs spread wide open. The patients were securely strapped to the surgical bed to facilitate maximum tilting and lateral rotation of the surgical table. The surgeon positioned himself between the patient's legs in the French laparoscopy position. The first surgical assistant stood at the surgeon's right-hand side and the second assistant to the left. The scrub nurse stood to the right of the first surgical assistant.

### Laparoscopic Choledochal Cyst Resection and Simplified Common Bile Duct Reconstruction

Using an open umbilical approach, a 12 mm port was introduced into the abdominal cavity in order to create a pneumoperitoneum with carbon dioxide maintaining an intra-abdominal pressure of 14 mm Hg (Fig. 2). Under direct laparoscopic vision, using a 30° lens, 4 additional ports were placed; two 12 mm ports, one in the right flank and the other in the left paramedial zone. The other two 5 mm ports were placed, one in the right upper quadrant, and the other one in the epigastrium. The port site placement for laparoscopic



**Fig. 3:** Bilioenteric anatomy with CC type I

CC resection with simplified common bile duct reconstruction is demonstrated in Figure 3.

The procedure started with full dissection of the structures within the Calot's triangle using an ultrasonic laparoscopic cutter (Harmonic, Ethicon Endo Surgery Inc., Cincinnati, OH, USA) from left to right exposing, cystic duct, artery, and vein. Dissection of intra-abdominal fat continued to expose other structures in order to better identify the common bile duct with the CC, hepatic artery, and portal vein. A Penrose drain was placed around the cyst to assist with retraction. The CC distal portion was sectioned less than 1 cm from the duodenum where the duct size was normal, this was done with an endoscopic mechanical linear cutter suture (The Endo GIA™ reinforced reload with Tri-Staple™ technology) (Fig. 4). After this, a partial laparoscopic cholecystectomy was performed, cutting only the cystic artery and maintaining the integrity of the cystic duct with an abandoned gallbladder. The proximal section of the common bile duct was made with laparoscopic scissors 1 cm away from the CC superior edge. Then, the gallbladder was extracted along with the cystic duct and CC. The extracted pieces were sent to the anatomic and pathological examination.

Longitudinal division of the greater omentum was performed allowing intestinal ascension for anastomosis. The Treitz ligament was identified and at 60–70 cm from it an omega loop was made and ascended, in an antecolic position, to the hepatic duct. A lateral-terminal hepatic-jejunostomy anastomosis was made using a Hepp–Couinaud approach without tension using simple non-continuous sutures with polydioxanone 4-0 (PDS, Ethicon, Inc., Cincinnati, OH, USA) (Fig. 5).

Tissue approximation was performed using a posterior initial suture continuing anteriorly, apply only the necessary number of sutures to prevent leakage ischemia, and stenosis. Around 100–150 cm distal from the anastomosis, a second omega loop was made with the intestinal tube from the duodenum (bile loop) and lateral–lateral jejunum–jejunum anastomosis was made 5 cm from the previous anastomosis using an endoscopic mechanical linear 60 mm suture (Fig. 6).

The subsequent wall was sutured using invaginating non-interrupted stitches with polydioxanone 3-0 (PDS, Ethicon, Inc., Cincinnati, OH, USA). The mesenteric defect was closed using simple non-interrupted sutures with polyester 2-0 (Ethibond, Ethicon, Inc., Cincinnati, OH, USA). The portion of the small intestine left between the two anastomoses was then separated using an endoscopic mechanical linear 60 mm suture leaving a Roux-en-Y configuration (Fig. 7). A 19 French round Blake drain was placed under the liver.



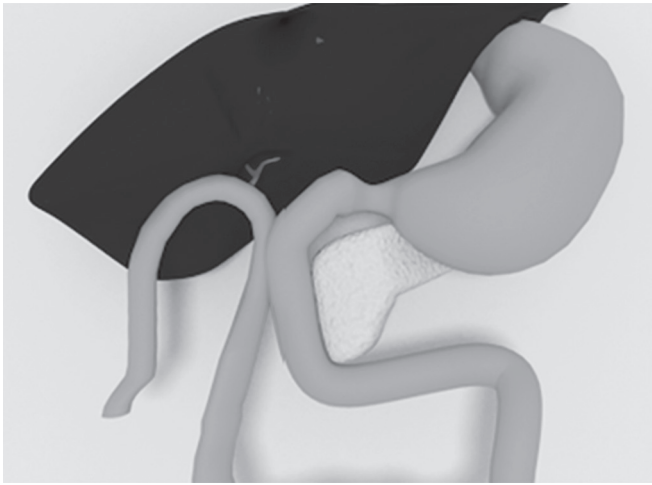


Fig. 5: Laparoscopic hepaticojejunostomy

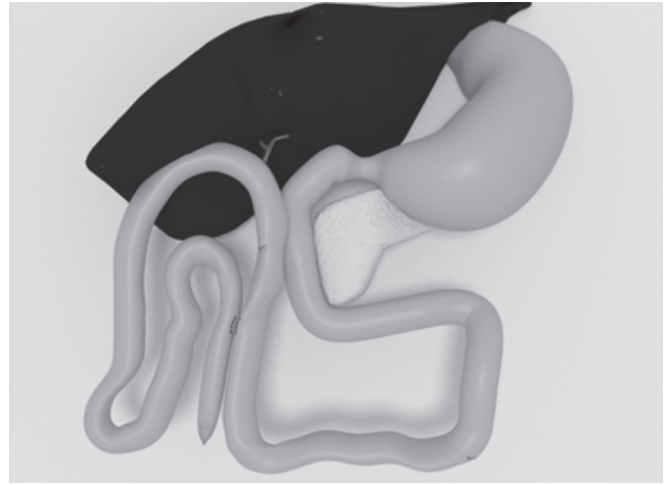


Fig. 6: Lateral-lateral omega jejunojejunostomy

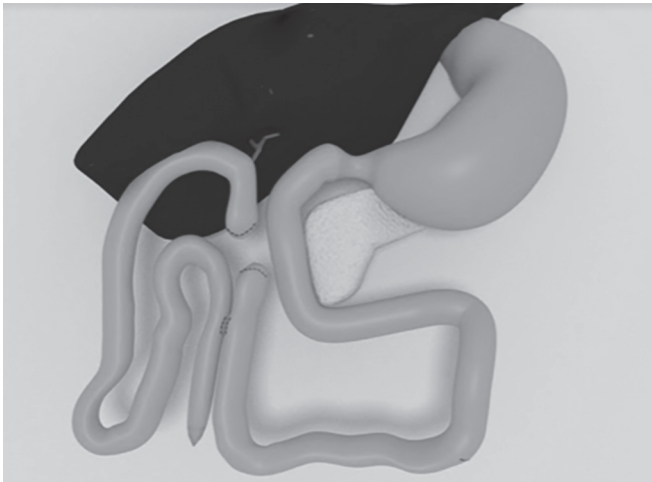


Fig. 7: Simplified hepaticojejunostomy in Roux-en-Y

Please refer to the online video material: Choledochal cyst 69556 Bestoun Ahmed (this material was presented at SAGES annual meeting, Baltimore, 2019).

### Postoperative Care

The operative time was approximately 147 minutes. The patient ambulated on the same day of the procedure and tolerated oral food intake. The peritoneal drain was removed on postoperative day 2; and all the patients were discharged the following day. No patients required ICU or reintervention.

### STATISTICAL ANALYSIS

Being an observational retrospective cohort, a descriptive analysis of the data was performed prospectively in Microsoft Excel databases and analyzed using SPSS1 (Statistical Package for The Social Sciences) V.22.0. Variables were analyzed and median, minimum, maximum values, and percentages were obtained.

## RESULTS

### Patient Characteristics

Between 2013 and 2018, 10 patients with a diagnosis of CC underwent simplified laparoscopic bile duct reconstruction in

**Table 2:** Patient referral characteristics with bile duct injury

Variable	Sub	n = 10 (%)
Age (years, median, SD)		34.5
Gender	Female	100
	Male	0
Choledochal cyst type	IA	75
	IVB	25
ASA classification	ASA 1/2	100
	ASA 3/4	0
Patients with preoperative ERCP or CPRMN	Yes	100
	No	

ASA, the American Society of Anesthesiologists physical status classification

our center. Patients demographics are presented in Table 2. All patients were women, 75% of them presented Todani type I CC and 25% Todani IV-B, without other associated malformations. About 50% of them were diagnosed during endoscopic retrograde cholangiopancreatography (ERCP) and other 50% with a magnetic resonance imaging (MRI). All of them were taken to resection of the common bile duct with a Roux-en-Y hepaticojejunostomy.

### Surgical Outcomes

Average surgery time was 147 minutes; and the average intraoperative bleeding was 15 cc. No intra or postoperative complications were detected. There were no operative site infections, biliary leaks, and no mortality. The mean hospital stay time was 5 days.

One patient required ICU admission for 2 days due to anesthetic complications. There was no need for open conversion of the procedures and all patients had oral feeding and adequate tolerance at 1 day postoperative. Long-term follow-up showed no bile reflux at 2 years following surgery (Table 3).

## DISCUSSION

In 1723, Vater and Ezler described for the first time, the CC; however, it was not until 1977 that Todani described the classification that it is most frequently used nowadays (Fig. 1).<sup>4,5,8,9</sup> The management of this pathology has evolved from a cysto-enterostomy to advanced bilioenteric reconstructions with Roux-en-Y configuration.<sup>3,10</sup>

**Table 3:** Surgical variables and outcomes, with at least 2-year follow-up

Variable	(%), SD
Average surgery time	147 minutes (113–195 minutes)
Average intraoperative bleeding	15–50 cc
Mean hospital stay	5 days
Bile leaks	0
Converted to open surgery	0
Oral feeding and adequate tolerance at POP (days)	2
Mortality	0

POP, postoperative

Prior to 1980's, management for common bile duct consisted on drainage; however, reports of cholangiocarcinoma, recurrent cholangitis, and biliary lithiasis led to a change in the way surgeons managed this disease.<sup>3,4</sup> That is why currently, the management of Todani I, II, and IV CC is similar and involve a complete resection of the defect with posterior bilioenteric reconstruction.<sup>1–3,5,11</sup>

Sastry et al. show the incidence of CC according to the *Todani* classification, being type I the most frequent (69.8%), followed by type IV (23.7%), type V (3.1%), type II (2%) and type III (1.4%).<sup>12</sup> The goal of the surgical management of type IV-A and IV-B CC is to stop or at least slow down the progression of liver damage. The complications of non-operated CC are the result of stasis in which cholangitis, biliary stone formation, recurrent pancreatitis, cirrhosis, and portal hypertension without mentioning the risk for cholangiocarcinoma; for that reason, surgical management in adult population is indicated.<sup>13</sup>

When complete resection of the cyst is not possible (usually in CC type IV-A) complete resection of the extrahepatic biliary tract should be performed in addition to a lobectomy (of the compromised portion of the intrahepatic biliary tree) with posterior biliary-enteric reconstruction. Incomplete resection of the cyst does not seem to be related to perioperative complications although some argue a persistent risk of malignancy.<sup>14,15</sup>

The usefulness of laparoscopy in the surgical management of this type of patients has been questioned due to the complexity of the procedures, the need for precise movements, and the long learning curve necessary to obtain adequate results.<sup>16</sup> However, resection with minimally invasive technique with a Roux-en-Y reconstruction has been shown to be safer when compared to open approach.<sup>16,17</sup>

Some of the advantages of laparoscopic management in these cases are the better visualization of structures, more precise dissections due to the magnification of structures, less postoperative pain, shorter hospital stay time, better esthetic results, decreased bleeding, lower risk SSI and lower incidence of postoperative ileus; being the only negative aspect a prolonged surgical time.<sup>6,18</sup> However, some authors have described an association between the laparoscopic approach and an augmented risk of malignancy due to incomplete CC resections that lead to chronic inflammatory process; they argue that open approach should not be fully abandoned since it is possible to better identify structures even in cases of severe local inflammatory processes and anatomical distortion.<sup>3,11</sup>

Some patients benefit from a two-stage surgical procedure, where during the first surgical time the CC is drained. During the second operative time (after physiological resuscitation in the

ICU and resolution of the acute phase), the resection of the cyst is performed.<sup>1</sup> In our series of cases, complete resection of the CC and bilioenteric reconstruction was performed in one surgical time with a 0% conversion rate and no need of reintervention.

Perhaps the most important aspect of the procedure, besides an adequate resection of the CC, is an adequate biliary-enteric reconstruction where the anastomosis made should allow free biliary flow into the intestine, avoiding as biliary reflux, which is the most important cause malignancy in these patients.<sup>1,3</sup> It can be done with a hepatic-duodenostomy, choledochojejunostomy, or with a Roux-en-Y hepaticojejunostomy.<sup>1,3,6</sup> Being the first and third the most frequent; today there is great controversy regarding which of the two most used procedures is the best as it can be evidenced in the experience of Narayanan et al., who in 2013 published a systematic review in which when comparing 679 cases of patients, 60.7% taken to hepatico-duodenostomy and 39.3% to hepaticojejunostomy, respectively, they reported: a hospital stay time of 4.8 days and 6.1 days, the incidence of biliary leakage 2.1% and 2.94%, the incidence of cholangitis 2.47% and 2.42%, the incidence of anastomotic stenosis 1.21% and 1.47%, the incidence of biliary reflux 5.88% and 0%, incidence of intestinal obstruction due to adhesion syndrome 0% and 5.12%, and the need for re-intervention 1.21% and 2.45%.<sup>19</sup> Most studies demonstrate that there are really no clinically significant differences between the two procedures. However, due to the existing evidence with hepaticoduodenostomy and the development of gastric cancer secondary to biliary reflux, in our study, we only performed bilioenteric reconstruction with a Roux-en-Y hepaticojejunostomy.<sup>1,20</sup> In our case series, there was no biliary leakage, no re-intervention were needed; and our hospital stay time was shorter to the one reported in the medical literature.

It is a common factor among the opinion of experts in the world medical literature on this regard that the laparoscopic approach is a challenging for the surgeon but if performed correctly it is effective and appropriate.<sup>2</sup> The conversion rate to open approach ranges from 0% to 37%, as described by Palanivelu et al. (2008) in a study published in the *Journal of the American College of Surgeons* that report a conversion rate of 8.5%. However, in our series there were no conversions to open surgery.<sup>3</sup> The age of the patient has been shown to be directly related to the need for conversion, is it more frequent in pediatric patients than in adults, which is extrapolated to our results.<sup>2</sup> On average, the length of hospital stay time in minimally invasive management ranges from 3 days to 4.7 days and in the open approach from 5 days to 20.5 days and has a mortality of up to 3.3%, as evidenced in our series.<sup>2,3,6</sup>

Early postoperative complications include pancreatitis, enteric or biliary leakage from the anastomosis, bleeding, SSI, and pancreatic or biliary fistulas. The most frequent delayed complications (after 30 days postoperative) are intrahepatic or extrahepatic bile duct stenosis, lithiasis, malignancy, intestinal obstruction, recurrent pancreatitis, hepatic cirrhosis, and cholangitis.<sup>1,4,8</sup> Postoperative complications in children are rare; however, in adults, they occur between 17% and 40% of cases.<sup>1</sup> the most frequent complication with an incidence of 0% to 20% of cases is an anastomotic leakage; however, in our study, there were no postoperative complications.<sup>3</sup>

Studies that support the use of robots for the surgical management of CC, such as the one reported by Wang et al. who reported their experience in 2016 with a 26-year-old patient who was diagnosed with a type I CC and decided to take him to a robotic Roux-en-Y hepaticojejunostomy with the alimentary and bilioenteric loops in a retrocolic position with satisfactory results in terms of incidence, early or late complications, esthetic results

and SSI, with a surgical time of 480 minutes (longer when compared with our surgical time) and a bleeding of 100 cc (also greater than the one reported in our series).<sup>10</sup> The evidence on robotic surgery in these cases is very limited; however, some authors consider that aspects such as the magnified three-dimensional image, along with more precise movements could represent the difference in the prognosis of the patients.<sup>1,10</sup>

As it was said before, some authors have reported that cholangiocarcinoma may be a secondary to unresected portions CC, with an incidence of up to 30% in the adult population.<sup>26</sup> The global incidence reported in the world medical literature for cholangiocarcinoma is 0.95 per 100,000, being more frequent in patients with CC.<sup>21,22</sup> The risk of malignancy reported for these patients is 0.7% to 28%, this risk increases over time.<sup>2,5,6,8,23</sup> Sastry et al., in one of their studies with a population of 7,880 patients (1,914 under 18 years of age and 3,866 adults), from which 4.59% had histopathological studies revealing malignancy, 70.4% of these patients had cholangiocarcinoma, 23.5% gallbladder carcinoma, and 6.1% other malignancies. The incidence of cholangiocarcinoma in type I CC is 68%; and in type IV CC it is of 21%.<sup>21</sup> The risk of malignancy is high, and it is associated with a global survival of 6 to 21 years. Incidence of malignancy referred by Amid et al., in type IV CC was of 9.2%, type I 7.6%, type II 4.3%, type III 4%, and type V 2.5%.<sup>12</sup> For this reason, it is imperative to make a complete resection of CC and to make a strict postoperative follow-up.

There is still some controversy regarding abandoned CC parts and their risk of malignancy; however, some of the studies on this regard seem to indicate that a complete resection is superior to a partial resection in terms of reducing the risk of malignancy as it is shown by Ten Hove et al. in a meta-analysis published in 2018, where they compare a total of 80 studies and 2,904 patients, with an incidence of 10.7% of cholangiocarcinoma, with an increased risk for patients with type I and IV CC with a statistically significant *p* of 0.016, and with an increased risk for cholangiocarcinoma for patients taken to CC drainage and partial resection with an OR of 3.97, almost four times more than patients taken to complete resection (as it was performed in our series).<sup>1,2,24,25</sup> Mutations in K-ras and p53 genes have been associated with cholangiocarcinoma and a history of common bile duct disease.<sup>1,4,8</sup> Nevertheless, no tumor markers show direct relationship between their serum levels and the presence of cholangiocarcinoma.<sup>26</sup>

Nicholl et al. revealed a direct correlation between patient age and cancer risk: from 0 year to 30 years (0%), from 31 years to 50 years (19%), and from 51 years to 70 years (50%).<sup>27</sup> Surgical management of CC with complete surgical excision during early life tends to decrease the probability of developing cancer cholangiocarcinoma later in life especially in the group of patients with type I CC.<sup>28,29</sup> One study of 56 patients with a previous history of resection three patients progressed to cholangiocarcinoma with a range of 2–19 years after the procedure, showing that a strict follow-up is necessary after the procedure and during a long period of time to ensure an early diagnosis and improve long-term outcomes even in malignant positive patients.<sup>30</sup> Other study that supports this shows that 15 patients out of 214 cases reported were associated with malignancy of the biliary tree; their survival was of 6–21 months after being diagnosed, poor prognosis was associated with late.<sup>31</sup> Lee et al. in a study of 40 patients diagnosed with cholangiocarcinoma during early stages and had a better prognosis; specifically, the 5-year survival rates of patients with stages Ia, Ib, and IIa cholangiocarcinoma reached 90.4%, 40.0%, and 25.1%, respectively.<sup>32</sup> The main limitation of this study is that

it is an observational retrospective study without randomization and no control group. It is therefore subject to selection bias. In addition, the population size of our study may be too small to draw statistically relevant conclusion, even if it is an infrequent disease in Latin America.

## CONCLUSION

Adult CC are a group of rare entities that lead to high mortality and risk of developing cancer, these make their management critical and necessary. Complete resection of the CC and laparoscopic Roux-en-Y bilioenteric reconstruction is an effective and safe method, although complex and challenging for the surgeon. This simplified laparoscopic approach to bile duct reconstruction with Roux-en-Y anastomosis seems to be an effective and safe alternative for the management of this pathology. Additional research is warranted to assess long-term results in a larger series.

## ACKNOWLEDGMENTS

The authors are pleased to acknowledge Dr Ximena Alvira who provided clinical feedback and assistance in preparing the manuscript for submission. Dr Ernest Njeru provided quality English translation.

## REFERENCES

- Soares KC, Arnaoutakis DJ, Kamel I, et al. Choledochal cysts: presentation, clinical differentiation, and management. *J Am Coll Surg* 2014;219(6):1167–1180. DOI: 10.1016/j.jamcollsurg.2014.04.023.
- Hasan A, Nuha Y, Basil A. Laparoscopic resection of type I choledochal cyst in an adult and Roux-en-Y hepaticojejunostomy: a case report and literature review. *Surg Laparosc Endosc Percutan Tech* 2006;16(6):439–444. DOI: 10.1097/01.sle.0000213768.70923.99.
- Palanivelu C, Rangarajan M, Parthasarathi R, et al. Laparoscopic management of choledochal cysts: technique and outcomes – a retrospective study of 35 patients from a tertiary center. *J Am Coll Surg* 2008;207(6):839–846. DOI: 10.1016/j.jamcollsurg.2008.08.004.
- Edil BH, Olino K, Cameron JL. The current management of choledochal cysts. *Adv Surg* 2009;43:221–232. DOI: 10.1016/j.yasu.2009.02.007.
- Tadokoro H, Takase M. Recent advances in choledochal cysts. *OJ Gas* 2012;2(4):145–154. DOI: 10.4236/ojgas.2012.24029.
- Ahmed B, Sharma P, Leaphart CL. Laparoscopic resection of choledochal cyst with Roux-en-Y hepaticojejunostomy: a case report and review of the literature. *Surg Endosc* 2017;31(8):3370–3375. DOI: 10.1007/s00464-016-5346-3.
- Crespo G, Garcia M, Marqués E, et al. Lesiones quísticas del conducto cístico (lesiones tipo VI). *Rev Esp Enferm Dig* 2017;109(5):373.
- Soares KC, Goldstein SD, Ghaseb MA, et al. Pediatric choledochal cysts: diagnosis and current management. *Pediatr Surg Int* 2017;33(6):637–650. DOI: 10.1007/s00383-017-4083-6.
- Manoj Kumar GP, Rajagopalan B. Choledochal cyst. *Med J Armed Forces India* 2012;68(3):296–298. DOI: 10.1016/j.mjafi.2012.04.011.
- Wang S-E, Chen S-C, Shyr B-U, et al. Robotic assisted excision of type I choledochal cyst with Roux-en-Y hepaticojejunostomy reconstruction. *Hepatobiliary Surg Nutr* 2017;6(6):397–400. DOI: 10.21037/hbsn.2017.01.15.
- Stringer M. Laparoscopic management of choledochal cysts: is a keyhole view missing the big picture? *Pediatr Surg Int* 2017;33(6):651–655. DOI: 10.1007/s00383-017-4089-0.
- Sastry AV, Abbadessa B, Wayne MG, et al. What is the incidence of biliary carcinoma in choledochal cysts, when do they develop, and how should it affect management? *World J Surg* 2015;39(2):487–492. DOI: 10.1007/s00268-014-2831-5.
- Chaturvedi A, Singh J, Rastogi V. Case report: cholangiocarcinoma in a choledochal cyst. *Indian J Radiology & Imaging* 2008;18(3):236–238. DOI: 10.4103/0971-3026.41836.

14. Congo K, Lopes MF, Oliveira PH, et al. Outcomes of choledochal cysts with or without intrahepatic involvement in children after extrahepatic cyst excision and Roux en Y hepaticojejunostomy. *Ann Hepatol* 2012;11(4):536–543. DOI: 10.1016/S1665-2681(19)31468-1.
15. Shimamura K, Kurosaki S, Sato D, et al. Intrahepatic cholangiocarcinoma arising 34 years after excision of a type IV – a congenital choledochal cyst: report of a case. *Surg Today* 2009;39(3):247–251.
16. Tang Y, Li F, He G. Comparison of single-incision and conventional laparoscopic cyst excision and Roux en Y hepaticojejunostomy for children with choledochal cyst. *Indian J Surg* 2016;78(4):259–264. DOI: 10.1007/s12262-015-1348-y.
17. Urushihara N, Fukumoto K, Fukuzawa H, et al. Hepaticojejunostomy and intrahepatic cystojejunostomy for type IV – A choledochal cyst. *J Pediatr Surg* 2007;42(10):1753–1756. DOI: 10.1016/j.jpedsurg.2007.06.012.
18. Lee H, Hirose S, Bratton B, et al. Initial experience with complex laparoscopic biliary surgery in children: biliary atresia and choledochal cyst. *J Pediatr Surg* 2004;39(6):804–807. DOI: 10.1016/j.jpedsurg.2004.02.018; discussion 804–7.
19. Narayanan SK, Chen Y, Narasimhan KL, et al. Hepaticoduodenostomy versus hepaticojejunostomy after resection of choledochal cyst: a systematic review and meta-analysis. *J Pediatr Surg* 2013;48(11):2336–2342. DOI: 10.1016/j.jpedsurg.2013.07.020.
20. Madadi-Sanjani O, Petersen C, Ure B. Minimally invasive hepatobiliary surgery. *Clin Perinatol* 2017;44(4):805–818. DOI: 10.1016/j.clp.2017.08.004.
21. Madadi-Sanjani O, Wirth TC, Kuebler JF, et al. Choledochal cyst and malignancy: a plea for lifelong follow-up. *Eur J Pediatr Surg* 2017;29(2):143–149. DOI: 10.1055/s-0037-1615275.
22. Drabek J, Keil R, Stovicek J, et al. The role of endoscopic retrograde cholangiopancreatography in choledochal cysts and/or abnormal pancreatobiliary junction in children. *Prz Gastroenterol* 2017;12(4):303–309. DOI: 10.5114/pg.2017.72107.
23. Ten Hove A, de Meijer VE, Hulscher JBF, et al. Meta-analysis of risk of developing malignancy in congenital choledochal malformation. *Br J Surg* 2018;105(5):482–490. DOI: 10.1002/bjs.10798.
24. Lal R, Agarwal S, Shivhare R, et al. Type IV-a choledochal cysts: a challenge. *J Hepatobiliary Pancreat Surg* 2005;12(2):129–134. DOI: 10.1007/s00534-004-0960-1.
25. Banks JS, Saigal G, D'Alonzo JM, et al. Choledochal malformations: surgical implications of radiologic findings. *AJR Am J Roentgenol* 2018;210(4):748–760. DOI: 10.2214/AJR.17.18402.
26. Katabi N, Pillarisetty VG, DeMatteo R, et al. Choledochal cysts: a clinicopathologic study of 36 cases with emphasis on the morphologic and the immunohistochemical features of premalignant and malignant alterations. *Hum Pathol* 2014;45(10):2107–2114. DOI: 10.1016/j.humpath.2014.06.016.
27. Nicholl M, Pitt HA, Wolf P, et al. Choledochal cysts in western adults: complexities compared to children. *J Gastrointest Surg* 2004;8(3):245–252. DOI: 10.1016/j.gassur.2003.12.013.
28. Ong J, Campbell W, Taylor MA. Metastatic cholangiocarcinoma following choledochal cyst excision: an unusual cause of abdominal pain in a 35-year-old female. *Ulster Medical Journal* 2013;82(1):21–22.
29. Voyles CR, Smadja C, Shands WC, et al. Carcinoma in choledochal cysts. Age-related incidence. *Arch Surg* 1983;118(8):986–988. DOI: 10.1001/archsurg.1983.01390080088022.
30. Kobayashi S, Asano T, Yamasaki M, et al. Risk of bile duct carcinogenesis after excision of extrahepatic bile ducts in pancreaticobiliary maljunction. *Surgery* 1999;126(5):939–944. DOI: 10.1016/S0039-6060(99)70036-X.
31. He XD, Wang L, Liu W, et al. The risk of carcinogenesis in congenital choledochal cyst patients: An analysis of 214 cases. *Annals of Hepatology* 2014;13(6):819–826. DOI: 10.1016/S1665-2681(19)30985-8.
32. Lee SE, Jang JY, Lee YJ, et al. Choledochal cyst and associated malignant tumors in adults: a multicenter survey in South Korea. *Arch Surg* 2011;146(10):1178–1184. DOI: 10.1001/archsurg.2011.243.



# Danger of Laparoscopic Umbilical Port in Portal Hypertensive Cirrhotic Patient: A Case Report

Suppadech Tunruttanakul<sup>1</sup>, Kotchakorn Verasmith<sup>2</sup>

## ABSTRACT

Laparoscopic surgery has been proved to be safe and better option for Child-Pugh (CP) score class I and II cirrhotic patients. Various challenging laparoscopic surgeries have been applied to this group of patients. This case report was of an obese man, CP class I alcoholic cirrhotic patient with radiological evidence of portal hypertension, inflicted with cecal adenocarcinoma. Laparoscopic right hemicolectomy was planned. First camera port incision was made on infraumbilical position and injured to large paraumbilical collateral, which drained blood from the main portal vein. The patient was survived but suffered from postoperative ascites and postponing definite surgery. The preoperative computed tomography was reviewed and detailed of these collateral vessels. This report aims to raise awareness of this potential complication and reveal the imaging with discussion of avoiding options.

**Keywords:** Cirrhosis, Laparoscopic surgery, Paraumbilical collaterals, Portal hypertension.

*World Journal of Laparoscopic Surgery* (2019): 10.5005/jp-journals-10033-1371

## INTRODUCTION

Liver cirrhosis has been a contraindication for laparoscopic cholecystectomy.<sup>1</sup> However, currently, many high-level evidences have revealed that it is safe and maybe better than open surgery in terms of fewer complications, length of hospital stay, and recovery.<sup>2,3</sup> Nevertheless, these safties are limited only on CP score class I and II cirrhotic patients.<sup>2,3</sup> In the beginning, laparoscopic surgery in cirrhotic patients was mostly limited to cholecystectomies. With more developed in minimally invasive surgical equipment, the procedures have expanded to cover many more challenging surgeries such as gastrectomy,<sup>4</sup> colorectal surgery,<sup>5</sup> splenectomy,<sup>6</sup> etc.

Most of the laparoscopic procedures begin with creating abdominal tunnel for a trocar for the laparoscopic camera, which is usually located around the umbilical area. Majority of studies included an umbilical port in the procedure.<sup>5,7-9</sup> This case report aims to alert surgeons to aware of a potentially serious bleeding complication that can occur from creating an umbilical port in a cirrhotic patient with portal hypertension.

## CLINICAL CASE DESCRIPTION

A 66-year-old male, known-case alcoholic cirrhosis, came to the hospital with clinical constipation and occasional abdominal pain. Colonoscopy was later utilized and detected fungating mass located in the cecal area. Pathologic examination later confirmed adenocarcinoma. Computed tomography was then organized and revealed circumferential, enhancing mass at the cecum. Morphologically liver cirrhosis and portal hypertension (seen collateral vessels) without ascites were also reported in the study. There was no evidence of distant metastasis, and the patient was fit with had only cirrhosis as his underlying disease. Regarding body mass index classification, he was categorized as obesity with body mass index 32.4 (bodyweight 83 kg and height 160 cm). His preoperative blood test results were as followings.

Complete blood count: hemoglobin 8.5 g/dL, white blood counts 4,230/ $\mu$ L, and platelet counts 1,13,000/ $\mu$ L.

<sup>1</sup>Department of Surgery, Sawanpracharak Hospital, Nakhon Sawan, Thailand

<sup>2</sup>Department of Radiology, Sawanpracharak Hospital, Nakhon Sawan, Thailand

**Corresponding Author:** Suppadech Tunruttanakul, Department of Surgery, Sawanpracharak Hospital, Nakhon Sawan, Thailand, Phone: +66 897590770, e-mail: sdtaaa@yahoo.com

**How to cite this article:** Tunruttanakul S, Verasmith K. Danger of Laparoscopic Umbilical Port in Portal Hypertensive Cirrhotic Patient: A Case Report. *World J Lap Surg* 2019;12(2):83–85.

**Source of support:** Nil

**Conflict of interest:** None

Liver function test: total protein 8.0 g/dL, albumin 3.6 g/dL, globulin 4.4 g/dL, aspartate aminotransferase 32 U/L, alanine aminotransferase 17 U/L, alkaline phosphatase 69 U/L, total bilirubin 1.02 mg/dL, and direct bilirubin 0.53 mg/dL.

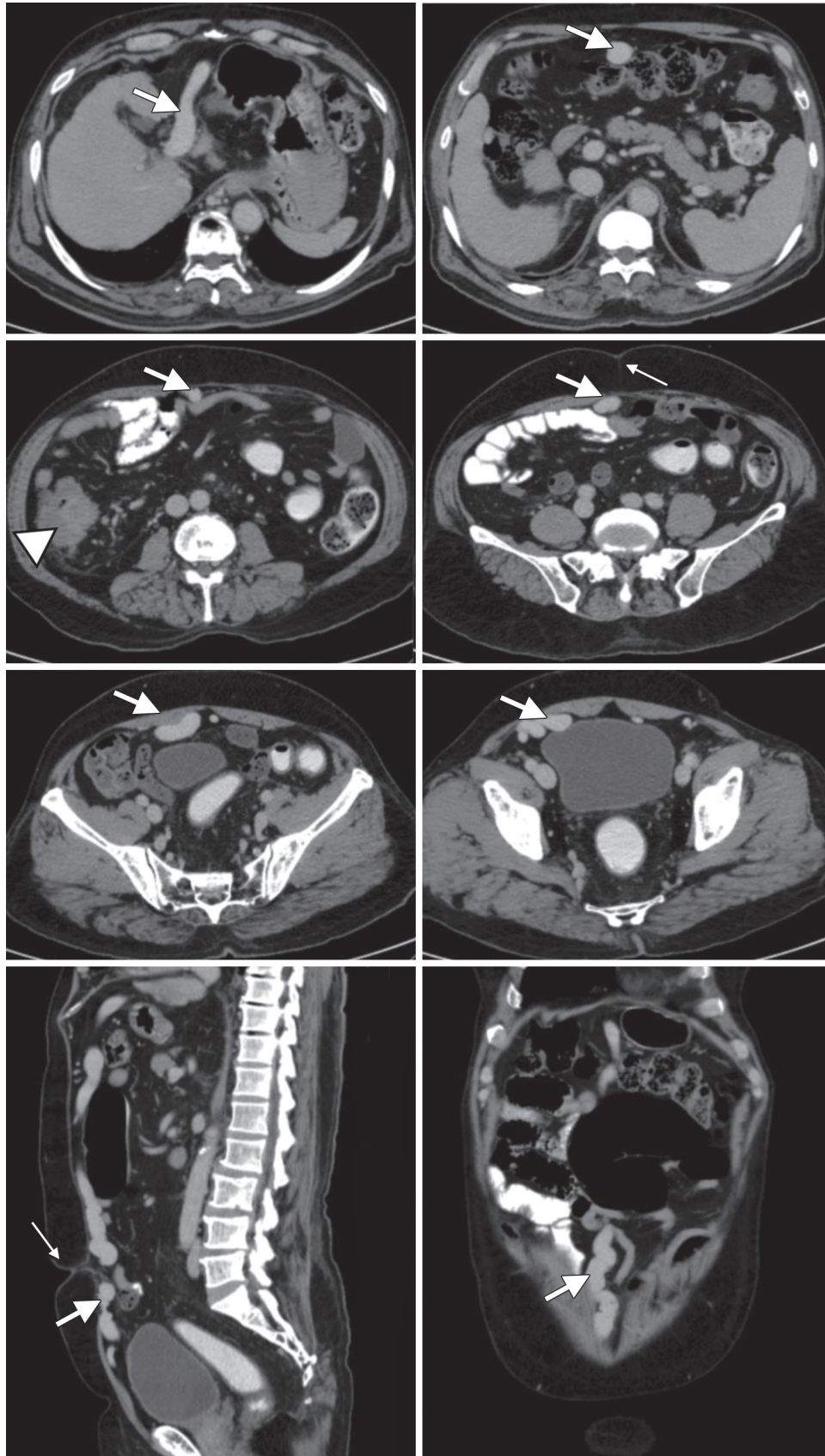
Coagulogram: prothrombin time (PT) 14.8 second with international normalization ratio (INR) 1.21, partial thromboplastin time (PTT) 26.0 with ratio 0.98.

Blood urea nitrogen 8 mg/dL and creatinine 1.09 mg/dL (g = gram, dL = deciliter,  $\mu$ L = microliter, U/L = international unit per liter and mg = milligram).

According to the patient's blood tests, most of the results were normal except slight thrombocytopenia, which can reflect having portal hypertension. Child–Pugh score was calculated, and the score was five (no ascites and hepatic encephalopathy), which categorized the patient as CP class I liver cirrhosis.

It can be summarized that the patient was inflicted resectable cecal cancer with CP class I alcoholic liver cirrhosis with portal hypertension. Surgical treatment was then planned laparoscopically.

Preoperatively, only some packed red cell was prepared, and prophylactic antibiotics were given. General anesthesia with some monitoring was applied without any concern. Umbilical incision was made on infraumbilical location, around one centimeter (cm) in length with open technique under direct vision. After peritoneum



**Fig. 1:** The patient's computed tomography shown: Atrophic change of liver with nodular surface suggests cirrhosis. Dilated tortuous recanalized paraumbilical vein along midline of anterior abdomen (thick arrow), draining from left portal vein into bilateral inferior epigastric vessels. Tumor (arrow head) and umbilicus (thin arrow) were also demonstrated. Esophageal varices are also noted

entered, a large amount of blood was gushed out. Stop bleeding was attempted through the 1 cm wound, but was unsuccessful due to small incision, blood rapidly obscuring surgical field and patient's thick abdominal wall. The incision was then extended to around 5 cm, the bleeding vessel was identified as around 1.2 cm vein just above the layer of peritoneum and then controlled with suture-ligation. Patient's conditions at that time were unstable with hypotension, and volume of blood loss was around one liter. The procedure was then terminated, and the patient was transferred to be resuscitated in the intensive care unit. Postoperatively, the patient has gradually improved with medical controlled ascites. The second operation was planned after the patient has recovered.

Preoperative computed tomography was later reviewed (Fig. 1) and shown the large collateral vessel beneath the anterior abdominal wall, which ran from the hilar area of the liver through the falciform ligament to anterior abdominal wall, ran down to locate under the umbilicus. Size of the vessel at the injured location was around 1.5 cm.

## DISCUSSION

Laparoscopic procedures were proved to be safe and beneficial in cirrhosis CP class I and II patients with less blood loss, shorter hospital stay, and earlier recovery.<sup>2,3</sup> More challenging laparoscopic procedures were also utilized in these patients with acceptable outcomes.<sup>4-6</sup> Most of the literature didn't report regarding portal hypertensive status. However, laparoscopic splenectomy, which is indicated in hypersplenism as the result of portal hypertension, was reflected in the application of laparoscopic surgery in these patients.<sup>6</sup> Although appealing outcome, compared to noncirrhotic studies, the morbidity of the procedures was still higher.<sup>10</sup>

Caution in placing the umbilical port was recommended by Earl TM and Chapman WC in textbook of hepatobiliary surgery.<sup>11</sup> To avoid collateral vessel, there was also a recommendation to choose an infraumbilical incision rather than a supraumbilical location.<sup>12</sup> Our case report revealed that even infraumbilical incision might not be able to avoid anterior abdominal collateral vessels. The incidence of paraumbilical vein and abdominal wall veins collaterals, which drain into the superior or inferior epigastric veins, was around 43% in portal hypertensive patients.<sup>13</sup> Even though, to our knowledge, the subset incidence of these collaterals, which drain into inferior epigastric veins that cause risk of injury from infraumbilical incision, is still unknown. The collateral vessel diameter can be very large, such as our case, and inflicts massive rapid loss of blood. In order to prevent air leakage around laparoscopic port during intra-abdominal gas inflation, surgeons trend to create as much small incision as possible. However, in the unexpected bleeding event, this small incision can prevent adequate visualization and causes delaying hemostatic control, especially in the thick abdominal wall. Volume of blood gushing worsens the aforementioned situation by obscuring an operative field. Preventive measures should be the best way for this occurrence that would be:

- Place the other ports first and place the umbilical port under direct vision.<sup>11</sup>
- Completely avoid the midline of umbilical area.<sup>14</sup>

- Reviewing of preoperative imaging to search for a collateral vessel such as our case. However, CT scan was not routinely utilized especially in laparoscopic cholecystectomy cases.

## CONCLUSION

Although various laparoscopic surgeries are recently supported in CP class I and II cirrhotic patients. However, these groups of patients still possess a higher chance of procedure-related complication. Collateral vessels secondary to portal hypertension can cause serious major bleeding from creating an umbilical port that should be aware.

## REFERENCES

1. Yerdel MA, Tsuge H, Mimura H, et al. Laparoscopic cholecystectomy in cirrhotic patients: expanding indications. *Surg Laparosc Endosc* 1993;3(3):180-183.
2. de Goede B, Klitsie PJ, Hagen SM, et al. Meta-analysis of laparoscopic versus open cholecystectomy for patients with liver cirrhosis and symptomatic cholelithiasis. *Br J Surg* 2013;100(2):209-216. DOI: 10.1002/bjs.8911.
3. Laurence JM, Tran PD, Richardson AJ, et al. Laparoscopic or open cholecystectomy in cirrhosis: a systematic review of outcomes and meta-analysis of randomized trials. *HPB* 2012;14(3):153-161. DOI: 10.1111/j.1477-2574.2011.00425.x.
4. Kim DJ, Park CH, Kim W, et al. Safety of laparoscopic radical gastrectomy in gastric cancer patients with liver cirrhosis. *Surg Endosc* 2017;31(10):3898-3904. DOI: 10.1007/s00464-017-5420-5.
5. Zhou S, Zhu H, Li Z, et al. Safety of laparoscopic resection for colorectal cancer in patients with liver cirrhosis: a retrospective cohort study. *Int J Surg* 2018;55:110-116. DOI: 10.1016/j.ijsu.2018.05.730.
6. Zhan XL, Ji Y, Wang YD. Laparoscopic splenectomy for hypersplenism secondary to liver cirrhosis and portal hypertension. *World J Gastroenterol* 2014;20(19):5794-5800. DOI: 10.3748/wjg.v20.i19.5794.
7. El-Awadi S, El-Nakeeb A, Youssef T, et al. Laparoscopic versus open cholecystectomy in cirrhotic patients: a prospective randomized study. *Int J Surg* 2009;7(1):66-69. DOI: 10.1016/j.ijsu.2008.10.013.
8. Hamad MA, Thabet M, Badawy A, et al. Laparoscopic versus open cholecystectomy in patients with liver cirrhosis: a prospective, randomized study. *J Laparoendosc Adv Surg Tech A* 2010;20(5):405-409. DOI: 10.1089/lap.2009.0476.
9. Ji W, Li LT, Wang ZM, et al. A randomized controlled trial of laparoscopic versus open cholecystectomy in patients with cirrhotic portal hypertension. *World J Gastroenterol* 2005;11(16):2513-2517. DOI: 10.3748/wjg.v11.i16.2513.
10. Puggioni A, Wong LL. A metaanalysis of laparoscopic cholecystectomy in patients with cirrhosis. *J Am Coll Surg* 2003;197(6):921-926. DOI: 10.1016/j.jamcollsurg.2003.08.011.
11. Earl TM, Chapman WC. Nonhepatic surgery in the cirrhotic patient. In: Jarnagin W, ed. *Blumgart's surgery of the liver, biliary tract and pancreas*. 2, 6th ed., Elsevier; 2017. pp. 1161-1167.
12. Nguyen KT, Kitisin K, Steel J, et al. Cirrhosis is not a contraindication to laparoscopic cholecystectomy: results and practical recommendations. *HPB (Oxford)* 2011;13(3):192-197. DOI: 10.1111/j.1477-2574.2010.00270.x.
13. Moubarak E, Bouvier A, Boursier J, et al. Portosystemic collateral vessels in liver cirrhosis: a three-dimensional MDCT pictorial review. *Abdom Imaging* 2012;37(5):746-766. DOI: 10.1007/s00261-011-9811-0.
14. Palanisamy S, Sabnis SC, Patel ND, et al. Laparoscopic major hepatectomy-technique and outcomes. *J Gastrointest Surg* 2015;19(12):2215-2222. DOI: 10.1007/s11605-015-2933-x.



# Secondary Live Abdominal Ectopic Pregnancy: A Case Report

Priyakshi Chaudhry<sup>1</sup>, Arpita Jaiswal<sup>2</sup>

## ABSTRACT

A 27-year-old primigravida, married for 3 months, was admitted in the All India Institute of Medical Sciences (AIIMS), Delhi, with the diagnosis of live abdominal ectopic pregnancy. She had a history of scanty menstrual flow since 2 months and brownish discharge since 15 days. The patient had a history of normal menses priorly. Urine pregnancy test done was positive. The gestational age of the present pregnancy was 12 weeks. The patient had no complaints of pain in her abdomen, nausea, and vomiting, was doing her daily activity, which included gym and yoga. Per abdomen examination revealed a soft nondistended abdomen. Per vaginam examination showed bulky, anteverted uterus with fullness in right fornix and tenderness in right fornix. Investigations revealed Hb-10.6 g%, ultrasound, and CT scan showed right-sided live abdominal ectopic pregnancy, and the vessels involved were a right uterine artery and a branch from the lower level of T11 vertebral level, fetal pole  $\approx$  12 weeks in Pouch of Douglas (POD). With this case report we highlighted the medical emergency that diagnosed should be managed promptly. Proper preoperative evaluation, use of systemic methotrexate, availability of multidisciplinary surgical team, and proper operative technique like minimal invasive surgery which is invaluable in modern era when incidence of ectopic pregnancy is increasing due to parallel increase in etiological factor-like sexually transmitted diseases and assisted reproductive techniques by early detection with transvaginal ultrasound and CT scan which can reduce maternal mortality and morbidity, offer the couple a more optimistic outlook for subsequent reproductive potential and reduce mental, emotional trauma to the patient.

**Keywords:** Abdominal ectopic, High-risk obstetrics, Laparoscopy.

*World Journal of Laparoscopic Surgery* (2019): 10.5005/jp-journals-10033-1372

## INTRODUCTION

Abdominal pregnancy is defined as pregnancy anywhere within the peritoneal cavity, exclusive of tubal, ovarian, or broad ligament locations.<sup>1</sup> The POD is the most common location of abdominal pregnancy, followed by the mesosalpinx and omentum. However, implantation on other abdominal organs such as the spleen, liver, and appendix has also been reported.<sup>2-4</sup> The maternal mortality rate can be as high as 20%. Abdominal pregnancy is thought to represent around 1–1.5% of all ectopic pregnancies, with an estimated incidence of 1:8,000 to 10,000 pregnancies.

Abdominal pregnancies are either primary or secondary, secondary being the more common type. Secondary abdominal pregnancy almost always follows the early rupture of a tubal ectopic pregnancy into the peritoneal cavity, with the incidence being 1 in 10,000 live births.<sup>5</sup> It usually occurs following an extra uterine tubal or ovarian pregnancy that ruptures and gets reimplanted within the abdomen.

## CASE DESCRIPTION

A 27-year-old primigravida, married for 3 months, was admitted in All India Medical Institute, Delhi, with the diagnosis of live abdominal ectopic pregnancy. She had a history of scanty menstrual flow since 2 months and brownish discharge since 15 days. The patient had a history of normal menses prior. Urine pregnancy test done was positive. The gestational age of the present pregnancy was 12 weeks. The patient had no complaints of pain in her abdomen, nausea, and vomiting was doing her daily activity, which included gym and yoga. On examination, per abdomen examination revealed a soft nondistended abdomen. Per vaginam examination showed bulky, anteverted uterus with fullness in right fornix and tenderness in the right fornix. Investigations revealed Hb-10.6 g%, ultrasound, and CT scan showed right-sided live abdominal ectopic pregnancy, and the vessels involved were a right uterine artery and a branch

<sup>1</sup>Department of Obstetrics and Gynaecology, Palika Maternity Hospital, New Delhi, India

<sup>2</sup>Jawaharlal Nehru Medical College, Sawangi, Maharashtra, India

**Corresponding Author:** Priyakshi Chaudhry, Department of Obstetrics and Gynaecology, Palika Maternity Hospital, New Delhi, India, Phone: +91 9975459078, e-mail: priyakshichaudhry@gmail.com

**How to cite this article:** Chaudhry P, Jaiswal A. Secondary Live Abdominal Ectopic Pregnancy: A Case Report. *World J Lap Surg* 2019;12(2):86–87.

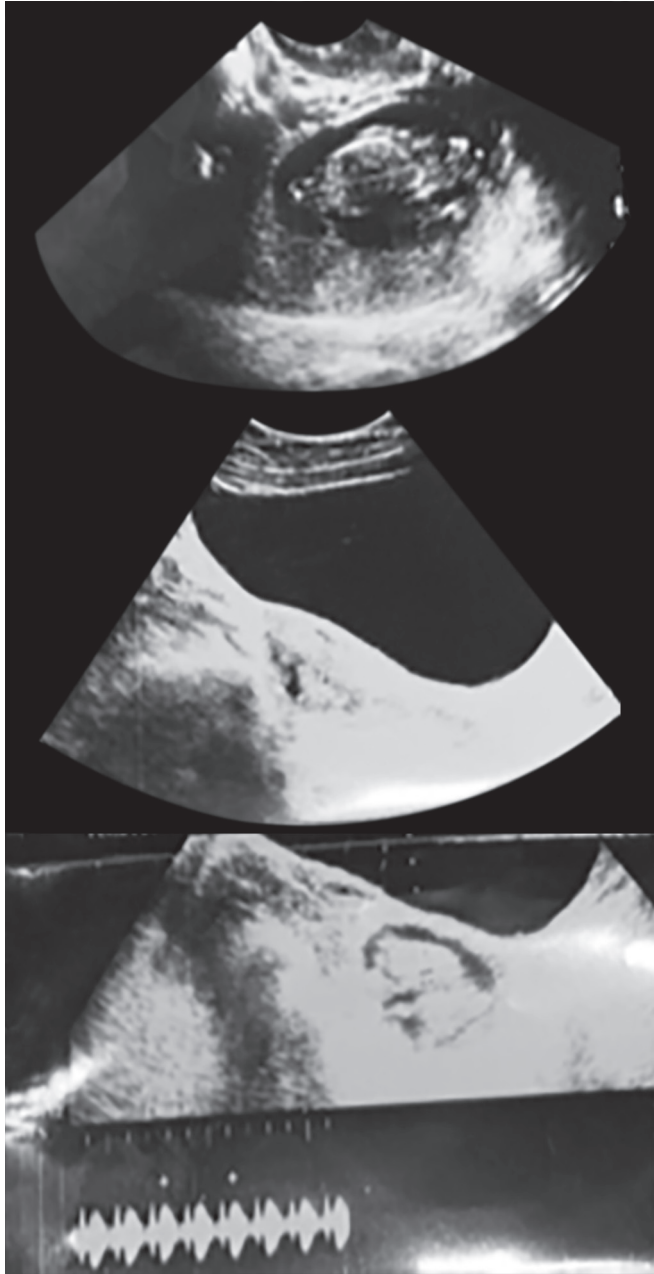
**Source of support:**

**Conflict of interest:**

from the lower level of T11 vertebral level, fetal pole  $\approx$  12 weeks in POD. Patient was taken to OT under general anesthesia, transvaginal ultrasound probe was introduced, and a needle was pushed into the heart of the fetus, and 2.3 mL KCl was introduced and observed for 1 minute, and no fetal cardiac activity was noticed post-procedure. On day 1,  $\beta$  hCG levels were 93,000; according to the formula 85 mg inj methotrexate was given IV. On day 2,  $\beta$  hCG levels were 93,610, on day 3—89,679, and on day 5, levels were—1,36,993, and inj methotrexate was repeated again. Day prior to the procedure, under general anesthesia, 6 F arterial catheter was placed in right femoral artery and selective catheterization of right iliac artery and right uterine artery was done on selective run 500  $\mu$ m PVA was used to embolize the gestational sac and its abnormal vascularity subsequently abnormal vascular, branch from lower level of T11 vertebral level was seen and was also embolized. Laparoscopic removal was planned. There were adhesions between the abdomen and anterior abdominal wall and evidence of secondary right abdominal ectopic pregnancy at the fimbrial end measuring 6  $\times$  6 cm gestational sac. Right-sided salpingectomy was done fimbrial end along with gestational sac was excised, which was



adherent to the lateral pelvic wall and sent for histopathology. Right ureter peristalsis visualized. Homeostasis was achieved. Abdominal drain was introduced. The postoperative period was uneventful (Fig. 1).



**Fig. 1:** Ultrasound films showing the gestational age of the fetus and its location

## DISCUSSION

During the past three decades, the incidence of ectopic pregnancy has increased exponentially from 20,000 to 70,000 cases per year (ectopic pregnancy-United States, 1995; Tait, 1884; Goldner et al.,<sup>6</sup> 1993; NCHS, 1994; Marchbanks et al., 1988).<sup>7</sup> While the case fatality rate has declined significantly. The analysis of different studies

(Fujishita et al.,<sup>8</sup> 1980; Vermesh et al.,<sup>9</sup> 1989; Brumsted et al., 1988<sup>10</sup>). Conclude that laparoscopic management of ectopic pregnancy results in less postoperative adhesions, significantly less blood loss, reduced postoperative analgesia, and reduced cost. Consequently, laparoscopy is the preferred option in the surgical management of ectopic pregnancy. However, in a critically ill patient, laparotomy may continue to have a role because of its swiftness to access the abdomen and securing bleeding vessels. Patients with ectopic pregnancy in the ampulla of the tube are the ideal candidate for salpingostomy. Linear salpingostomy can be tried out but not very successful in the management of a pregnancy lodged in isthmus because lumen is so small that it erodes muscularis. The prognosis of the patient with an ectopic pregnancy is good for those with an early diagnosis. The earlier the diagnosis is made, and treatment is administered higher the likelihood of subsequent fertility.

## CONCLUSION

With this case report, we highlighted, the medical emergency that diagnosed should be managed promptly. Proper preoperative evaluation, use of systemic methotrexate, availability of multidisciplinary surgical team and proper operative technique like minimal invasive surgery is invaluable in modern era when incidence of ectopic pregnancy is increasing due to parallel increase in etiological factor-like sexually transmitted diseases and assisted reproductive techniques by early detection with transvaginal ultrasound and CT scan which can reduce maternal mortality and morbidity, offer the couple a more optimistic outlook for subsequent reproductive potential and reduce mental, emotional trauma to the patient.

## REFERENCES

1. Worley KC, Hnat MD, Cunningham FG. Advanced extrauterine pregnancy: diagnostic and therapeutic challenges. *Am J Obstet Gynecol* 2008;198(3):297.E1–297.E7. DOI: 10.1016/j.ajog.2007.09.044.
2. Nama V, Gyampoh B, Karoshi M, et al. Secondary abdominal appendicular ectopic pregnancy. *J Minim Invasive Gynecol* 2007;14(4):516–517. DOI: 10.1016/j.jmig.2007.02.005.
3. Chui AK, Lo KW, Choi PC, et al. Primary hepatic pregnancy. *ANZ J Surg* 2001;71(4):260–261. DOI: 10.1046/j.1440-1622.2001.02085.x.
4. Yagil Y, Beck-Razi N, Amit A, et al. Splenic pregnancy: the role of abdominal imaging. *J Ultrasound Med* 2007;26(11):1629–1632. DOI: 10.7863/jum.2007.26.11.1629.
5. Masukume G. Live births resulting from advanced abdominal extrauterine pregnancy, a review of cases reported from 2008 to 2013. *Obstet Gynecol* 2014;5(1):WMC004510.
6. Goldner TE, Lawson HW, Xia Z, et al. Surveillance for ectopic pregnancy: United States, 1970–1989. *MMWR CDC Surveill Summ* 1993;42(6):73–85.
7. Marchbanks PA, Annegers JF, Coulam CB, et al. Risk factors for ectopic pregnancy. a population-based study. *JAMA* 1998;259(12):1823–1827. DOI: 10.1001/jama.1988.03720120027030.
8. Fujishita A, Masuzaki H, Newaz Khan K, et al. Laparoscopic salpingotomy for tubal pregnancy: comparison of linear salpingotomy with and without suturing. *Hum Reprod* 2004;19(5):1195–1200. DOI: 10.1093/humrep/deh196.
9. Vermesh M, Presser SC. Reproductive outcome after linear salpingostomy for ectopic gestation: a prospective 3-year follow-up. *Fertil Steril* 1992;57(3):682–684. DOI: 10.1016/S0015-0282(16)54921-8.
10. Brumsted JR, Nakajima ST, Badger G, et al. Serum concentration of ca-125 during the first trimester of normal and abnormal pregnancies. *J Reprod Med* 1990;35(5):499–502.