



World Journal of Laparoscopic Surgery

An Official Publication of the World Association of Laparoscopic Surgeons, UK

Editors-in-Chief

RK Mishra (India)

Jiri PJ Fronek (UK)



WJOLS

Also available online at
www.jaypeejournals.com
www.wjols.com

Access Online Resources



For more details, visit
www.wjols.com

Bibliographic Listings:

ProQuest, Scopus, Journals Factor,
EBSCO, Genamics JournalSeek, Emcare, HINARI, Embase,
J Gate, Google Scholar, Ulrich, CiteFactor, SIS,
OAJI, MIAR, SIF, COSMOS, ESJI, SJIF, SJR, IJIF, ICI



JAYPEE Jaypee Journals

Editorial

Our goal for World Journal of Laparoscopic Surgery must be to convey our reader knowledge of excellent operative care with evidence-based perioperative processes, to leverage what we do in the operation room to its maximal benefit. In so doing, we can generate the evidence that will move the needle from open to MIS and serve our patients best.

World Association of Laparoscopic Surgeons (WALS) has grown enormously with the laparoscopic revolution as a primary society for minimal access surgeons including gynecologists and urologists. This organization is remarkable for its energy and the capacity of its members to work hard to achieve our organizational goals. It is unlike any organization to which I belong in allowing and encouraging young surgeons to get involved and to develop their careers.

Membership is the fuel of any professional organization. We will make a strong push to increase our membership of WALS and World Journal of Laparoscopic Surgery this year. This effort will be built around conveying the values that drive WALS, the opportunities for career development, the interpersonal opportunities to network and expand the community of each of our members, and the excellent value that WALS membership provides. We will bring this effort to residents and fellows and will extend our reach internationally.

We take great pleasure in inviting you to Fourth World Congress of Laparoscopic Surgeons on February 8th and 9th 2014. This event is organized by World Association of Laparoscopic Surgeons and hosted by World Laparoscopy Hospital, Gurgaon, India. This year, WALS committees have worked hard to ensure a varied program for professional development and networking opportunities. I would encourage each of you to bring two new members to WALS this year. I know that they will thank you for years to come.

It is an incredible honor for me to be WALS Organizing Secretary. WALS is your organization. It is essential that the WALS leadership keep in touch with our members and respond to their needs. For more details regarding the conference, please visit website www.wals.in. If you have any questions about the conference, please e-mail md@laparoscopyhospital.com and please communicate your ideas to us and get involved!

Again, I request all of you to join hands and make the forthcoming Congress a grand success.



RK Mishra
Editor-in-Chief

Effect of Different Carbon Dioxide Pressure Gradients in Capnoperitoneum for Laparoscopic Examination in Dogs

Swapan Kumar Maiti, Avijit Dutta, Jagadish Varshney, Naveen Kumar

ABSTRACT

Eighteen female mongrel bitches, equally divided into three groups (A, B and C) were subjected to CO₂ insufflation at 6, 10 and 14 mm Hg pressure gradient respectively to study the physiological changes of capnoperitoneum during laparoscopy. Optimum visualization of internal organs during laparoscopy was achieved at 10 and 14 mm Hg of CO₂ pressure gradient. The physiological effects were more pronounced at 14 mm Hg of CO₂ pressure gradient. Marked increase of respiration rate in correlation with increased pCO₂ and decreased pO₂ was observed in the group C. Bradyarrhythmia was observed in all three groups, however, myocardial ischemia or hypoxia as reflected through S-T segment depression and elevation was more pronounced in 14 mm Hg of CO₂ pressure gradient (group C). Alteration of liver function was within the physiological range in the animals of all the three groups. Physiological stress was remained significantly higher with 14 mm Hg intra-abdominal pressure. In conclusion, 10 mm Hg of CO₂ was found most suitable pressure gradient for laparoscopic examination in dogs.

Keywords: Capnoperitoneum, Dog, Intra-abdominal pressure, Electrocardiography, Laparoscopic surgery.

How to cite this article: Maiti SK, Dutta A, Varshney J, Kumar N. Effect of Different Carbon Dioxide Pressure Gradients in Capnoperitoneum for Laparoscopic Examination in Dogs. *World J Laparosc Surg* 2013;6(2):53-62.

Source of support: Nil

Conflict of interest: None declared

INTRODUCTION

Laparoscopy is now considered as one of the most potent and promising aids for both its diagnostic and therapeutic use. It involves minimal invasiveness (keyhole surgery) with maximum visibility, shorter surgical time, decreased postoperative discomfort and pain, less incidence of infection, uncomplicated healing with minimal scarring, and minimal surgical morbidity.^{1,2} Laparoscopy is now emerging as a diagnostic and therapeutic tool in the medical field.³

Laparoscopic examination requires the separation of structures from the abdominal wall. Insufflations of the abdomen with most suitable gas CO₂ optimally separates the intra-abdominal organs from ventral and lateral walls.⁴ In response to CO₂ capnoperitoneum (CP) there are series of physiologic responses that have an impact on cardio-pulmonary function of animal. These responses include the hemodynamic changes related to mechanical and neuroendocrine effects of CP and effects of absorbed CO₂ on cardiovascular and respiratory function.⁵ Routine

electrocardiogram is therefore a very useful mean for continuous assessment of patient's condition during laparoscopy. In addition, blood gas analysis has been proved very useful to evaluate the effect of CP.⁶ Increased intra-abdominal pressure affects various intra-abdominal organs and is linearly regulated by its level and durations. Alteration of hepatic function has been reported following laparoscope surgery.¹

So far, very little works has been carried out on CP pressure gradient to establish a most suitable one for canine species with having minimum adverse effects. Therefore, the present study was undertaken to evaluate the physiological effect of CP using different CO₂ pressure gradients and to find a most suitable one for routine laparoscopic examination and surgery in canines.

MATERIALS AND METHODS

The study was conducted on 18 clinically healthy adult female mongrel dogs with body weights of 15 to 20 kg and aged 16 to 22 months. The animals were randomly divided into three equal groups (A, B and C) consisting of six animals each. Different CO₂ pressure gradients were used to produce CP for laparoscopic visualization of different intra-abdominal organs in these three groups of animals. In group A, CO₂ pressure gradient was 6 mm Hg, whereas, in groups B and C it was 10 and 14 mm Hg respectively. After administration of general anesthesia, the animals were placed in dorsal recumbency and then in the Trendelenburg position for laparoscopic visualization of different intraperitoneal organs.

A small 0.5 cm skin incision was made at the level of the umbilicus and a Verres needle was inserted. Insufflation of the abdominal cavity was achieved with carbon dioxide gas at the rate of 2 L/min with a pressure gradient of 6, 10 and 14 mm Hg in groups A, B and C respectively. A 6 mm safety trocar and cannula unit was inserted into the abdominal cavity. A rigid-type telescope connected to a light source and a digital camera was then introduced through the cannula. The intra-abdominal organs were visualized thoroughly. After completing the laparoscopic examination, CO₂ gas was allowed to escape through the cannula. The incisions were sutured with simple interrupted sutures. Antiseptic dressing was applied regularly for 3 days post-

surgery. The animals were evaluated on the basis following observations.

- *Intraoperative and postoperative observations:* Visualization of different peritoneal organs namely liver, spleen, urinary bladder, uterus, ovary, pancreas, gall bladder, stomach and intestine were assessed on the basis of scoring for each organ as: 0-no visualization of an organ; 1-difficult visualization of an organ; 2-moderate visualization of an organ and 3-optimum visualization of an organ.
- *Clinical observations:* The heart rate (beats/min), respiratory rate (breaths/min), and rectal temperature (°F) were recorded before and after anesthesia, 30, 60 and 120 minutes after establishment of CP and 24 hours postlaparoscopy.
- *Electrocardiographic observations:* A lead II ECG was recorded at 1 mV and 25 mm/s paper speed before and after anesthesia, 30, 60 and 120 minutes after establishment of CP and 24 hours after laparoscopy. The ECG was analyzed for heart rate, duration and amplitude of P-wave, QRS complex, T-wave and RR, P-R, S-T and Q-T intervals.
- *Hematological and biochemical observations:* Heparinized blood was collected before and after anesthesia, 30, 60 and 120 minutes after establishment of CP and 24 hours postlaparoscopy for estimation of packed cell volume (PCV), hemoglobin (Hb), total leukocyte count (TLC), differential leukocyte count (DLC), aspartate aminotransferase (AST), alanine aminotransferase (ALT), creatinine, blood urea nitrogen and uric acid using standard procedures.
- *Acid-base observations:* Different acid-base parameters like pH, partial pressure of oxygen (pO₂), partial pressure of carbon dioxide (pCO₂), sodium, potassium, chloride and base excess were estimated by using 0.5 ml an aerobically collected heparinized venous blood in blood gas analyzer.
- *Hormonal observations:* The plasma samples were used to estimate the cortisol by radioimmunoassay assay using RIA kit.
- *Statistical analysis:* The data were subjected to two-way analysis of variance (ANOVA) and the paired t-test, as per standard statistical methods.

RESULTS

Intraoperative and Postoperative Observations

The surgical phase of anesthesia in all the animals of different groups was achieved by administering xylazine and ketamine in combination. No additional anesthesia was required in any animal to complete the intraoperative

procedure. The postsurgical recovery from anesthesia in all of the animals of three groups was smooth and uneventful.

Establishment CP in each animal was easy and safe. Insufflation of the abdominal cavity with CO₂ gas at the flow rate of 2 L/min was found sufficient for establishment of CP within 1 to 2 minutes in all of the animals of three groups. All animals were closely monitored for their respiration and capillary perfusion. Each animal tolerated well during insufflation even at Trendelenburg position. Insufflation by CO₂ at 6, 10 and 14 mm Hg was maintained for 30 minutes in each animal of groups A, B and C respectively. During this period complication like emphysema or respiratory distress was not noticed in any animal.

The urinary bladder was visualized first by its characteristic tortuous structures of blood vessels. Uterine body was visualized next and it depended on the distension of the urinary bladder. The uterus and ovarian structure were thoroughly visualized with their characteristic ivory-colored, cord-like structure. Both the kidneys were identified by the presence of perirenal fat at the corresponding level of last costochondral junction (Fig. 1). Spleen was visualized in the upper left abdominal quadrant, cranial to the left kidney. It was tongue shaped and in close exposure its diaphragmatic surface was converse and cobbled. In the upper right abdominal quadrant, liver was identified by its bright red color and uniform smooth surfaces. Gallbladder was visualized in between right medial and right lateral lobes and appeared as distended, round and whitish to bluish in color (Fig. 1). The empty stomach appeared as dense, pale-red in color and was situated toward the mid-abdominal plane. Visualization of pancreas was found most difficult in this study. In contrary, intestine was visualized very easily and appeared as loop like structures (Fig.1) Different abdominal organs were evaluated in respect of their visualization pattern during laparoscopy in three groups. Observations were recorded on the basis of numerical score from '0' to '3' depending on the degree of visualization (Table 1). No differences in scores have been observed in groups B and C, but they significantly ($p < 0.05$) differed from group A.

Normal appetite returned within 2 to 4 hours after surgical intervention in all animals. No postoperative complications like emphysema, portal herniation, peritonitis, ascites, or stitch abscess were recorded in any animals of the three groups.

Clinical Observations

The respiration rate (breaths/min), heart rate (beats/min), and rectal temperature (°F) recorded in all of the animals of three groups are presented in Table 2. Respiration rate decreased significantly ($p < 0.05$) in all the animals of three groups after anesthesia. However, in group C, it was

significantly ($p < 0.05$) increased at 60 minutes interval after CP. Heart rate (beats/min) decreased nonsignificantly ($p > 0.05$) immediately after anesthesia and at 30, 60 and 120 minutes after CP in all of the animals of the three groups. However, it again nonsignificantly ($p > 0.05$) increased at 24 hours postlaparoscopy in all the three groups. This fluctuation in heart rate was more pronounced in the animals of group C than it was in groups A and B. Preoperative as well as postoperative mean rectal temperatures ($^{\circ}\text{F}$) recorded

in all three groups remained within the normal limits throughout the observation period.

Electrocardiographic Indices

The mean amplitude and duration of P-wave in all the animals of three groups did not differ significantly (Table 3). Wandering pacemaker was evident in three animals of groups A and B and one animal of group C after CP (Fig. 2). One animal of group C showed occasional

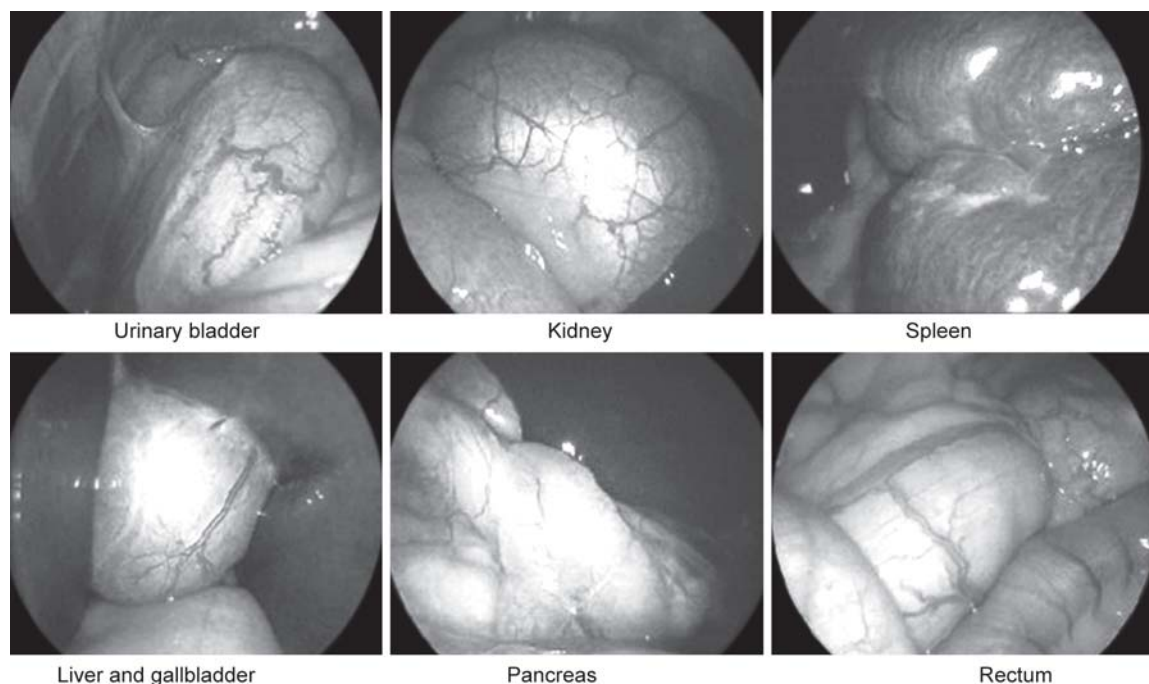


Fig. 1: Laparoscopic visualization of different intra-abdominal organs at 10 mm Hg of CO_2 pressure gradient

Table 1: Mean \pm SE of visualization score of internal organs during laparoscopy in animals of different groups

Groups	Liver	Spleen	Gallbladder	Pancreas	Intestine	Kidney	Ovary	Uterus
A	2.33 ± 0.21	2.16 ± 0.16	2.50 ± 0.22	0.33 ± 0.21	2.50 ± 0.22	1.50 ± 0.22	2.16 ± 0.16	1.83 ± 0.16
B	2.66 ± 0.21	2.66 ± 0.24	3.00 ± 0.00	2.50 ± 0.22	3.00 ± 0.00	2.66 ± 0.21	3.00 ± 0.00	2.66 ± 0.21
C	3.00 ± 0.00	3.00 ± 0.05	3.00 ± 0.00	2.50 ± 0.02	2.83 ± 0.30	3.00 ± 0.00	3.00 ± 0.04	3.00 ± 0.00

Table 2: Mean \pm SE value of respiration rate, heart rate and rectal temperature recorded at different time intervals

Groups	Before anesthesia	After anesthesia	Time intervals after establishment of capnoperitoneum			
			30 mins	60 mins	120 mins	24 hrs
Respiration rate (beats/min)						
A	26.83 ± 1.13	20.16 ± 0.98	28.16 ± 1.11	28.66 ± 1.33	26.16 ± 0.74	28.66 ± 1.08
B	29.16 ± 1.01	23.00 ± 1.39	29.66 ± 1.52	30.16 ± 1.93	28.66 ± 1.56	28.86 ± 0.84
C	28.50 ± 0.92	23.50 ± 1.05	31.83 ± 1.60	32.8 ± 1.07	30.16 ± 1.37	30.33 ± 0.88
Heart rate (beats/min)						
A	137.52 ± 20.15	136.25 ± 23.57	104.25 ± 17.97	93.25 ± 14.10	98.00 ± 18.92	132.50 ± 7.88
B	126.50 ± 9.91	107.00 ± 22.69	94.00 ± 5.47	86.00 ± 10.29	85.50 ± 5.12	115.00 ± 12.12
C	139.50 ± 16.50	105.00 ± 22.78	97.00 ± 13.3	106.50 ± 19.81	145.75 ± 29.85	134.50 ± 9.68
Rectal temperature (F)						
A	100.85 ± 0.33	100.98 ± 0.48	101.05 ± 0.55	101.11 ± 0.25	101.21 ± 0.43	101.33 ± 0.29
B	100.45 ± 0.32	100.36 ± 0.44	100.45 ± 0.38	100.41 ± 0.39	100.56 ± 0.36	100.83 ± 0.27
C	100.63 ± 0.50	100.71 ± 0.38	100.23 ± 0.21	100.63 ± 0.23	101.15 ± 0.44	101.28 ± 0.26

atrial premature complex after anesthesia and at 60 minutes post-CP (Fig. 2). Intermittent sinus arrest was also evident in one animal of group C after anesthesia (Fig. 2). The preanesthetic amplitude and duration of QRS complex and T-wave in all the animals of three groups also did not differ significantly (Tables 4 and 5). Changes of T-wave amplitude and duration were more marked in group C than groups A and B. After establishment of CP, characteristics T-wave were observed in the animals of different groups at different time intervals. In group A, T-wave became biphasic at 30 minutes (two animals), 60 minutes (three animals), 120 minutes (two animals) and 24 hours (one animal) (Fig. 2). In addition to biphasic, characteristic T-wave alternans was also observed in one animal of group A at 30- and 60-minute post-CP. In group C, two animals showed biphasic T-wave at 60 and 120 minutes post-CP. The initial mean duration of RR interval did not differ significantly in all of the animals of the different groups (Table 6). The initial mean duration of PR interval, ST interval and QT intervals were almost same in all of the animals of three different groups. The ST elevation (one

animal of group A at 60 minutes) and ST depression (one animal of group C at 30 and 60 minutes) were also recorded after establishment of CP (Fig. 2).

Hematological Observations

Mean \pm SE of PCV, Hb and TLC are presented in Table 7. Preanesthetic values of PCV and Hb in all of the animals of the three different groups were within the normal limit. No significant change was observed when comparisons were made between the groups at different time intervals. No significant leukocytosis or leukopenia was observed in any animal of the three groups before and after anesthesia, rather they were within the normal limit (Table 7). DLC of the animals of three different groups at different intervals did not reveal any significant differences. Only a mild neutrophilia and comparative lymphopenia were evident in groups B and C at 120 minutes post-CP.

Acid-base Analyses

Mean \pm SE values of pH in different groups are presented in Figure 3. No significant ($p > 0.05$) difference of pH value

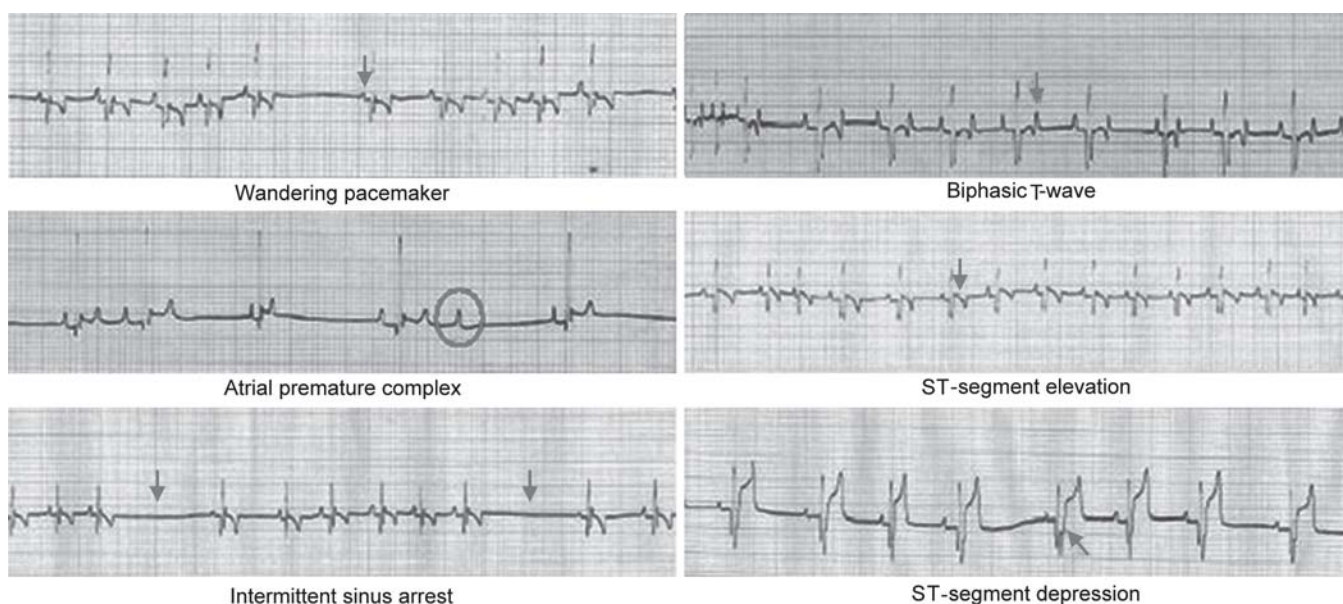


Fig. 2: Characteristic electrocardiograms in the animals of three different groups

Table 3: Mean \pm SE of P-wave (amplitude and duration) recorded at different time intervals

Table 3: Mean ± SE of P-wave (amplitude and duration) recorded at different time intervals						
Groups	Before anesthesia	After anesthesia	Time intervals after establishment of capnoperitoneum			
			30 mins	60 mins	120 mins	24 hrs
Amplitude (mV)						
A	0.150 ± 0.035	0.137 ± 0.023	0.143 ± 0.021	0.115 ± 0.016	0.137 ± 0.023	0.150 ± 0.020
B	0.163 ± 0.031	0.103 ± 0.039	0.169 ± 0.037	0.163 ± 0.023	0.175 ± 0.032	0.163 ± 0.024
C	0.206 ± 0.016	0.163 ± 0.024	0.175 ± 0.014	0.163 ± 0.012	0.206 ± 0.026	0.175 ± 0.014
Duration (seconds)						
A	0.032 ± 0.004	0.035 ± 0.002	0.037 ± 0.002	0.032 ± 0.004	0.032 ± 0.002	0.035 ± 0.002
B	0.040 ± 0.000	0.042 ± 0.000	0.038 ± 0.003	0.040 ± 0.000	0.044 ± 0.000	0.035 ± 0.003
C	0.038 ± 0.003	0.033 ± 0.005	0.035 ± 0.003	0.040 ± 0.000	0.038 ± 0.003	0.035 ± 0.003

was recorded in any group at any time interval. Mean \pm SE values of partial pressure of carbon dioxide ($p\text{CO}_2$) in the animals of different groups are presented in Figure 4. Comparison among three groups revealed no significant variation among the mean values, in respect to different time intervals. Mean \pm SE values of partial pressure of oxygen ($p\text{O}_2$) in the animals of different groups are presented in Figure 5. In all the animals of the three groups a nonsignificant ($p > 0.05$) decrease of $p\text{O}_2$ were recorded

at 30 minutes after CP and it continued up to 120 minutes. Mean \pm SE values of base excess (BE-B) in the animals of three groups are presented in Table 8. No significant ($p > 0.05$) changes were observed at any time interval within a group or between the groups. Mean \pm SE values of sodium, potassium and chloride in animals of three groups are presented in Table 9. No significant ($p > 0.05$) changes were observed at any time interval within a group or between the groups.

Table 4: Mean \pm SE of QRS complex (amplitude and duration) recorded at different time intervals

Groups	Before anesthesia	After anesthesia	Time intervals after establishment of capnoperitoneum			
			30 mins	60 mins	120 mins	24 hrs
Amplitude (mV)						
A	0.975 ± 0.189	1.112 ± 0.198	1.087 ± 0.25	1.025 ± 0.221	1.075 ± 0.221	1.025 ± 0.193
B	1.075 ± 0.048	1.275 ± 0.048	1.313 ± 0.148	1.225 ± 0.184	1.325 ± 0.103	0.887 ± 0.174
C	0.900 ± 0.141	0.988 ± 0.238	0.975 ± 0.149	0.901 ± 0.119	0.850 ± 0.137	0.925 ± 0.165
Duration (seconds)						
A	0.042 ± 0.006	0.040 ± 0.004	0.045 ± 0.005	0.045 ± 0.006	0.040 ± 0.004	0.042 ± 0.006
B	0.048 ± 0.005	0.043 ± 0.005	0.053 ± 0.003	0.043 ± 0.003	0.045 ± 0.003	0.0043 ± 0.005
C	0.050 ± 0.005	0.052 ± 0.002	0.055 ± 0.006	0.052 ± 0.006	0.048 ± 0.002	0.048 ± 0.004

Table 5: Mean \pm SE of T-wave (amplitude and duration) recorded at different time intervals

Groups	Before anesthesia	After anesthesia	Time intervals after establishment of capnoperitoneum			
			30 mins	60 mins	120 mins	24 hrs
Amplitude (mV)						
A	0.231 ± 0.034	0.268 ± 0.101	0.212 ± 0.051	0.262 ± 0.055	0.162 ± 0.037	0.225 ± 0.032
B	0.138 ± 0.038	0.388 ± 0.065	0.350 ± 0.106	0.275 ± 0.032	0.288 ± 0.075	0.363 ± 0.103
C	0.150 ± 0.029	0.225 ± 0.014	0.387 ± 0.208	0.512 ± 0.231	0.225 ± 0.043	0.175 ± 0.025
Duration (seconds)						
A	0.045 ± 0.002	0.070 ± 0.010	0.057 ± 0.010	0.070 ± 0.017	0.045 ± 0.012	0.060 ± 0.000
B	0.045 ± 0.005	0.065 ± 0.009	0.077 ± 0.023	0.075 ± 0.035	0.073 ± 0.018	0.050 ± 0.009
C	0.057 ± 0.010	0.055 ± 0.013	0.075 ± 0.042	0.075 ± 0.022	0.045 ± 0.008	0.058 ± 0.010

Table 6: Mean \pm SE of different intervals (seconds) on electrocardiograph recorded at different time intervals

Groups	Before anesthesia	After anesthesia	Time intervals after establishment of capnoperitoneum			
			30 mins	60 mins	120 mins	24 hrs
RR interval						
A	0.480 ± 0.120	0.670 ± 0.174	0.735 ± 0.152	0.745 ± 0.085	0.756 ± 0.144	0.430 ± 0.099
B	0.525 ± 0.075	0.568 ± 0.148	0.639 ± 0.042	0.763 ± 0.106	0.854 ± 0.054	0.545 ± 0.069
C	0.485 ± 0.100	0.715 ± 0.098	0.746 ± 0.068	0.488 ± 0.184	0.512 ± 0.106	0.490 ± 0.070
PR interval						
A	0.090 ± 0.005	0.127 ± 0.013	0.110 ± 0.012	0.085 ± 0.005	0.097 ± 0.014	0.090 ± 0.005
B	0.095 ± 0.006	0.105 ± 0.006	0.105 ± 0.009	0.098 ± 0.008	0.103 ± 0.006	0.078 ± 0.006
C	0.085 ± 0.011	0.100 ± 0.015	0.113 ± 0.017	0.100 ± 0.014	0.085 ± 0.006	0.108 ± 0.015
ST interval						
A	0.052 ± 0.007	0.045 ± 0.013	0.080 ± 0.023	0.080 ± 0.016	0.063 ± 0.01	0.050 ± 0.012
B	0.065 ± 0.009	0.063 ± 0.008	0.075 ± 0.022	0.070 ± 0.024	0.100 ± 0.02	0.070 ± 0.006
C	0.040 ± 0.014	0.055 ± 0.015	0.059 ± 0.019	0.052 ± 0.017	0.053 ± 0.011	0.040 ± 0.008
QT interval						
A	0.165 ± 0.017	0.185 ± 0.005	0.245 ± 0.059	0.205 ± 0.013	0.178 ± 0.006	0.185 ± 0.009
B	0.180 ± 0.016	0.200 ± 0.016	0.233 ± 0.024	0.218 ± 0.024	0.240 ± 0.022	0.170 ± 0.007
C	0.162 ± 0.016	0.190 ± 0.023	0.212 ± 0.024	0.227 ± 0.016	0.165 ± 0.003	0.175 ± 0.017

Biochemical Observations

Mean \pm SE values of AST and ALT in the animals of three groups are presented in Figures 6 and 7 respectively. AST and ALT values were within the normal range in all of the animals of three different groups throughout the observation period. Comparison among three groups revealed no significant ($p > 0.05$) changes at any time interval. Mean \pm SE values of creatinine, blood urea nitrogen and uric acid in animals of three groups are presented in Table 10. The creatinine, BUN and uric acid values in all three groups were within the normal range throughout the observation period.

Hormonal Estimation

Mean \pm SE of cortisol values recorded in animals of three different groups are presented in Figure 8. Cortisol values

in all of the animals of three groups started to increase at 30 minutes after CP and reached to peak at 120 minutes after CP, which were significantly ($p < 0.01$) higher than the base value of the respective group.

DISCUSSION

General anesthesia was achieved by inducing xylazine and ketamine combination with premedication by atropine sulphate was found sufficient to establish CP and laparoscopy in the animals of three different groups. Induction as well as recovery from general anesthesia was smooth and uneventful in all of the animals, as was also reported by Wildt and associates in 1977.¹

The establishment of CP in the animals of all three groups was easy through Verrees needle at preselected

Table 7: Mean \pm SE of PCV, Hb and TLC recorded at different time intervals

Groups	Before anesthesia	After anesthesia	Time intervals after establishment of capnoperitoneum			
			30 mins	60 mins	120 mins	24 hrs
PCV (L/l)						
A	0.41 ± 0.02	0.38 ± 0.01	0.38 ± 0.01	0.40 ± 0.01	0.39 ± 0.01	0.39 ± 0.01
B	0.41 ± 0.01	0.41 ± 0.01	0.40 ± 0.01	0.41 ± 0.01	0.41 ± 0.01	0.43 ± 0.01
C	0.43 ± 0.01	0.41 ± 0.02	0.40 ± 0.02	0.40 ± 0.01	0.41 ± 0.01	0.41 ± 0.01
Hb (g/l)						
A	139.83 ± 7.42	132.33 ± 5.16	131.33 ± 5.37	135.50 ± 5.27	134.00 ± 5.42	138.83 ± 7.38
B	136.16 ± 4.50	133.00 ± 4.36	131.66 ± 4.48	132.66 ± 4.77	134.83 ± 4.36	137.32 ± 6.44
C	142.33 ± 6.23	135.83 ± 7.00	134.83 ± 7.55	135.50 ± 5.39	134.66 ± 5.48	137.33 ± 5.50
TLC (10 ⁹ /l)						
A	8.93 ± 0.69	9.14 ± 0.75	9.18 ± 0.78	9.85 ± 0.79	9.98 ± 0.74	9.96 ± 0.70
B	9.41 ± 1.19	9.30 ± 1.15	9.74 ± 1.17	10.07 ± 1.36	11.56 ± 1.22	9.83 ± 1.21
C	9.13 ± 1.10	9.36 ± 1.21	9.93 ± 1.22	11.10 ± 1.26	12.07 ± 1.41	9.58 ± 1.14

Table 8: Mean \pm SE of base excess of blood (mmol/l) recorded at different time intervals

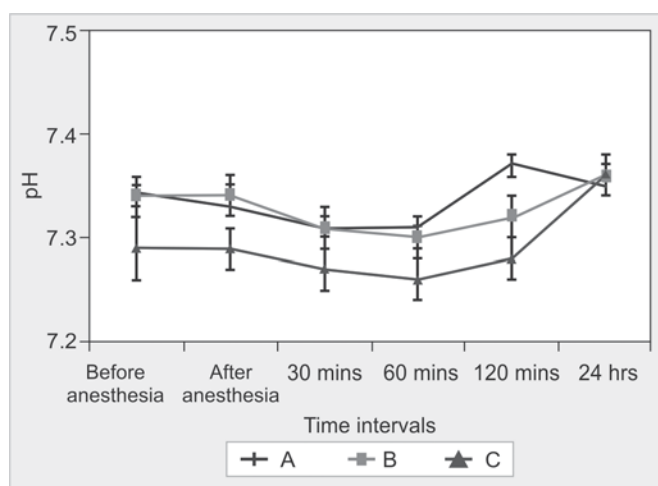
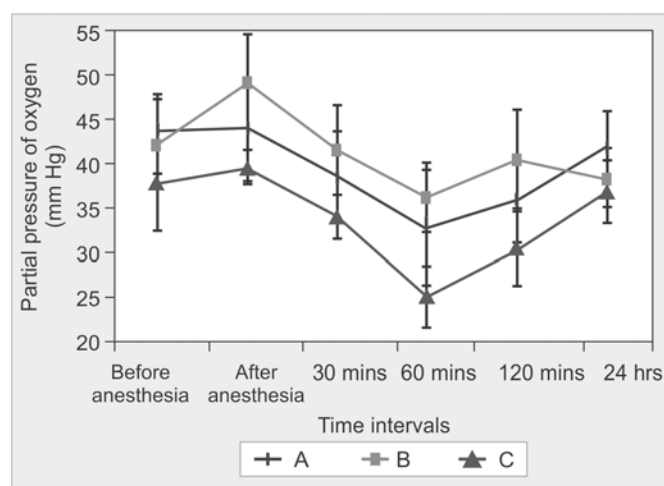
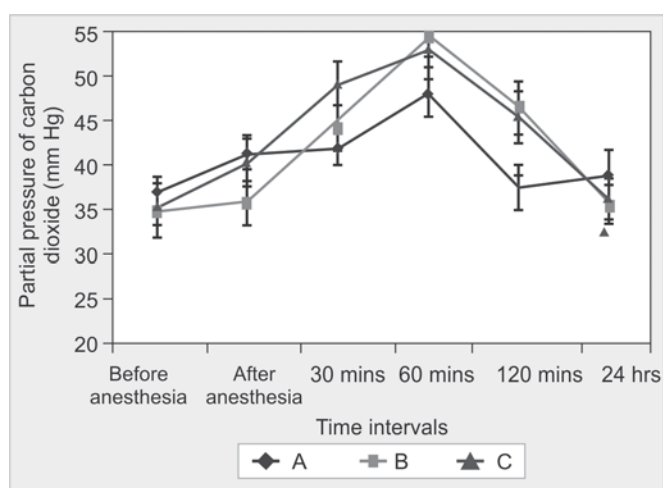
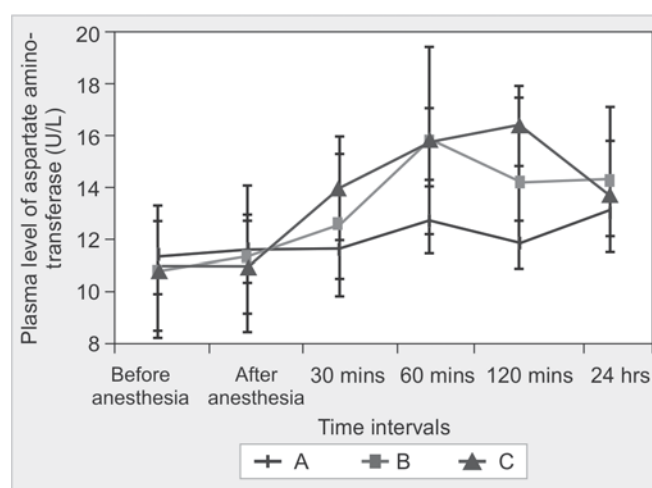
Groups	Before anesthesia	After anesthesia	Time intervals after establishment of capnoperitoneum			
			30 mins	60 mins	120 mins	24 hrs
A	-2.91 \pm 1.32	-1.98 \pm 1.20	-2.43 \pm 1.16	-1.71 \pm 1.26	-0.66 \pm 1.27	-0.31 \pm 1.10
B	-2.71 \pm 1.40	-2.61 \pm 1.12	-2.51 \pm 1.08	-1.98 \pm 1.00	-1.50 \pm 1.36	-1.56 \pm 2.06
C	-2.11 \pm 0.59	-2.38 \pm 0.51	-2.61 \pm 0.64	-1.86 \pm 0.67	-1.35 \pm 0.65	-1.68 \pm 0.66

Table 9: Mean \pm SE of sodium, potassium and chloride (mmol/l) recorded at different time intervals

Groups	Before anesthesia	After anesthesia	Time intervals after establishment of capnoperitoneum			
			30 mins	60 mins	120 mins	24 hrs
Sodium						
A	147.33 ± 1.05	146.83 ± 0.94	146.33 ± 1.87	149.33 ± 2.99	146.33 ± 1.96	144.83 ± 1.4 4
B	146.83 ± 1.44	147.83 ± 1.72	147.33 ± 1.45	147.83 ± 1.68	149.00 ± 1.70	144.88 ± 1.08
C	146.83 ± 1.40	146.50 ± 1.12	145.66 ± 1.22	147.00 ± 1.00	148.00 ± 0.68	147.16 ± 1.24
Potassium						
A	4.53 ± 1.10	4.36 ± 0.14	4.46 ± 0.25	4.56 ± 0.19	4.41 ± 0.14	4.28 ± 0.07
B	4.56 ± 0.12	4.41 ± 0.10	4.56 ± 0.05	4.88 ± 0.14	4.76 ± 0.19	4.58 ± 0.17
C	4.40 ± 0.12	4.30 ± 0.18	4.21 ± 0.17	4.55 ± 0.14	4.36 ± 0.12	4.40 ± 0.10
Chloride						
A	113.00 ± 2.81	108.83 ± 1.68	108.66 ± 2.45	103.50 ± 3.38	107.83 ± 2.34	108.66 ± 0.80
B	110.66 ± 2.69	111.16 ± 1.49	110.66 ± 1.56	110.16 ± 1.40	111.16 ± 1.37	107.83 ± 1.32
C	108.50 ± 3.58	106.50 ± 1.87	107.00 ± 1.23	103.16 ± 3.16	104.83 ± 2.22	108.83 ± 1.95

Table 10: Mean \pm SE of creatinine, blood urea nitrogen and uric acid recorded at different time intervals

Groups	Before anesthesia	After anesthesia	Time intervals after establishment of capnoperitoneum			
			30 mins	60 mins	120 mins	24 hrs
A	61.34 \pm 5.77	69.89 \pm 7.07	79.89 \pm 7.44	72.23 \pm 5.35	77.33 \pm 8.19	76.40 \pm 8.74
B	74.59 \pm 10.55	72.42 \pm 9.20	82.24 \pm 12.03	78.95 \pm 9.86	79.67 \pm 11.14	92.43 \pm 7.70
C	74.80 \pm 10.92	80.23 \pm 13.60	79.53 \pm 15.83	86.44 \pm 14.24	90.08 \pm 15.21	91.51 \pm 13.7
BUN (mmol/l)						
A	7.23 \pm 0.76	6.65 \pm 0.66	7.21 \pm 0.71	7.30 \pm 0.79	8.09 \pm 0.64	7.74 \pm 0.58
B	7.41 \pm 0.63	7.34 \pm 0.78	7.49 \pm 0.72	7.91 \pm 0.90	8.32 \pm 0.58	8.04 \pm 0.36
C	7.40 \pm 0.81	7.31 \pm 0.86	7.65 \pm 1.02	7.67 \pm 0.94	8.52 \pm 1.06	8.35 \pm 1.30
Uric acid (μmol/l)						
A	42.36 \pm 7.29	39.47 \pm 6.56	42.34 \pm 6.74	41.18 \pm 6.48	42.80 \pm 8.24	42.62 \pm 8.68
B	40.00 \pm 6.05	42.99 \pm 6.53	43.57 \pm 7.22	44.52 \pm 8.65	43.69 \pm 7.90	42.12 \pm 7.09
C	50.89 \pm 9.14	50.01 \pm 9.25	54.61 \pm 10.07	52.61 \pm 7.83	48.83 \pm 6.15	51.12 \pm 6.94

**Fig. 3:** Mean \pm SE of pH recorded in the animals of three different groups**Fig. 5:** Mean \pm SE of partial pressure of pO₂ (mm Hg) recorded in the animals of three different groups**Fig. 4:** Mean \pm SE of partial pressure of pCO₂ (mm Hg) recorded in the animals of three different groups**Fig. 6:** Mean \pm SE of plasma aspartate aminotransferase (U/L) recorded in the animals of three different groups

pressure gradient in endoflator. Injection of 5 ml of normal saline through Verres needle was found very useful⁷ to confirm the insertion of the needle within the peritoneum and thereby the chance of subcutaneous emphysema.⁸ During trocarization some complications observed in two

animals of group A. In one animal, splenic trauma due to faculty trocarization while in other animal the tip of cannula was entrapped within the mesentery. Davidson and coworkers⁹ encountered inadvertent splenic puncture and laceration due to blunt trocarization in three out of

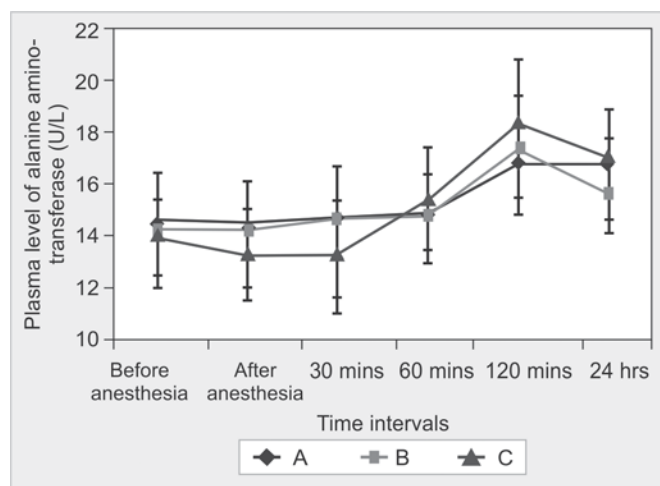


Fig. 7: Mean \pm SE of plasma alanine aminotransferase (U/L) recorded in the animals of three different groups

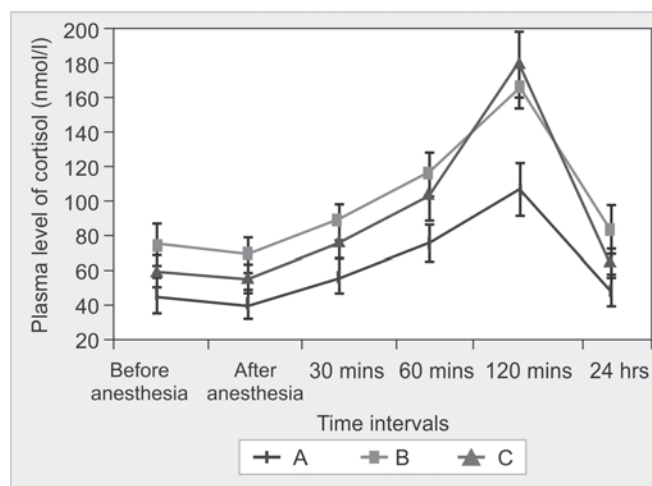


Fig. 8: Mean \pm SE of plasma cortisol (mmol/l) recorded in the animals of three different groups

16 animals during laparoscopic examination. The low insufflations pressure of CO₂ might attribute to insufficient spacing and separation of the abdominal structures from the ventral abdominal wall and led to these complications.

Visualization of the abdominal organs started from the urinary bladder which was readily and promptly visualized by its unique tortuous vasculature over the visceral surface. Identification and visualization of various internal organs like liver, spleen and pancreas, kidney, ovary and uterus during various laparoscopic surgeries have been reported.^{10,11} Evaluation of laparoscopic organ visualization at different CO₂ pressure gradient revealed marked differences among the three groups. Urinary bladder was visualized distinctly in all the animals of all three groups without any significant difference. But visualization of liver in group C differed significantly from group A. In groups B and C significantly better visualization was observed than that was in group A when other organs were evaluated.

No significant differences were found between the various groups as related to the physiologic parameters except the respiration rate. Following CP, it was increased in all groups, but it was significant in group C at 60 minutes after CP. Soon after CO₂ insufflation, CO₂ absorbed from abdominal cavity led to hypercapnia and hypercarbia which might stimulate the respiratory center and as compensation respiration rate was increased.¹² CP is associated with an increase in plasma potassium concentration,¹³ metabolic acidosis¹⁴ and hemodynamic changes;¹⁵ therefore, concomitant changes in electrocardiogram can be logically speculated. Although the initial heart rate ranged widely among the animals of three groups, it markedly decreased during post-CP period, which could be attributed to parasympathetic effect on vagus nerve owing to increased intra-abdominal pressure.⁵ Increase in R-R interval during

post-CP periods was in tune with the observation of decrease in heart rate and might be as a result of hypercarbia following CP.^{16,17} Wandering pacemakers, and atrial premature complexes were occasionally seen in this study. Wandering pacemaker a variant of sinus arrhythmia is a shift of pacemaker within the SA node and observed even in normal dogs.¹⁸ Atrial premature complexes, AV junction premature complexes, wandering pacemaker and intermittent sinus arrest seems to a normal variants and might be due to an increase in vagal tone in individual dogs on CP. The increase in amplitude of T-wave was more marked in group C at 60 minutes post-CP, and could be related to the transient hyperkalemia owing to CP.¹³ Biphasic T-wave and T-wave alternant were more marked in animals of group C. Large T-wave possibly indicated hyperkalemia and ST depression suggested myocardial ischemia.¹⁹ The ST intervals did not reveal any significant changes throughout the observation in three groups, however, ST elevation (in group A) and ST depression (in group C) were observed in some animals during post-CP and were suggestive of myocardial ischemia as a result of CP during laparoscopy.²⁰

PCV and Hb were unchanged throughout the observation period in all groups and remained within the normal range as also reported by Delling et al²¹ 24 hours after laparoscopy. The mean value of TLC revealed a nonsignificant increase at 60 and 120 minutes after CP in group C might be due to the effect of corticosteroid, released as a stress response of increased IP at higher CO₂ pressure gradient of group C. In this study, significant decrease of pH value was observed at 120 minutes after CP in group C might be due to hypercapnia developed as a result of increased absorption of CO₂ in blood from peritoneal cavity.⁵ Significant increase of pCO₂ in post-CP period in all the three groups might be due to compensate the respiratory acidosis developed as a result of hypercarbia.

Low insufflations pressure in group A might attributed to the unaltered plasma sodium, potassium and chloride as reported by Yavuz et al²² Furthermore, CP maintained for only 30 minutes in animals of the present study might be insufficient to inflict any changes.²³ Two cytosolic enzymes ALT and AST are mostly used to evaluate hepatic function. In this study both the ALT and AST revealed no statistically significant changes among the different groups in respect to different time intervals.

A nonsignificant increase of the mean plasma level of BUN, creatinine and uric acid was observed in post-CP period in all three groups and remained above the base value throughout the rest part of the observation period. This transient nonsignificant increase might be due to the effect of CP. In the present study, change of plasma cortisol in all groups was probably due to the effect of pneumoperitoneum rather than operative trauma. Change of plasma cortisol level had also been reported by O'Leary et al²⁴ at the time of laparoscopy. Marcovich et al²⁵ reported a higher cortisol level at 4 hours after laparoscopy in dogs. This change was reflected markedly in CP at 14 mm Hg than 6 mm Hg.

CONCLUSION

The results of this study indicated that 10 mm Hg of CO₂ pressure gradient provided optimum laparoscopic visualization of intra-abdominal organs and minimum physiological, biochemical, electrocardiographical changes and hormonal stress during laparoscopic examination in dogs.

ACKNOWLEDGMENT

The authors are highly thankful to the Indian Council of Agricultural Research (ICAR), New Delhi, for providing financial assistance in the term of Ad-hoc project granted on laparoscopic study in animals.

REFERENCES

- Wildt DE, Kinney GM, Seager SWJ. Laparoscopy for direct observation of internal organs of domestic cats and dogs. *Am J Vet Res* 1977;38:1429-32.
- Maiti SK, Dutta A, Ajith P, Kumar N, Sharma AK, Singh GR. Laparoscopy for direct examination of internal organs in small animals. *J Appl Anim Res* 2008;33:201-04.
- Dutta A, Maiti SK, Ajith P, Kumar N. Evaluation of different laparoscopic sterilization techniques in a canine birth control programme. *Turk J Vet Anim Sci* 2010;34:393-402.
- Ishizaki Y, Bandai Y, Shimomura K, Abe H, Ohtomo Y, Idezuki Y. Safe intra-abdominal pressure of carbon dioxide pneumoperitoneum during laparoscopic surgery. *Surgery* 1993; 114:549-54.
- Windberger U, Siegl H, Woisetschlager R. Haemodynamic changes during prolonged laparoscopic surgery. *Eur Surg Res* 1994;26:1-9.
- Cruz AM, Kerr CL, Boure LP, Sears WC. Cardiovascular effects of insufflation of the abdomen with carbon dioxide in standing horses sedated with detomidine. *Am J Vet Res* 2004;65: 357-62.
- Hardie RJ, Planders JA, Schmidt P, Credille KM, Pedrick JP, Short CE. Biochemical and histological evaluation of a laparoscopic stapled gastropexy technique in dogs. *Vet Surg* 1996;25:127-33.
- Crist DW, Gadacz TR. Complications of laparoscopic surgery. *Vet Clin North Am Equine Pract* 1993;73:265-89.
- Davidson EB, Moll HD, Payton ME. Comparison of laparoscopic ovariohysterectomy and ovariohysterectomy in dogs. *Vet Surg* 2004;33:62-69.
- Nord HJ. Complications of laparoscopy. *Endoscopy* 1992;24: 693-700.
- Lew M, Nowicki M, Jaynski M, Rychlik A. Laparoscope guided renal biopsy in dogs. *Medycina Weterynaryjna* 2003;59: 307-10.
- Seed RF, Shakespeare TF, Muldoon MJ. Carbon dioxide homeostasis during anesthesia for laparoscopy. *Anaesthes* 1970;25:223-28.
- Pearson MRB, Sander ML. Hyperkalaemia associated with prolonged insufflation of carbon dioxide into the peritoneal cavity. *Br J Anaesth* 1994;72:602-04.
- Perner A, Bugge K, Lyng KM, Schulze S, Kristensen PA, Bendtsen A. Changes in plasma potassium concentration during carbon dioxide pneumoperitoneum. *Br J Anaesthes* 1999;82: 137-39.
- Joris JL, Noirot DP, Legrand MJ, Jacquet NJ, Lamy ML. Haemodynamic changes during laparoscopic cholecystectomy. *Anesth Analg* 1993;76:1067-71.
- Yoshinobu M, Haruhisa H, Yuji H, Tadashi N, Yoshiaki H. Effects of systemic hypoxia on R-R interval and blood pressure variabilities in conscious rats. *Am J Physiol* 1998;275:H797-804.
- Halachmi S, Ghoneimi AE, Bissonnette B, Zaarour C, Bagli DJ, McLorie GA, et al. Haemodynamic and respiratory effect of paediatric urological laparoscopic surgery: A retrospective study. *J Urol* 2003;170:1651-54.
- Tilley LP. Essentials of canine and feline electrocardiography. Philadelphia: Lea and Febiger 1985;134-37.
- Coulter DB, Duncan RJ, Sander PD. Effects of asphyxia and potassium on canine and feline electrocardiograms. *Can J Comp Med* 1975;39:442-49.
- Jones CL. Electrocardiography. In: Tilley LP, Owens JM, (Eds). *Manual of small animal cardiology*. New York: Churchill Livingstone 1985;55-86.
- Delling U, Howard RD, Pleasant RS, Lanz OI. Hand-assisted laparoscopic ovariohysterectomy in the mare. *Vet Surg* 2004;33: 487-94.
- Yavuz Y, Ronning K, Lyng O, Marvik R, Gronbech JE. Effect of increased intra-abdominal pressure on cardiac output and tissue blood flow assessed by color-labeled microspheres in the pig. *Surg Endosc* 2001;15:149-55.
- Brundell SM, Tsopelas C, Chatterton J, Touloumtzoglou J, Hewett PJ. Experimental study of peritoneal blood flow and insufflation pressure during laparoscopy. *Br J Surg* 2002;89: 617-22.

24. O'Leary E, Hubbard K, Tomey W, Cunningham AJ. Laparoscopic cholecystectomy: Haemodynamic and neuro-endocrine responses after pneumoperitoneum and changes in position. *Br J Anaesth* 1996;76:640-44.
25. Marcovich R, Williams AL, Seifman BD, Wolf JS Jr. A canine model to assess the biochemical stress response to laparoscopic and open surgery. *J Endurol* 2001;15:1005-08.

ABOUT THE AUTHORS

Swapan Kumar Maiti (Corresponding Author)

Principal Scientist, Department of Veterinary Surgery, Indian Veterinary Research Institute, Bareilly, Uttar Pradesh, India
e-mail: maiti_62@rediffmail.com

Avijit Dutta

PhD Scholar, Department of Surgery, Indian Veterinary Research Institute, Bareilly, Uttar Pradesh, India

Jagadish Varshney

Principal Scientist, Department of Medicine, Indian Veterinary Research Institute, Bareilly, Uttar Pradesh, India

Naveen Kumar

Principal Scientist, Department of Surgery, Indian Veterinary Research Institute, Bareilly, Uttar Pradesh, India

Different Techniques of Tissue Retrieval from Abdominal Cavity during Minimal Access Surgery

Nuzhat Amer, Muhammad Amer, Rajineesh K Mishra

ABSTRACT

Minimally access laparoscopic surgery has undergone rapid development in last decade. It has many advantages but one of the challenges is the tissue retrieval from the surgical site. Large specimen can be retrieved after enlarging the port site but this is against the concept of minimal access surgery (MAS). In this article, we reviewed the literature to analyze the different methods of tissue retrieval during MAS. Tissue retrieval using the endobag for small to medium-sized specimens is straight forward through the umbilical trocar port. For larger specimens morcellation, delivery through colpotomy or hand-assisted laparoscopic surgery was used to retrieve the specimen. All these methods help to keep the incision size small hence improving the surgical outcome with minimal complications and early recovery.

Keywords: Laparoscopic tissue retrieval, Colpotomy, Endobag, Laparoscopic tissue retrieval sac, Morcellator.

How to cite this article: Amer N, Amer M, Mishra RK. Different Techniques of Tissue Retrieval from Abdominal Cavity during Minimal Access Surgery. *World J Laparosc Surg* 2013;6(2):63-68.

Source of support: Nil

Conflict of interest: None declared

INTRODUCTION

Laparoscopic surgery has been known by surgeons since 1980. After the advent of laparoscopic surgery, it has undergone rapid development in last decade. Laparoscopic surgery has many advantages, like less tissue dissection, less need of analgesia postoperatively, better cosmetic aspect, less intraoperative and postoperative complications and early return to work.¹

In laparoscopic surgery, one challenge is to retrieve the specimen from the abdominal cavity with minimal spillage as spillage of the content may cause dissemination of disease, infection or malignancy. Spillage rate depends upon the size of the mass, surgical expertise and route of removal of the tissue. Spillage rate of dermoid cyst by laparoscopy is 15 to 100% as compared to 4 to 13% in laparotomy.²

One method of retrieval of specimen from the abdomen is to enlarge one of the laparoscopic trocar incisions but it is against the concept of minimal access surgery (MAS).³ Tissue retrieval through port site may cause contamination, implantation and port site hernia formation.⁴

Transumbilical port is most thinnest and most distensible portion of the anterior abdominal wall. As this technique may be satisfactory for simple cyst or tissue but challenging in cases of dermoid cyst of larger sizes. Endobags will be

used but still the chance of spillage in case when perforation of the tissue inside the bag.⁵

Specimen retrieval bags used for removal of excised mass. It can avoid the spillage of the cyst and contamination of the wound (Fig. 1). The bags generally require 10 to 12 mm port.²

Many types of specimen retrieval bags have been described, including Nadiad bag, condom, modified zipper bag. Commercial bags can be costly and difficult to use and are available only in standard size. Some authors describe bags from surgical glove finger (powder free) but it can tear off during traction through abdominal wall. This can be minimized by making purse string suture around the opening (Fig. 2).⁶

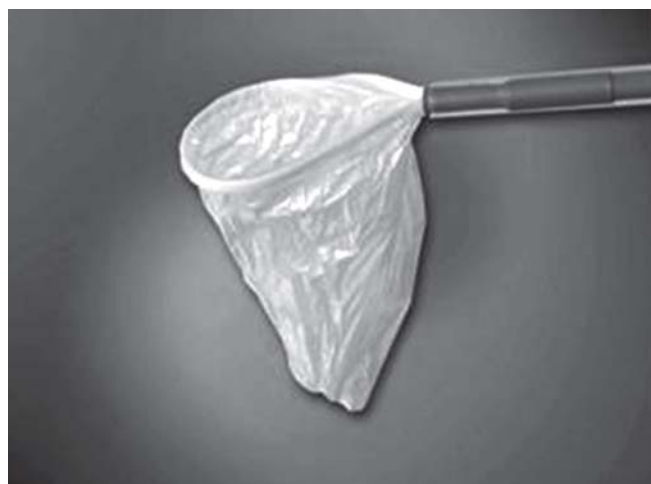

Fig. 1: Endobag for tissue retrieval in MAS




Fig. 2: Endobag made with surgical glove

Specimen can be retrieved through vaginal route by colpotomy. It was first documented over a 100 years ago but was not used much due to technical difficulties, poor exposure and increased risk of infection.⁵

Some surgeons prefer to use plastic bag for drainage package as endobag as it minimizes the tearing effect as in glove finger bag (Figs 3A and B).⁷

Transvaginal route has been popular again for last few years. Removal of the intact specimen through colpotomy is more important.

Colpotomy is generally safe and easily learnt technique. To minimize the risk of spillage, endoscopic bags can be used during removal of tissue under direct vision but, whenever incision is given in the posterior vagina, (colpotomy) pneumoperitoneum greatly affected.⁸

To maintain the pneumoperitoneum, counter pushing by other instrument inside the vagina is effective.¹

This problem can be overcome by suturing the posterior vaginal wall laparoscopically.⁸

Colpotomy may result injury to nearby structures, bladder or bowel perforation, ureter injury, vaginal wall hematoma. Extra care has to be taken during specimen removal through vagina as it may tear or lacerate. Risks will be more, if patient is nulliparous or morbid obese.⁵

Obstetric forceps can be used to extract the specimen enclosed in an endobag. It can help to protect the integrity of the bag and specimen and minimize the diameter of the sac.⁹

Morcellator is another technique to retrieve the solid tissue from abdominal cavity. It is important instrument for tissue removal in myomectomy and splenectomy. Morcellator works through sharp cylindrical blade over the specimen and change tissue into small strips (Figs 4A and B). Morcellator do not affect the pneumoperitoneum during its work.¹

Morcellator is not acceptable in cases where suspicion of infection or malignancy is there. Morcellated tissue may disturb the pathological findings on histopathology in cases of suspected malignancy.³

Large diameter morcellator remove tissue in less time but is associated with incisional hernia formation.² This complication can be avoided by port closure with sutures. Now morcellator with diathermy instead of blade are also available.¹⁰ Since, morcellator decrease the operative time so the risk of port site herniation decreases due to decreased manipulation.¹

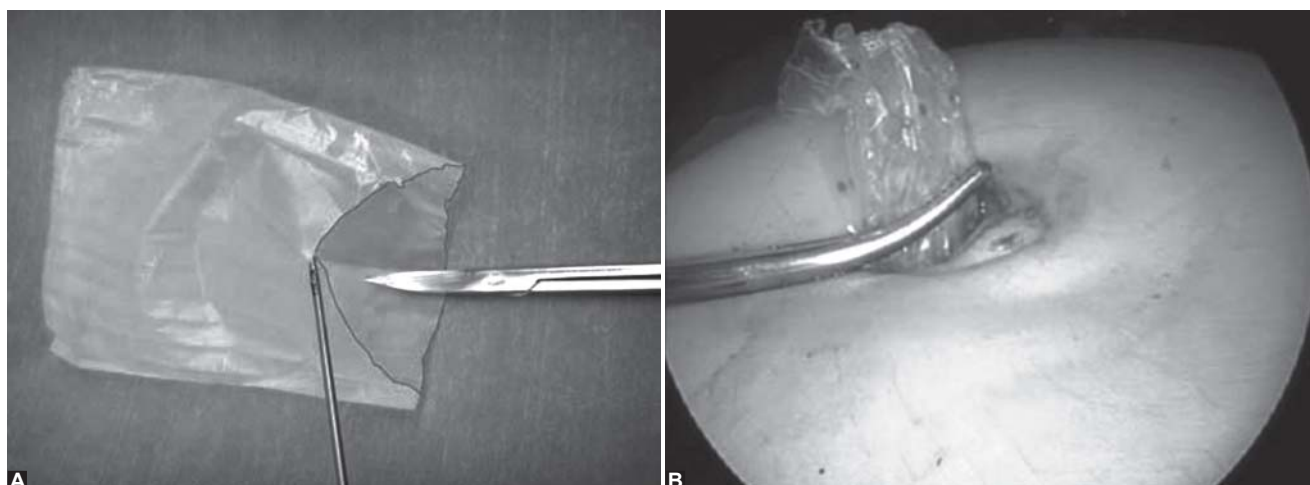
During morcellator use, caution must be taken as there is risk of inadvertent injury to the normal tissue. This can be avoided by bringing specimen toward the morcellator rather moving the morcellator toward specimen.⁸

Natural orifice, transluminal endoscopic surgery (NOTES) is another advancement of minimally invasive intra-abdominal surgery in which peritoneal cavity is approached by incising and traversing the lumen of natural orifices.¹¹

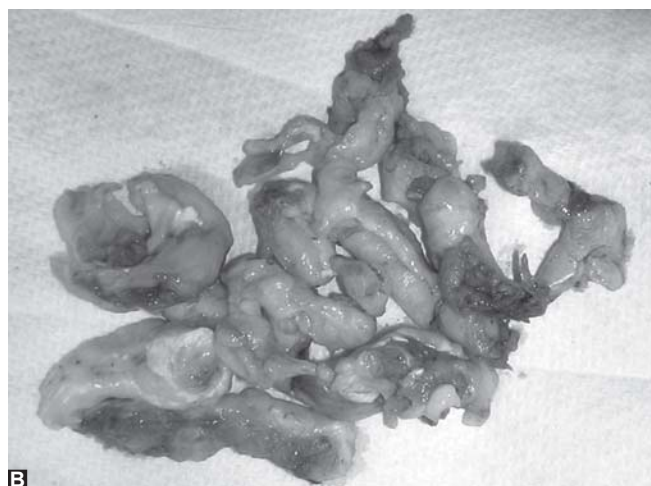Natural orifices, like oral, anal, vaginal and urethral routes, have been described but optimal route is still to be determined. Vaginal access has been used for long time due to its ease of access and more capacity. Closure of vaginal wound can be done under direct vision and complication rate is also low.¹²

Vaginal approach is not possible in some situations, like fixed retroverted uterus, obliteration of Pouch of Douglas, due to endometriosis or previous pelvic inflammatory disease.⁸

In hand-assisted laparoscopic surgery (HALS), the surgeon can insert a hand through a small incision via pressurized sleeve. It is a new advancement in MAS. HALS initially was started for tissue retrieval and surgeons can use their hand for exploration, isolation and removal of tissue (Fig. 5).¹



Figs 3A and B: Plastic bag used as endobag



Figs 4A and B: Morcellator and morcellated tissues

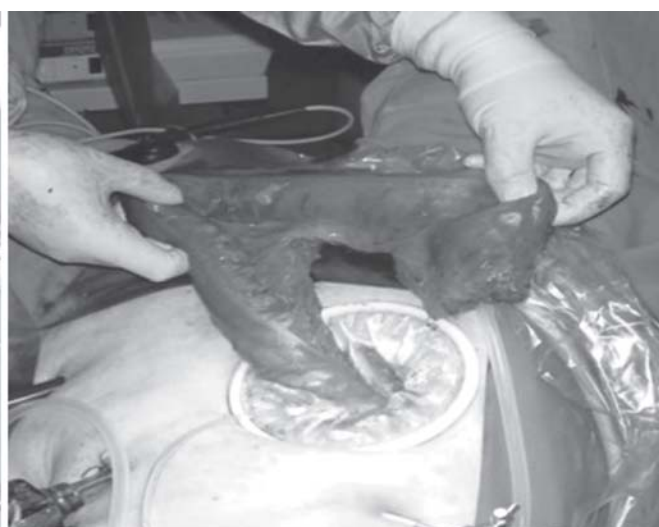
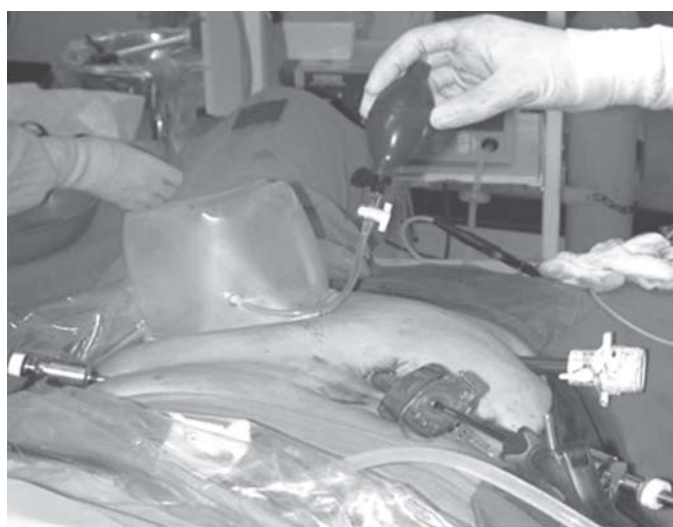
Fig. 5: HALS and tissue retrieval

It is indicated for complex and advance laparoscopy procedures. It restores tactile sensation and help to complete the laparoscopic surgery without conversion.⁹

MATERIALS AND METHODS

A literature search was performed using Google, Yahoo, PubMed, Springer library facility available at World Laparoscopy Hospital, Gurgaon, Haryana, India.

AIM

To evaluate the different techniques of tissue retrieval from abdominal cavity during MAS.

REVIEW OF EVIDENCE

Transumbilical Tissue Retrieval with Endobag

A prospective study was done by Schellpfeffer in which 42 patients underwent for laparoscopic tissue retrieval after surgery by transumbilical route. In 34 out of 42 patients, the

tissue retrieval was successful, while in eight patients (19%), it was unsuccessful due to size of the mass. The subumbilical incision became large during specimen removal. There was no sac rupture and no intraoperative complications relating to tissue retrieval. There was no incisional hernia in 2 to 6 weeks postoperative period. Three patients (7%) had superficial subumbilical trocar site wound infection which was managed conservatively.³

In a study done by Turial and Schier, they used sterile plastic bag (innermost cover from Redon drain package) to laparoscopically remove tissue through umbilical port. According to them, this bag is cost effective, does not need port enlargement as compared to commercially available bags and there was no bag rupture as seen with glove bag technique.⁷

In a study done by Ghezzi et al (1,116 women) underwent operative laparoscopy and endobags were used for laparoscopic tissue retrieval through umbilical port. They described method to remove large specimen without

enlarging the umbilical port. In this method, they bring the mouth of sac out of the port with help of atraumatic grasper. The specimen then is morcellated with Kocher's clamps to avoid intra-abdominal spillage. No intraoperative or immediate postoperative complication related to technique of specimen extraction was noted. No trocar site hernia or metastasis was observed.¹³

A study was done by Kao et al who described homemade specimen retrieval bag (sterile glove) for laparoscopic tissue retrieval. A total of 135 patients underwent laparoscopic surgery and tissue specimen were retrieved using bag made with surgical gloves. No postoperative complications were noted such wound infection or wound metastasis. They found this bag easy to prepare, easy to use, cost effective and with short learning curve.¹⁴

Ganpule et al have described a novel cost effective specimen retrieval bag (Nadiad bag) to retrieve specimen in laparoscopic surgery. They used this bag in 40 patients. They found this bag to be inexpensive and easy to use. This bag needs less force for traction and is tumor seeding is less. Urethral catheter used in this techniques keeps the bag open during entrapment.⁶

Schellpfeffer described a novel laparoscopic tissue retrieval device in which a forceps was used in cases where endobag could not be removed with axial traction. Out of 42 patients in eight, the retrieval was not successful even with the forceps and it was due to the large size of the mass. In these cases, the port size had to be enlarged to remove the mass. In 34 patients, the procedure was successful without and significant complications. Three patients developed subumbilical trocar site superficial infection which was managed conservatively. No incisional hernia was noted in early postoperative period. No adverse outcome was noted on long term follow-up (until 5 years).³

Tissue Retrieval by Morcellation

Chen et al did laparoscopic myomectomy and morcellator was used to remove the tissue. They grouped the patients into three groups according to the weight of fibroid. They observed shorter surgical time in groups with lower fibroid weight. Patients were followed for until 3 months. They advised to do simultaneous enucleation and *in situ* morcellation as this minimize the operative time and missing of myoma. They did not report any late postoperative complications.¹⁵

Another study was done by Zhang et al in which 26 patients underwent laparoscopic myomectomy. Simultaneous morcellator *in situ* was used to remove fibroids which were more than 9 cm in size. There were no serious complications and hospital stay was not different for fibroids of different sizes.¹⁶

A study was done by Chang et al in which they compared the results of simultaneous laparoscopic uterine artery ligation and laparoscopic myomectomy for symptomatic myomas with a without *in situ* morcellation. No major complication was noted during morcellation in both groups. Improvement of symptoms was similar in both groups. Follow-up was done until 24 months postoperatively. They observed shorter surgical time in the group in which *in situ* morcellation of the myoma was done without enucleation.¹⁷

In a retrospective study done by Rosenblatt et al, 51 patients underwent laparoscopic supracervical hysterectomy with transcervical morcellation. They found this procedure efficient and safe.¹⁸

Tissue Retrieval in Hand-Assisted Laparoscopic Surgery

Hand-assisted laparoscopic living donor nephrectomy was done in 100 cases in which donor kidney was retrieved by surgeon's hand after laparoscopic nephrectomy through a specially designed hand assist device. Advantage of this technique was that there was shorter hospital stay, less ileus and postoperative pain.⁹

In a study done by Kakinoki et al, 28 patients underwent for HALS splenectomy. Out of these, one patient suffered from intraoperative hemorrhage and two patients had postoperative wound infection.¹⁹

Tissue Retrieval through Colpotomy (Transvaginal)

Transvaginal removal of large organs, like spleen, kidney and gallbladder with large stones, has been performed successfully.²⁰

Mofid et al studied 1,281 patients who underwent notes procedure from 2007 to 2011. In 222 patients, cholecystectomy of appendectomy was done through transvaginal route. Twelve patients out of these need additional abdominal trocar for drainage system, 0.7% intraoperative complications while two patients had postoperative complications, (abscess in pouch of Douglas and biliary fistula). A total of 88% patients did not have any postoperative complications, like vaginal bleeding, incisional hernia, wound infection or sexual dysfunction.²¹

A 2 years prospective study done by Pillai and Yoong in which they studied the use of endobag to remove the benign ovarian mass through colpotomy. There was no spillage of the cyst and no intraoperative or postoperative complication observed.⁵

Panait et al performed transvaginal notes procedure on 17 morbid obese patients. There was no significant difference in operative time in morbid obese patients. These

patients had better cosmesis, decreased postoperative pain, faster recovery and early return to work.²²

Wyman et al described robotic-assisted hysterectomy and bilateral salpingo-oophorectomy through transvaginal tissue retrieval by using anchor tissue retrieval system. These patients were having atypical endometrial hyperplasia. There was no split or tear in the sac and this system minimized the exposure of cancer bearing tissue to the pelvis.⁴

DISCUSSION

With advent of minimally access surgery by laparoscopy, the major challenge has been to find the easy and safe method of tissue retrieval from the surgical site. Enlargement of trocar incision site is against the MAS and various methods have been employed to overcome this problem. It is important to retrieve the tissue from the abdominal cavity in such a way so it will not cause infection, implantation of tumor cells or spillage of the contents into the abdominal cavity or tissue retrieval site. For this purpose, various types of endobags have been described. There are purpose built commercially available endobags but are expensive. Various do it yourself endobags have been described in literature which claim to be inexpensive and safe for tissue retrieval during MAS. These include endobags made of surgical glove or readily available polythene pouches available in operation theater. Although, these are inexpensive but there have been reports of rupture of these bags leading to spillage of contents. Endobags cannot be used to retrieve large specimen and in such conditions the specimen has to be fragmented or morcellated. An interesting technique is described by Ghezzi et al and Schellpfeffer in which a polythene bag is used to draw the large specimen into the mouth of the trocar port and then forceps are used to morcellate and retrieve the tissue without enlarging the port site as well as protecting the port site from contact of the specimen.^{3,13}

Morcellator (mechanical or thermal) can be used in cases, where tissue is supposed to be benign in nature. Morcellator should be used with caution in any suspected malignancy and preferably specimen should be morcellated in a rip proof bag whenever possible.¹ In various studies, morcellator has been found safe and time saving device for tissue retrieval during laparoscopic surgery.¹⁵⁻¹⁸

HALS is another method used to retrieve large size tissue from the abdominal cavity. This method has been used to retrieve kidney after nephrectomy and large pieces of colon after hemicolectomy. Studies have shown this method to be less traumatic with less postoperative complications and early return to work.^{9,19}

Tissue retrieval through colpotomy has been known since long and now with the advent of MAS this has become an important route for large-sized specimen retrieval.²⁰ Naturally, this method is only available in females. This procedure can be used in morbid obese patients with good results.^{21,22} In robotic-assisted laparoscopic surgery, colpotomy wound can be closed laparoscopically.²² Tissue retrieval through colpotomy has been found to be safe and easy to learn method. There are minimal intraoperative and postoperative complications, decreased hospital stay and early return to work.^{4,5,22}

CONCLUSION

Tissue retrieval in MAS is an important issue. Various methods are being used and new technologies are being developed to make this procedure safe for the patient. For smaller specimens, transumbilical route using endobag technique and for larger specimens retrieval through colpotomy seems reasonable at this moment. Use of morcellator is time saving but can only be used in for tissues which are supposed to be benign in nature. For large tissue resections and organ removal, HALS shows good promise.

REFERENCES

1. Mishra RK. Laparoscopic general surgical procedures. Textbook of practical laparoscopic surgery (1st ed). New Delhi: Jaypee Brothers Medical Publishers 2008;143-250.
2. Shamshirsaz AA, Shamshirsaz AA, Vibhakar JL, Broadwell C, Van Voorhis BJ. Laparoscopic management of chemical peritonitis caused by dermoid cyst spillage. JSLs 2011;15(3): 403-05.
3. Schellpfeffer MA. A novel laparoscopic tissue retrieval device. JSLs 2011;15(4):527-32.
4. Wyman A, Fuhrig L, Bedaiwy MA, Debernardo R, Coffey G. A novel technique for transvaginal retrieval of enlarged pelvic viscera during minimally invasive surgery. Minimally Invasive Surgery 2012;2012:454120.
5. Pillai R, Yoong W. Posterior colpotomy revisited: A forgotten route for retrieving larger benign ovarian lesions following laparoscopic excision. Arch Gynecol Obstet 2010;281(4): 609-11.
6. Ganpule AP, Gotov E, Mishra S, Muthu V, Sabnis R, Desai M. Novel cost-effective specimen retrieval bag in laparoscopy: Nadiad bag. Urology 2010;75(5):1213-16.
7. Turial S, Schier F. The use of a plastic bag from a drain package instead of an endobag in children: A safe effective and economical alternative. Surgical Innovation 2010;17(3): 269-72.
8. Andreas S, Maria M, Wai Y. Methods for specimen removal from the peritoneal cavity after laparoscopic excision. Obstet Gynaecol 2013;15:26-30.
9. Buell JF, Hanaway MJ, Potter SR, Cronin DC, Yoshida A, Munda R, et al. Hand-assisted laparoscopic living-donor nephrectomy as an alternative to traditional laparoscopic living-donor nephrectomy. Am J Transplan 2002;2(10):983-88.

10. Walid MS, Heaton RL. A large fibroid uterus removed with a bipolar morcellator. *Proc Obstet Gynecol* 2011;1(3):11.
11. Box GN, Bessler M, Clayman RV. Transvaginal access: Current experience and potential implications for urologic applications. *J Endourol* 2009;23(5):753-57.
12. Chukwumah C, Zorron R, Marks JM, Ponsky JL. Current status of natural orifice transluminal endoscopic surgery (NOTES). *Curr Probl Surg* 2010;47(8):630-68.
13. Ghezzi F, Cromi A, Uccella S, Siesto G, Bergamini V, Bolis P. Transumbilical surgical specimen retrieval: A viable refinement of laparoscopic surgery for pelvic masses. *BJOG* 2008;115(10):1316-20.
14. Kao CC, Cha TL, Sun GH, Yu DS, Chen HI, Chang SY, et al. Cost-effective homemade specimen retrieval bag for use in laparoscopic surgery: Experience at a single center. *Asian J Surg* 2012;35(4):140-43.
15. Chen SY, Huang SC, Sheu BC, Chang DY, Chou LY, Hsu WC, et al. Simultaneous enucleation and in situ morcellation of myomas in laparoscopic myomectomy. *Taiwan J Obstet Gynecol* 2010;49(3):279-84.
16. Zhang P, Song K, Li L, Yukuwa K, Kong B. Application of simultaneous morcellation in situ in laparoscopic myomectomy of larger uterine leiomyomas. *Med Princ Pract* 2011;20(5):455-58.
17. Chang WC, Chou LY, Chang DY, Huang PS, Huang SC, Chen SY, et al. Simultaneous laparoscopic uterine artery ligation and laparoscopic myomectomy for symptomatic uterine myomas with and without in situ morcellation. *Hum Reprod* 2011;26(7):1735-40.
18. Rosenblatt P, Makai G, DiSciullo A. Laparoscopic supracervical hysterectomy with transcervical morcellation: Initial experience. *J Minim Invasive Gynecol* 2010;17(3):331-36.
19. Kakinoki K, Okano K, Suto H, Oshima M, Hagiike M, Usuki H, et al. Hand-assisted laparoscopic splenectomy for thrombocytopenia in patients with cirrhosis. *Surg Today* 2012 Nov 11.
20. Bingener J, Gostout CJ. Update on natural orifice transluminal endoscopic surgery. *Gastroenterol Hepatol (NY)* 2012;8(6):384-89.
21. Mofid H, Emmermann A, Alm M, von Waldenfels HA, Felixmuller C, Zornig C. Is the transvaginal route appropriate for intra-abdominal NOTES procedures? Experience and follow-up of 222 cases. *Surg Endosc*. Published online on 2013 Feb 8. DOI: 10.1007/s00464-013-2812-z.
22. Panait L, Wood SG, Bell RL, Duffy AJ, Roberts KE. Transvaginal natural orifice transluminal endoscopic surgery in the morbidly obese. *Surg Endosc*. Published online on 2013 Jan 26. DOI: 10.1007/s00464-012-2775-5.

ABOUT THE AUTHORS

Nuzhat Amer (Corresponding Author)

Senior Registrar, Department of Obstetrics and Gynecology, Armed Forces Hospital, Southern Region, Khamis Mushait, Saudi Arabia
e-mail: nuzhatamer@hotmail.com

Muhammad Amer

Senior Registrar, Department of Ophthalmology, Armed Forces Hospital, Southern Region, Khamis Mushait, Saudi Arabia

Rajineesh K Mishra

Head of Minimal Access Surgery, TGO University; Director, India, World Laparoscopy Hospital, Gurgaon, Haryana, India

A Review of the Robotic Radical Prostatectomy Outcomes

Suhani Maharajh

ABSTRACT

Robotic radical prostatectomy was first performed in 2000. The superior range of movement as well as better ergonomics were clear advantages of this technology. This technology and its cost can however only be justified, if it has clear data confirming its equivalence or preferably superiority in management. Open radical retropubic prostatectomy has previously been the gold standard for oncological outcomes in organ confined prostate cancer. Follow-up data showed good 5-year cancer free survival and mortality and Walsh's technique contributed significantly to improvement of quality of life issues, such as sexual function. In spite of improved survival rates with other less invasive modalities, such as brachytherapy and intensity-modulated radiotherapy, the radical prostatectomy is still a popular treatment choice as there is long-term data to support evidence of durable cancer control. The recovery and cost of the open procedure has often been a disadvantage. Minimal access surgery was able to overcome these issues with good surgical outcomes. Robotic surgery may well be the next step in surgical and technological revolution and has the possibility of making minimally invasive surgery accessible to surgeons with less laparoscopic experience. This review will attempt to assess the outcomes of robotic surgery to determine if it is indeed a feasible option for the treatment of organ confined prostate cancer, by assessing the surgical outcomes.

Keywords: Robotic radical prostatectomy, Outcomes, Trifecta, Continence, Erectile function, Complications, Oncologic outcomes, Positive surgical margins.

How to cite this article: Maharajh S. A Review of the Robotic Radical Prostatectomy Outcomes. *World J Laparosc Surg* 2013;6(2):69-73.

Source of support: Nil

Conflict of interest: None declared

INTRODUCTION

With the evolution of disease patterns, increased awareness around screening and widespread availability of prostate-specific antigen (PSA), prostate cancer is increasingly being recognized at the stage of organ confined disease.¹ It is a disease associated with the elderly males, who often have comorbid conditions.² Screening from the age of 40, as per the EUA recommendations, has resulted in younger males in the sexually active age group being diagnosed with this disease. Preservation of continence and sexual function are both prime considerations in this age group of individuals. The previous gold standard of open radical prostatectomy has shown durable excellent oncologic outcomes, but due to the complexity of this procedure, quality of life issues such as erectile function and continence rates, have produced variable results, affected by the surgeon experience, amount

of annual surgeries in the respective centers as well as patient and cancer-specific variables.

The laparoscopic procedure with better visualization of nerve anatomy and superior reconstruction of the pelvic floor anatomy has shown good results over the past years.³ The procedure has a considerable learning curve in spite of its clear benefits of lower hospital stay and transfusion rate.³ However, technology may offer an advantage in terms of the learning curve. The introduction of robotic surgery by Da Vinci robotic surgery (Fig. 1) has made these operative skills more attainable goal with a reportedly less steep learning curve. Despite the lower hospital stay with robot-assisted radical prostatectomy (RARP), the considerable cost still overshadows any apparent benefit to the technology.³

However, if evidence-based evaluation were able to show clear benefits in terms of oncological and quality of life outcomes, the cost could be at least justified, in the limited centers that are able to afford this revolutionary technology.

This article will review the recent literature regarding robotic radical prostatectomy, and examine whether it is a superior treatment option in the treatment of organ confined prostate cancer.

MATERIALS AND METHODS

Keywords pertaining to the topic were used to identify relevant literature, through the use of search engines (PubMed Central, Google scholar and Medline). The MESH keywords utilized included the following:

- Robotic radical prostatectomy (Fig. 2)
- Outcomes




Fig. 1: da Vinci robot (Source: <http://www.daviscrump.com/>)

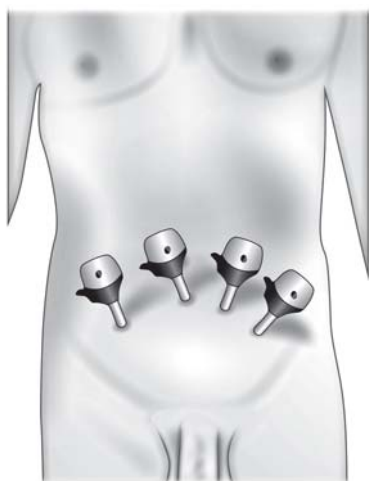


Fig. 2: Port placement in robotic radical prostatectomy
(Source: <http://www.avantgardeurology.com/>)

- Trifecta
- Continence
- Erectile function
- Complications
- Oncologic outcomes
- Positive surgical margins.

Relevant articles identified through the previously mentioned search engines were identified. MESH keywords were to identify the most relevant articles, and only these articles are included in the review. Fifteen articles were included in the review. Prospective and retrospective studies were both included in this review. In addition, relevant articles were cross-referenced from the articles identified. Cohort studies were also used, which compared open and laparoscopic approaches to the robotic radical prostatectomy outcome. Only English articles that were published from 2010 until current date were included for analysis.

Results were analyzed by the author and summarized in data capture sheet for analysis.

Endnote citation manager was used for the purposes of referencing and downloaded directly from the respective articles and search engines.

RESULTS

Eight articles were identified that dealt with complications. Not all articles defined whether complications were minor or major, whether transfusions were included and whether or not they were graded according to the Clavien system or not (Table 1).

The following 10 studies includes one study by Kaffenberger¹¹ et al that assessed the outcomes in salvage prostatectomy postablative therapy (Table 2).

There were different definitions of failure and recurrence in each of the studies below. The duration of follow-up also varied as specified in each case (Table 3).

Erectile preservation rates differed based on age, preoperative erectile function, nerve sparing techniques and the early use of PDE-5 inhibitors, accounting for the differences seen below (Table 4).

Differences in preservation of the puboprostatic ligaments, the use of the Rocco suture and reconstruction of the posterior rhabdosphincter, account for the differences in rates below (Table 5).

DISCUSSION

Prostate carcinoma is now the most common solid neoplasm of the male population.¹⁸ With a shift of the population dynamics in the developed, world as well as the widespread awareness of PSA² and prostate cancer and Men's health awareness, there has been a shift in the profile of diagnosed patients. Prostate carcinoma is a major cause of morbidity and mortality and is now increasingly being diagnosed in male patients at an earlier stage when it is organ-confined.²

Disease has physical, social and psychological ramifications on the well-being of an individual. This is extremely relevant in the treatment of prostate cancer as it has the potential to have debilitating consequences on all of these aspects of health, as the outcomes of surgery can have adverse effects on sexual and voiding function, with adverse psychological sequelae and patient dissatisfaction.¹⁹

The trifecta outcome²⁰ is used to describe the triad of oncological, potency and continence outcomes. These areas are important to assess outcomes in surgery. Quality of life

Table 1: Complication rate results

References	Complications (%)
Bouchier-Hayes ⁴ et al (n = 125)	12.8
Doumerc ⁵ et al (n = 212)	1.8
Jayram ⁶ et al (n = 148)	3.4
Padanavo ⁷ et al (n = 153)	7.8
Patel ⁸ et al (n = 1,100)	8.6
Sharma ⁹ et al (n = 500)	5.6
Yip ¹⁰ et al (n = 235)	7

n: patient numbers in individual studies

Table 2: Results for positive surgical margins

References	Positive surgical margins (%)
Bouchier-Hayes ⁴ et al (n = 125)	32
Doumerc ⁵ et al (n = 212)	21.3
Jayram ⁶ et al (n = 148)	20.9
Kaffenberger ¹¹ et al (n = 34)	26
Leitao ¹² et al (n = 171)	23.4
Novara ¹³ et al (n = 242)	31
Padanavo ⁷ (n = 153)	35
Patel ⁸ et al (n = 1,100)	10.6
Sharma ⁹ et al (n = 500)	23-26
Yip ¹⁴ et al (n = 235)	20.7

n: patient numbers in individual studies

Table 3: Summary of incidence of biochemical recurrence and failure

References	Biochemical recurrence (%)	Biochemical failure (%)
Bouchier-Hayes ⁴ (n = 125)	7.6 (12 months)	18 (16 months)
Kaffenberger ¹⁵ (n = 34)		
Liss ¹⁶ (n = 289)	15.7 (60 months)	2 (9 months)
Jayram ⁶ (n = 148)	21.3 (24 months)	
Padanavo ⁷ (n = 153)		

n: patient numbers in individual studies

issues can no longer be viewed as separate entities from disease treatment and side effects. Radical retropubic prostatectomy has been previously performed by the open surgical route and after the detailed anatomic description of nerve sparing radical prostatectomy by Walsh, has had good outcomes in this regard.⁸ However, as result of improvements in minimal access surgery, similar outcomes have been reported in the literature with laparoscopic radical prostatectomy.²¹

The first robotic-assisted laparoscopic surgery was performed in 2001.²¹ Data has confirmed that there is a shorter recovery, shorter hospital stay and a lower transfusion rate¹³ with the procedure, but this must be counterbalanced against the high operating and maintenance costs of the robot.³

The complication rates in this review varied from 1.8 to 12.8%. This is comparable to the accepted complication rate in open retropubic radical prostatectomy, the previously considered gold standard. The articles did not include a more

detailed breakdown in these complications as to ascertain the degree of morbidity. Three of the studies were from centers that involved the first 200 cases, and hence incorporate the learning curve and are therefore still encouraging, that there was no statistically significant increase in the incidence of the complications, even with less experienced surgeons. There were also no reported mortalities in these studies.

Positive surgical margins ranged from 10.6 to 35%. The reported prevalence in the literature ranges from 10 to 45%.⁹ This is therefore in the acceptable range. Of note, is that in the study by Kaffenberger et al¹⁵ which assessed positive surgical margins in salvage radical prostatectomy, positive surgical margin rate was 26%. This suggests that even in patients that failed previous modalities, RARP still has an acceptable positive surgical margin²¹ rate that is comparable to that of cases where radical prostatectomy was offered at the outset of treatment. However, the fact that this has a smaller representative patient population makes this data difficult to interpret. The Gleason grade and D'Amico classification was not specified in all series, although there was correlation noted by specific groups between higher stage disease, positive surgical margins and high risk disease. This has been confirmed by review of the current literature as well.²²

Although positive surgical margins were noted, this did not correlate with the disease recurrence. Pandanavo⁷ et al had two recurrences, both of whom had negative surgical margins. Across these studies the apex and base were the most common sites of recurrence. This concurs with previous literature. It also correlates with the PSA and the prostate volume as well.¹⁰ It would be of value to know if these cases of positive surgical margins were confined to cases of nerve sparing techniques, but this information was not specified.

With regards to biochemical recurrence and failure, it is difficult to standardise and analyze this data, as different follow-up periods were used. The incidence however did correlate with higher stage disease²³ and has similar rates to other studies.²⁴

The erectile preservation range varied across the studies. Of note, the high volume center with 1,100⁸ cases had excellent potency rates, in spite of using a strict definition

Table 4: Preservation of erectile function

References	Erectile function preservation (%)
Bouchier-Hayes ⁴ et al (n = 125)	72
Decastro ¹⁷ et al (n = 140)	60
Jayram ⁶ et al (n = 148)	51.7
Leitao ¹² et al (n = 171)	69.1
Novara ¹³ et al (n = 242)	60
Patel ¹⁴ et al (n = 1,100)	96.6
Sharma ⁹ et al (n = 500)	75
Yip ¹⁰ et al (n = 235)	37.3

n: patient numbers in individual studies

Table 5: Preservation of continence

References	Continence preservation (%)
Bouchier-Hayes ⁴ (n = 125)	93
Decastro ¹⁷ (n = 140)	55.7
Jayram ^{6,11} (n = 148)	91.5
Kaffenberger ¹¹ (n = 34)	39
Leitao ¹² (n = 171)	90.3
Novara ¹³ (n = 242)	89
Padanavo ⁷ (n = 153)	98
Patel ⁸ (n = 1,100)	97.9
Sharma ⁹ (n = 500)	91.3
Yip ¹⁰ (n = 235)	72.5

n: Patient numbers in individual studies

n(erections adequate for intercourse with use of phosphodiesterase-5 inhibitors, but not other assistive devices). This would suggest that more experience would improve potency outcomes. However, this could also be due to the patient profile undergoing robotic retropubic radical prostatectomy in this series. Also the study did note a better potency rate in younger patients, and this could therefore have a significant impact on outcomes. The range reported here is consistent with that in literature of studies with nerve preserving radical prostatectomies.⁸ However, most of these patients had concomitantly used phosphodiesterase-5 inhibitors. The use of early rehabilitation of erectile function was not specified across all these studies, and it is therefore difficult to compare these results. More literature, and a randomized controlled trial on the use of phosphodiesterase-5 inhibitor's impact on outcomes of erections in bilateral vs unilateral nerve sparing procedures, would be helpful in this regard. Most of these techniques used athermal dissection and the principles of nerve sparing procedures (although not specified). In addition the use of the intrafascial vs interfascial dissection planes of nerve dissection affects potency outcome. The specifics of this were not provided and hence its impact on outcomes cannot, be assessed in this review. However, different tools were used as assessment of the erectile function. Most often questionnaires were used. The outcomes are therefore, reporter dependant, and therefore reliability of this is, patient dependant.

The continence rate in this review is consistent with the rates reported in the literature.⁸ The one study by Kaffenberger et al¹¹ reports a considerably lower rate of continence of 39%. However, it must be borne in mind that this was in a series of salvage radical prostatectomies, postablative treatment. This may impact on the surgical outcomes. Across the studies, the definition of continence differed with some defining it as pad free⁸ and the rest allowing for one pad. There were differences in the duration of follow-up, as well. Most studies were followed up until at least 1 year. Prolonged follow-up should not provide an improved rate of continence noted, however. There were also differences in the use of continence preservation techniques in the different series.

Patel et al⁸ reconstructed the rhabdosphincter and used periurethral suspension stitches. This may have contributed to the excellent continence rates noted in this large series.¹² Leita et al¹² preserved the puboprostatic ligaments and these may contribute to their results.

CONCLUSION

RARP has outcomes that are similar to laparoscopic radical prostatectomy. The cost can however be a prohibitive factor.

Although the outcomes of this procedure have curtailed the in-hospital stay, it cannot counterbalance the cost of this procedure until sufficient data shows superior outcomes of this procedure. This review shows that although there is no sacrifice of trifecta outcomes, no clear benefit over conventional laparoscopy was demonstrated. Studies that directly compare the learning curve of robotic radical prostatectomy and laparoscopic radical prostatectomy may help in settling this debate and providing motivation for robotic radical retropubic prostatectomy.

REFERENCES

1. Nordstrom T, Aly M, Clements MS, Weibull CE, Adolfsson J, Gronberg H. Prostate-specific antigen (PSA) testing is prevalent and increasing in Stockholm County, Sweden, despite no recommendations for PSA screening: Results from a population-based study, 2003-2011. *Eur Urol* 2013;63(3):419-25.
2. Sapira MK, Obiorah CC. Age and pathology of prostate cancer in South-Southern Nigeria: Is there a pattern? *Med J Malaysia* 2012;67(4):417-19.
3. Bolenz C, Gupta A, Hotze T, Ho R, Cadeddu JA, Roehrborn CG, et al. Cost comparison of robotic, laparoscopic, and open radical prostatectomy for prostate cancer. *Eur Urol* 2010; 57(3):453.
4. Bouchier-Hayes DM, Clancy KX, Canavan K, O'Malley PJ. Initial consecutive 125 cases of robotic assisted laparoscopic radical prostatectomy performed in Ireland's first robotic radical prostatectomy centre. *Ir J Med Sci* 2012;181(1):21-25.
5. Doumerc N, Yuen C, Savdie R, Rahman MB, Rasiah KK, Pe Benito R, et al. Should experienced open rostatic surgeons convert to robotic surgery? The real learning curve for one surgeon over 3 years. *BJU Int* 2010;106(3):378-84.
6. Jayram G, Decastro GJ, Large MC, Razmaria A, Zagaja GP, Shalhav AL, et al. Robotic radical prostatectomy in patients with high-risk disease: A review of short-term outcomes from a high-volume center. *Journal of Endourology* 2011;25(3): 455-57.
7. Padavano J, Shaffer L, Fannin E, Burgers J, Poll W, Ward E, et al. Robotic radical prostatectomy at teaching community hospital: Outcomes and safety. *JSLs* 2011;15(2):193-99.
8. Patel VR, Coelho RF, Chauhan S, Orvieto MA, Palmer KJ, Rocco B, et al. Continence, potency and oncological outcomes after robotic-assisted radical prostatectomy: Early trifecta results of a high-volume surgeon. *BJU Int* 2010;106(5):696-702.
9. Sharma NL, Papadopoulos A, Lee D, McLoughlin J, Vowler SL, Baumert H, et al. First 500 cases of robotic-assisted laparoscopic radical prostatectomy from a single UK centre: Learning curves of two surgeons. *BJU Int* 2011;108(5):739-47.
10. Yip KH, Yee CH, Ng CF, Lam NY, Ho KL, Ma WK, et al. Robot-assisted radical prostatectomy in Hong Kong: A review of 235 cases. *J Endourol* 2012;26(3):258-63.
11. Kaffenberger SD, Keegan KA, Bansal NK, Morgan TM, Tang DH, Barocas DA, et al. Salvage robotic-assisted laparoscopic radical prostatectomy: A single institution, 5-year experience. *J Urol* 2013;189(2):507-13.
12. Leitão TP, Papatsoris AG, Mandron E. Extraperitoneal laparoscopic radical prostatectomy: A prospective 2-year single-surgeon experience with 171 cases. *Arab J Urol* 2012;10: 347-532.

13. Novara G, Ficarra V, Mocellin S, Ahlering TE, Carroll PR, Graefen M, et al. Systematic review and meta-analysis of studies reporting oncologic outcome after robot-assisted radical prostatectomy. *Eur Urol* 2012;62(3):382-404.
14. Patel V, Coelho R, Rocco B, Orvieto M, Sivaraman A, Palmer K, et al. Positive surgical margins after robotic assisted radical prostatectomy: A multi-institutional study. *J Urol* 2011;186(2): 511-16.
15. Briganti A, Bianchi M, Sun M, Suardi N, Gallina A, Abdollah F, et al. Impact of the introduction of a robotic training programme on prostate cancer stage migration at a single tertiary referral centre. The trifecta outcome in 300 consecutive cases of robotic-assisted laparoscopic radical prostatectomy according to D'Amico risk criteria: Robot-assisted radical prostatectomy: Five year oncological and biochemical outcomes. *Salvage robotic assisted laparoscopic radical prostatectomy: A single institution, 5-year experience. BJU Int* 2012;39(1):107-13.
16. Liss MA, Lusch A, Morales B, Beheshti N, Skarecky D, Narula N, et al. Robot-assisted radical prostatectomy: 5-year oncological and biochemical outcomes. *J Urol* 2012;188(6): 2205-10.
17. DeCastro GJ, Jayram G, Razmaria A, Shalhav A, Zagaja GP. Functional outcomes in African-Americans after robot-assisted radical prostatectomy. *J Endourol* 2012;26(8):1013-19.
18. Tewari AK, Srivastava A, Sooriakumaran P, Grover S, Desir S, Dev H, et al. Pathological outcomes and strategies to achieve optimal cancer control during robotic radical prostatectomy in Asian-Indian men. *Indian J Urol* 2011;27(3):326-30.
19. Eton DT, Lepore SJ. Prostate cancer and health-related quality of life: A review of the literature. *Psychooncology* 2002;11(4): 307-26.
20. Bianco FJ Jr, Scardino PT, Eastham JA. Radical prostatectomy: Long-term cancer control and recovery of sexual and urinary function (trifecta). *Urology* 2005;66(5 Suppl):83-94.
21. Motttrie A, Gallina A, De Wil P, Thüer D, Novara G, Ficarra V. Balancing continence function and oncological outcomes during robot-assisted radical prostatectomy (RARP). *BJU Int* 2011; 108(6b):999-1006.
22. Barry MJ, Gallagher PM, Skinner JS, Fowler FJ Jr. Adverse effects of robotic-assisted laparoscopic versus open retropubic radical prostatectomy among a nationwide random sample of medicare-age men. *J Clin Oncol* 2012;30(5):513-18.
23. Padavano J, Shaffer L, Fannin E, Burgers J, Poll W, Ward ES, et al. Robotic radical prostatectomy at a teaching community hospital: Outcomes and safety. *JSLs* 2011;15(2):193-99.
24. Masterson TA, Cheng L, Boris RS, Koch MO. Open vs robotic-assisted radical prostatectomy: A single surgeon and pathologist comparison of pathologic and oncologic outcomes. *Urol Oncol* 2012 Jan 3. [Epub ahead of print].

ABOUT THE AUTHOR

Suhani Maharajh

Specialist Urologist, Department of Urology, Greys Hospital Pietermaritzburg Urology Complex, Town Bush Road, Kwa-Zulu Natal 3200, South Africa, e-mail: suhanimaharajh@ymail.com

Comparative Study between Harmonic Scalpel and LigaSure Vessel Sealing System: In Open and Laparoscopic Surgery

Vinayak Mishra

ABSTRACT

Background: Energy sources have been an important part of surgery in achieving hemostasis and bloodless field to operate. Nowadays the most recent and commonly used are the bipolar vessel sealing system (LigaSure) and the harmonic scalpel (HS).

Purpose: To do a comparative review between the LigaSure vessel sealing system and harmonic scalpel to make surgery faster, safer and better.

Materials and methods: The literature regarding this review article was searched online on various websites like Google, PubMed, World Journal of Gastrointestinal Surgeons, YouTube. Search words used were LigaSure vs harmonic scalpel, LigaSure vessel sealing system, role of vessel sealer and HS in laparoscopic surgery.

Conclusion: LigaSure vessel sealing system (LVSS) proves to have a hand above the HS as it depends of the surgeon's convenience to use which of the energy sources when it comes to handling and maneuverability during surgery resulting in an overall faster, safer and a bloodless experience.

Keywords: LigaSure vs harmonic scalpel, LigaSure vessel sealing system, Role of vessel sealer and harmonic scalpel in laparoscopic surgery.

How to cite this article: Mishra V. Comparative Study between Harmonic Scalpel and LigaSure Vessel Sealing System: In Open and Laparoscopic Surgery. World J Laparosc Surg 2013;6(2): 74-76.

Source of support: Nil

Conflict of interest: None declared

INTRODUCTION

Energy sources have been an important part of surgery in achieving hemostasis and bloodless field to operate. The energy sources are required to cut, coagulate, desiccate, dissect and evaporate tissue. There have been tremendous upgrades in the technology used in energy sources which targets on better, faster and safe hemostasis with minimal lateral thermal spread or damage. Lateral thermal damage confers to the damage to the tissues just adjacent to the target site. Nowadays, the two most used energy sources used are the LigaSure vessel sealing system (LVSS) (Fig. 1) and the harmonic scalpel (HS) (Fig. 2).

LVSS manufactured by Covidien under the brand name of Valleylab is a bipolar apparatus for sealing vascular tissues. It seals tissue by administration of high current and

low voltage that of 180 V as compared to conventional electrosurgery. Its unique combination of pressure energy causes fusion of vessels. The fusion is because of melted collagen and elastin in the vessels which forms a permanent, plastic like seal. LVSS has a unique property of active tissue response which is a feedback from tissue that controls the energy delivery and automatically discontinues it when the seal cycle completes. This eliminates the guesswork of operating surgeon and provides minimal lateral thermal damage to approximately 2 mm. There is no sticking of the instruments on tissues with least charring of the tissues. The seal withstands thrice of normal systolic blood pressure. The LVSS generator detects the characteristic of the tissue in the jaws of the instruments and delivers energy accordingly to provide a permanent seal. LVSS promises to provide a secure seal of blood vessels measuring up to 7 mm in diameter. Various probes both for laparoscopic and open surgeries are available which are compatible to this electrosurgical generator.

Harmonic scalpel (HS) is manufactured and marketed by Ethicon across the globe. It uses ultrasonic energy as its principle and, hence, dissection by ultrasonic probes is called ultracision. The HS is a high power system which works at a frequency of 55.5 kHz or 55,500 vibrations/sec. It comprises of a generator, blade and a hand piece. The hand piece has an ultrasonic transducer which consists of stacked piezoelectric crystals sandwiched under pressure among metal cylinders. The sealing of the vessels is achieved due to denatured protein coagulum which occurs due to tamponade and coaptation. The ultrasonic generator converts ultrasonic energy into mechanical energy. HS mainly has three compatible probes both for open and laparoscopic surgery that are the shear, blade and a hook. The shear has opposite silicon padding which the blade and hook lacks. The shear can coagulate vessels up to 5 mm, whereas the hook and blade only 2 mm in diameter. The HS probes reach the temperature of 80°C and even on prolonged use stays below 250°C which is far less than other electrosurgical and laser energy sources resulting in reduced lateral thermal spread and charring. Vibration of the active probe prevents sticking of coagulated tissue over it.

AIMS AND OBJECTIVES

The present study is designed to compare between HS and LVSS in open and laparoscopic surgery.

MATERIALS AND METHODS

The literature regarding this review article was searched online on various websites, like Google, PubMed, World Journal of Gastrointestinal Surgeons, YouTube. Search words used were LigaSure vs HS, LVSS role of vessel sealer and HS in laparoscopic surgery.

DISCUSSION

Kwok SY et al in their double-blinded study did a randomized trial comparing LigaSure and HS hemorrhoidectomy. Forty-nine patients with grades 3 and 4 hemorrhoids admitted for hemorrhoidectomy were selected and randomized into two groups: (1) LigaSure hemorrhoidectomy or (2) HS hemorrhoidectomy. The primary outcomes measured were the analgesic requirement and the postoperative pain score (assessed by an independent assessor). Secondary outcome criteria included the operating time, blood loss, hospital stay, patient satisfaction score, and early and late complications and they concluded that LigaSure hemorrhoidectomy reduces the postoperative pain and operating time compared to the HS hemorrhoidectomy. And, it is a safe, effective procedure for treating grades 3 and 4 hemorrhoids.¹

Smith et al in a prospective comparison of four laparoscopic vessel ligation devices found that the LigaSure had the best overall performance with the highest burst pressure, low thermal spread, fast sealing time, and low smoke production. By contrast, the HS has the lowest thermal spread and smoke production but was slow and had the lowest mean burst pressure.²

Cakan A et al studied the safety and efficacy of the LVSS and HS in sutureless nonanatomical lung resections on 20 adult rabbit lungs in which 1 × 1 cm wedge resections were performed under one-lung ventilation with both LVSS and HS and compared the air tightness and tissue damage caused by them. They found no statistical significant difference when the air tightness for both devices was compared after resection ($p = 0.37$) and concluded that their study LVSS and HS can both be used for peripheral lung resections without any need of further intervention for securing the air tightness, but LVSS was found safer by means of tissue damage when compared with HS in this experimental study.³

Zarebczan B et al did a retrospective study to compare the LigaSure and HS in thyroid surgery. Their study included a total of 231 patients of whom 123 underwent total thyroidectomy and 108 underwent lobectomy. They found that there was a significant decrease in the operative time for both thyroidectomies and lobectomies when the HS was utilized. But in regard to complications, there was no statistically significant difference in the number of transient and permanent recurrent laryngeal nerve injuries, percentage of patients developing hypocalcemia or rate of hematoma development. And, concluded that there was no difference in the rate of complications between the two devices. However, the use of the HS significantly decreased operative time for both thyroidectomies and thyroid lobectomies compared with the LigaSure device.⁴

An inference can also be made from a video available online on the site www.youtube.com, which shows the infrared camera recording of the probes of LVSS and HS which compares the lateral thermal spread of both the instruments, which is more in LVSS as compared to HS (Fig. 3). It might be also due to a slightly bigger probe tip of LVSS as compared to smaller probe tip of HS shear.⁵

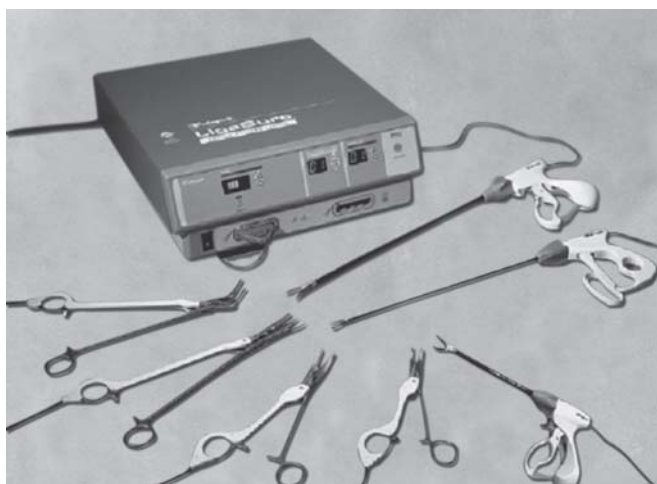


Fig. 1: LigaSure vessel sealing system



Fig. 2: Harmonic scalpel

Two cohort studies comparing a bipolar vessel sealer (BVS) with the ultrasonic coagulating shears (UCS) for laparoscopic colectomy reported a slightly reduced length of surgery and decreased blood loss in the BVS groups.⁶ One of these studies included 30 patients with colon cancer who underwent laparoscopic transverse colectomy and sigmoidectomy using either the electrothermal bipolar vessel sealer (EBVS) (LigaSure) or UCS (harmonic scalpel). The EBVS and the UCS were used for the mesocolon dissection in the transverse and sigmoid colon. The incidence of rebleeding was significantly lower in the EBVS group than in the UCS group for both surgical procedures (0.3 vs 1.2 in transverse colectomy, 0.3 vs 2.0 in sigmoidectomy respectively). The required time for mesocolon dissection was also significantly shorter when the EBVS was used in both laparoscopic transverse colectomy and sigmoidectomy (7.9 vs 18.4, 15.0 vs 27.6 respectively). Another report demonstrated the outcome of 200 consecutive unselected patients who underwent laparoscopic colorectal resections, of which 100 were performed with EBVS (LigaSure) and 100 with UCS (harmonic scalpel).⁷ Only right colectomy (RC), left colectomy (LC) and low anterior resections (LAR) were performed during this study. There were no deaths in either group. One conversion to open surgery and two major complications occurred in the UCS harmonic scalpel group. There were no differences in the mean length of surgery (111 vs 133, 140 vs 176 and 153 vs 201 minutes) or in the mean postoperative hospital stay (5.2 vs 6.1, 6.5 vs 7.1 and 6.8 vs 7.3 days) for RC, LC and LAR between EBVS LigaSure group and UCS harmonic scalpel group respectively. There were, however, differences in the mean

blood loss: 115 vs 370, 150 vs 455 and 185 vs 495 ml for RC, LC and LAR between the EBVS LigaSure group and the UCS harmonic scalpel group respectively.^{6,7}

CONCLUSION

After reviewing the above articles, we found that LVSS as compared to HS, LVSS provides a better, safer and much secure seal than HS that is up to 7 mm. The postoperative pain, when used in open surgery, is less as compared to HS. Even blood loss was comparatively less while using LVSS than HS. HS made the surgery faster with low smoke production as compared to LVSS. Lateral thermal spread of HS is quite less as compared to LVSS but LVSS as compared to other electrosurgical generators was quite less. At the end though LVSS proves to have a hand above the HS, it depends of the surgeon's convenience to use which of the energy sources when it comes to handling and maneuverability during surgery resulting in an overall faster, safer and a bloodless experience.

REFERENCES

1. Kwok SY, et al. A double-blind, randomized trial comparing LigaSure and harmonic scalpel hemorrhoidectomy. *Dis Colon Rectum* 2005 Feb;48(2):344-348.
2. Smith R, Pasic R. The role of vessel sealing technologies in laparoscopic surgery. *Surg Technol Int* 2008;17:208-212.
3. Cakan A, Yoldas B, Samancilar O, et al. LigaSure vessel sealing system versus harmonic scalpel for sutureless nonanatomical pulmonary resections in a rabbit model. Which one is safer? *Eur Surg Res* 2009;43(1):24-28.
4. Zarebczan B, Mohanty D, Chen H. A comparison of the LigaSure and harmonic scalpel in thyroid surgery: a single institution review. *Ann Surg Oncol* 2011 Jan;18(1):214-218.
5. RandDMagazine. Available from: <http://www.youtube.com/watch?v=TtEZtvUBMdU>. On Jun 17, 2009.
6. Takada M, Ichihara T, Kuroda Y. Comparative study of electrothermal bipolar vessel sealer and ultrasonic coagulating shears in laparoscopic colectomy. *Surg Endosc* 2005;19(7):226-228.
7. Campagnacci R, de Sanctis A, Baldarelli M, Rimini M, Lezoche G, Guerrieri M. Electrothermal bipolar vessel sealing device vs ultrasonic coagulating shears in laparoscopic colectomies: a comparative study. *Surg Endosc* 2007 Sep;21(9):1526-1531.

ABOUT THE AUTHOR

Vinayak Mishra

Laparoscopic Surgeon, Department of Minimal Access Surgery Hanuman Endosurgery Center, Lucknow, Uttar Pradesh, India, Phone: 8853042226, e-mail: drvinayakmishra@gmail.com



Fig. 3: Screenshots taken from infrared recordings of probes of HS and LVSS respectively

Prevention of Port-Site Metastasis in Gynecologic Malignancies

Tânia Ornelas Freitas, Raquel Maciel Barbosa

ABSTRACT

Port-site metastasis is a major complication of surgical laparoscopy for gynecologic oncology and has been reported in literature with an incidence of 1.1 to 16%. Factors that contribute for development of port site can be divided in three categories: operative related, wound related and tumor related. With this review, the authors pretend to report the ideal surgical conditions, laparoscopic environment and means of prevention to decrease risk of port-site metastases in gynecologic malignancies.

Keywords: Port-site metastasis, Prevention, Gynecologic malignancies.

How to cite this article: Freitas TO, Barbosa RM. Prevention of Port-Site Metastasis in Gynecologic Malignancies. *World J Laparosc Surg* 2013;6(2):77-80.

Source of support: Nil

Conflict of interest: None declared

INTRODUCTION

Laparoscopy is an established technical option for the diagnosis, staging and treatment of several oncologic pathologies.¹ The early optimism after the introduction of this approach was followed by the doubts based on the observation of port-site metastasis after laparoscopic surgery for neoplastic diseases.² In 1978, port-site metastasis was defined for the first time, subsequent to laparoscopy in a patient with ovarian cancer. Port-site metastasis is a major complication of surgical laparoscopy for gynecologic oncology and has been reported in literature with an incidence of 1.1 to 16%.³ Prospective studies show that it is possible to keep the incidence of abdominal wall metastases to about 1% comparable to open surgery.⁴ Etiology of port-site metastases is multifactorial. Factors can be divided in three categories: operative related, wound related and tumor related. Operative-related factors include the gas used, the effect of gas turbulence in long laparoscopic procedures, the high pressure pneumoperitoneum, long-operative procedure, tumor manipulation, local trauma and individual surgical skills. Wound-related factors are forced extraction of unprotected tissue and contamination from instruments during tumor dissection. Tumor-related factors are the biologic properties of the tumor, embolization of exfoliated cells and tumor stage.^{1,3,5-8}

AIM

The aim of this review is to report ideal surgical conditions, laparoscopic environment and means of prevention to

decrease risk of port-site metastases in gynecologic malignancies.

MATERIALS AND METHODS

The authors searched in Medline database for English-language and French-language articles using the keywords 'laparoscopic port-site metastases', 'prevention of laparoscopic port-site metastases', 'laparoscopic port-site metastases in ovarian cancer', 'laparoscopic port-site metastases in endometrial cancer', 'laparoscopic port-site metastases in cervical cancer' and 'laparoscopic port-site metastases in borderline ovarian tumors'.

Additional articles were obtained based on the bibliographic cross-reference of the initial articles reviewed.

There were identified >400 articles in English published during the last 51 years regarding the history, incidence, etiology and prevention of port-site metastases. According to the aim of this revision, 28 articles were selected and reviewed.

RESULTS

The development of port-site metastases following laparoscopic resection of various malignancies continues to be a disturbing issue for laparoscopic surgeons.⁹

Mostly studies intend to investigate the factors potentially responsible for the spread of cancer cells in laparoscopic surgery.

Based on experimental studies and clinical reports, many theories have been proposed to account for the ability of tumor to spread to surgical wounds. The tumor cell entrapment hypothesis, which was proposed in 1989, suggests that free cancer cells are able to implant on raw tissue surfaces including damaged peritoneal surfaces. Postoperatively, these areas become covered by a fibrinous exudate which could serve to protect the tumor cells from destruction by the normal defense mechanisms. This theory is supported by studies that have demonstrated tumor cells at concentrations of up to 26% in wound washings and have shown the recovery of tumor cells from the gloves and instruments used during surgery. Hypotheses specific to laparoscopy include exfoliation and spread of tumor cells by laparoscopic instruments, direct implantation at the trocar site by frequent changes of instruments, direct implantation from the passage of the specimen, the presence of the pneumoperitoneum, which can create a 'chimney effect'

that causes an increase in the passage of tumor cells at port sites and preferential growth of malignant cells at areas of laparoscopic peritoneal perforation.^{10,11}

A study performed to evaluate the variables in the spread of tumor cells to port sites in swines demonstrated that some strategies, such as increasing insufflation pressure, reducing episodes of desufflation and gas leaks, and using frequent intra-abdominal lavage may help to reduce the numbers of viable tumor cells displaced to port sites during laparoscopic surgery for intra-abdominal malignancy.¹²

Another study performed in rat model evaluated the effects of carbon dioxide (CO₂) pneumoperitoneum and wound closure technique on port-site tumor implantation. This study suggests that closure technique (skin closure alone vs all three layers) may influence the rate of port-site tumor implantation. The rate of tumor implantation was found to be significantly higher for skin closure alone.¹³ Another experimental study in rat model proved that the choice of helium as insufflation gas reduces the incidence of port-site metastases and the degree of intraperitoneal tumor spread.¹⁴ However, the use of helium carries a possible risk of lethal gas embolism.⁴

Several clinical reports have suggested that gasless laparoscopy may aid in the prevention of port-site metastases by reducing tumor dissemination created by the carbon dioxide CO₂ pneumoperitoneum. However, *in vitro* research involving a laparoscopic model performed on colorectal cancer cells showed that malignant cells were not identified in the CO₂ exhaust, but were found on the laparoscopic instruments used. Similarly, a study of the instruments, port cannula, and CO₂ gas of 12 patients undergoing staging laparoscopy for pancreatic cancer showed extremely low levels of free-floating tumor cells when compared with the cell content found on the cannula and instruments. In both cases, the authors concluded that the finding of malignant cells on the ports was a result of direct contamination by the instruments and not from dispersion of malignant cells by the CO₂ gas.¹⁵ In a prospective randomized study in rats using a xenograft ovarian cancer model, port-site metastases were found to be significantly higher in the gasless laparoscopy group compared with that in a group that had laparoscopy with a CO₂ pneumoperitoneum.¹⁶

An article that reviewed all reported cases of laparoscopic port-site metastases in patients with gynecological malignancies revealed that 71% of port-site recurrences were isolated in the tissue-manipulating port.⁸ This observation also highlights the importance of the usage of protected tissue retrieval.

Other studies were performed to evaluate if the irrigation of port sites are efficient for the prevention of port-site metastases.¹⁷

One study evaluated the effect of topical application of oxaliplatin on the development of port-site metastases in an experimental murine model. Intramuscular topical application of oxaliplatin did not decrease the incidence of port-site metastasis, but a tendency of declination was observed.⁹

In another article reported the results of incidence of port-site metastases with the irrigation after completion of the pneumoperitoneum with povidone-iodine, a mixture of tauridine and heparin or sodium chloride in rat models. No difference in tumor growth at trocar wounds was found between any type of irrigation and controls in both experiments.¹⁸ However, another study has shown a significant reduction in port-site metastases when diluted povidone-iodine was instilled in the peritoneal cavity in a rat model.¹⁶

Cell adhesion molecules integrin and CD44 play an important role in the development of port-site metastasis. According to an investigative study in a murine model, intraperitoneal injection of antiadhesion molecules can prevent port-site metastasis.¹⁹

Another study investigated the antiproliferative effect of aspirin and indomethacin on tumor cells *in vitro* and *in vivo* and the potential of these drugs to inhibit port-site and intraperitoneal metastases. Despite promising *in vitro* studies, this study does not suggest any clinical therapeutic value associated the use of aspirin or indomethacin for the prevention of the spread of tumor following the spillage of cells into the peritoneal cavity at laparoscopic surgery.²⁰

Several authors have suggested that the presence of ascites may be a contraindication to performing laparoscopy in patients with known or suspected malignancy. Specifically, a review of the literature of all cases of port-site metastases demonstrated the presence of ascites to be significantly associated with the early occurrence of port-site metastases, and another study has demonstrated that patients with ovarian cancer who developed port-site metastases after undergoing laparoscopy tended to have larger amounts of ascitic fluid present at the time of surgery.²¹ Specific factors that were shown to be significantly associated with the rapid development of port-site metastases postoperatively included the diagnosis of ovarian malignancy, the presence of ascites and noncurative surgery. The early onset of postoperative chemotherapy has been advocated by several authors that have suggested that patients with a longer duration between laparoscopy and postoperative chemotherapy may be more likely to develop port-site metastases.²²

A recent study presented clinical evidence to prove that port-site metastases are likely to be due to the hematogenous spread of tumor cells. In this same study, the authors propose

that port-site metastasis could be a likely existence of circulating tumor cells at the time of surgical trauma of penetrating nature, i.e. port site or injection site, which manifest in some patients depending upon their immune response.²³

DISCUSSION

Proper surgical technique in tumor handling following rigorous oncological principles is the key to good surgery with low recurrences and excellent survival rates. Some unusual cases reported in literature highlight the important role that tumor and host biologic mechanisms play in the development of port-site metastasis.²⁴ Whether or not patients with malignancy would benefit from a gasless laparoscopy approach remains controversial and further research is needed in this area.¹⁶

According to the review of literature, the prophylactic measures proposed to avoid the development of port-site metastases after laparoscopy in gynecologic malignancies are as follows:

- Preoperative measures^{7,25}
 - Proper patient selection
 - Avoidance of laparoscopic surgery, if ascites is present
 - Compliance guidance and adequate equipment for advanced laparoscopic surgery
 - Knowledge of the principles of prevention in the event of intraoperative discovery of malignant disease
 - Adequate duration of the procedure
 - Proper training of the surgeon
- Technical measures^{1,3,25-28}
 - Protected puncture of ovarian cyst
 - Resection without rupture of an ovarian cyst (in case of rupture-aspiration and extensive washing)
 - Minimal tumor manipulation
 - Resection of the tumor with adequate margin
 - Peritoneal lavage with heparin in order to avoid adhesion of free cells or lavage with cytotoxic solutions
 - Use of protective bags for tissue retrieval
 - Avoiding CO₂ leaks and sudden desufflations
 - Use of heated and humidified CO₂
 - Exsufflation of the peritoneum before removal of the ports
 - Drainage placement, if needed, before abdomen deflation
 - Irrigation of ports with heparin or povidone-iodine solution before removal
 - Administration systemic or intraperitoneal of methotrexate

- Closure of all abdominal layers including the peritoneum
- Early chemotherapy.

CONCLUSION

Laparoscopic port-site metastases are a potential complication of laparoscopy in patients with gynecological malignancies, even in patients with early-stage disease.

Although the etiology is not yet understood, a number of factors are contributory. All efforts should be made to prevent port-site metastases.

The risk of port-site metastases remains low, provided that surgeons rigorously adhere to the principles of oncological surgery.

ACKNOWLEDGMENT

I would like to thank Professor Rajneesh Mishra, World Laparoscopy Hospital, New Delhi, for his esteem support.

REFERENCES

1. Martinez J, Targarona EM, Balagué C, Pera M, Trias M. Port-site metastasis. An unresolved problem in laparoscopic surgery. A review. *Int Surg* 1995 Oct-Dec;80(4):315-321.
2. Spiridakis K, Panagiotakis G, Krasoniklakis G, Grigoraki M, Chronakis E, Psarakis F, Kokkinakis T, Kandylatus S. Port-site metastasis: a problem in oncologic laparoscopic surgery. Case report and review of the literature. *G Chir* 2010 Apr;31(4):175-179.
3. Özmen B, Şükür YE, Atabekoglu SC, Heper OA, Sönmezer M, Güngör M. Early port-site metastasis during neoadjuvant chemotherapy in advanced stage ovarian cancer: report of two cases. *J Gynecol Oncol* 2011 March 31;22(1):57-60.
4. Reymond M, Schnetder C, Kastl S, Hohenberger W, Kockertlmg F. The pathogenesis of port-site recurrences. *Gastronest Surg* 1998;2:406-414.
5. Agostini A, Mattei S, Ronda I, Banet J, Lécure F, Blanc B. Prevention of port-site metastasis after laparoscopy. *Gynecol Obstet Fertil* 2002 Nov;30(11):878-881.
6. Schaeff B, Paolucci V, Thomopoulos J. Port-site recurrences after laparoscopic surgery. A review. *Dig Surg* 1998;15(2):124-134.
7. Castillo OA, Vitagliano G. Port-site metastasis and tumor seeding in oncologic laparoscopic urology. *Urology* 2008 Mar;71(3):372-378.
8. Ramirez PT, Frumovitz M, Wolf JK, Levenback C. Laparoscopic port-site metastases in patients with gynecological malignancies. *Int J Gynecol Cancer* 2004 Nov-Dec;14(6):1070-1077.
9. Tai YS, Abente FC, Assalia A, Ueda K, Gagner M. Topical treatment with oxaliplatin for the prevention of port-site metastases in laparoscopic surgery for colorectal cancer. *JSLs* 2006 Apr-Jun;10(2):160-165.
10. Sugarbaker P, Cunliffe WJ, Belliveau J, de Bruyn EA, Graves T, Mullins RE, Schlag P. Rationale for integrating early postoperative intraperitoneal chemotherapy into the surgical treatment of gastrointestinal cancer. *Semin Oncol* 1989 Aug;16(4 Suppl V6):83-97.

11. Thomas CG. Tumor cell contamination of the surgical wound: Experimental and clinical observations. *Ann Surg* 1961 May; 153(5):697-705.
12. Brundell SM, Tucker K, Texler M, Brown B, Chatterton B, Hewett PJ. Variables in the spread of tumor cells to trocars and port sites during operative laparoscopy. *Surg Endosc* 2002 Oct; 16(10):1413-1419.
13. Burns JM, Matthews BD, Pollinger HS, Mostafa G, Joels CS, Austin CE, Kercher KW, Norton HJ, Honiford BT. Effect of carbon dioxide pneumoperitoneum and wound closure technique on port site tumor implantation in a rat model. *Surg Endosc* 2005 Mar;19(3):441-447.
14. Gupta A, Watson DI, Ellis T, Jamieson GG. Tumor implantation following laparoscopy using different insufflation gases. *ANZ J Surg* 2002 Apr;72(4):254-257.
15. Schaeff B, Paolucci V. Port-site recurrences after laparoscopic surgery. A review. *Dig Surg* 1998;15:124-134.
16. Nagarsheth NP, Rahaman J, Cohen CJ, Gretz H, Nezhat F. The incidence of port-site metastases in gynecologic cancers. *JSL S* 2004 Apr-Jun;8(2):133-139.
17. Seow-Choen F, Wan WH, Tan KY. The use of a wound protector to prevent port-site recurrence may not be totally logical. *Colorectal Dis* 2009 Feb;11(2):123-125.
18. Wittich P, Mearadji A, Marquet RL, Bonjer HJ. Irrigation of port sites: Prevention of port-site metastases. *J Laparoendosc Adv Surg Tech A* 2004 Jun;14(3):125-129.
19. Hirabayashi Y, Yamaguchi K, Shiraishi N, Adachi Y, Saiki I, Kitano S. Port-site metastasis after CO₂ pneumoperitoneum: role of adhesion molecules and prevention with antiadhesion molecules. *Surg Endosc* 2004 Jul;18(7):1113-1117.
20. Kinugasa S, Smith E, Drew PA, Watson DI, Jamieson GG. Aspirin and indomethacin for the prevention of experimental port-site metastases. *Surg Endosc* 2004 May;18(5):834-838.
21. Wang PH, Yuan CC, Lin G, Ng HT, Chao HT. Risk factors contributing to early occurrence of port-site metastases of laparoscopic surgery for malignancy. *Gynecol Oncol* 1999 Jan;72(1):38-44.
22. Kruitwagen R, Swinkels BM, Keyser K, Doesburg WH, Schijf CP. Incidence and effect on survival of abdominal wall metastases at trocar or puncture sites following laparoscopy or paracentesis in women with ovarian cancer. *Gynecol Oncol* 1996 Feb;60(2):233-237.
23. Chaturvedi S, Bansal V, Kapoor R, Mandhani A. Is port-site metastasis a result of systemic involvement? *Indian J Urol* 2012 Apr;28(2):169-173.
24. Highshaw RA, Vakar-Lopez F, Jonasch E, Yasko AW, Matin SF. Port-site metastasis: The influence of biology. *Eur Urol* 2005 Mar;47(3):357-360.
25. Agostini A, Camatte S, Farthouat P, Blanc B, Lecuru F. Port-site metastases following laparoscopic surgery. *Bull Cancer* 2000 Dec;87(12):902-906.
26. Hubens G. Port-site metastases: where are we at the beginning of the 21st century? *Acta Chir Belg* 2002 Aug;102(4):230-237.
27. Hirabayashi Y, Yamaguchi K, Shiraishi N, Adachi Y, Kitamura H, Kitano S. Development of port-site metastasis after pneumoperitoneum. *Surg Endosc* 2002 May;16(5):864-868.
28. Rané A, Eng MK, Keeley FX Jr. Port-site metastases. *Curr Opin Urol* 2008 Mar;18(2):185-189.

ABOUT THE AUTHORS

Tânia Ornelas Freitas (Corresponding Author)

Resident, Department of Obstetrics and Gynecology, Hospital Dr Nélito Mendonça, Madeira Island, Portugal, e-mail: tcof@portugalmail.pt

Raquel Maciel Barbosa

Department of Gynecology and Obstetrics, Centro Hospitalar do Porto Maternidade Júlio Denis, Porto, Portugal

Vaginal Cuff Dehiscence after Minimal Invasive Hysterectomy: Laparoscopic Surgical Techniques

Raquel Maciel, Tânia Freitas

ABSTRACT

Vaginal cuff dehiscence (VCD) after hysterectomy is an adverse event with potential severe morbidity. Although the data are limited, minimally invasive approaches to hysterectomy, such as total laparoscopic hysterectomy (TLH), may be associated with a higher risk of vaginal cuff dehiscence. The cause for these dehiscences is unknown, and multiple factors may be involved. Internationally, the etiology of VCD is still a matter of concern. Either in its technique (TLH) as in the used technology (electrosurgical colpotomy and/or suturing method), an explanation could be found for the higher incidence of VCD.

This study aims to review laparoscopic surgical techniques in the minimal invasive hysterectomy and its association with VCD.

Keywords: Vaginal cuff dehiscence, Total laparoscopic hysterectomy, Vaginal cuff laparoscopic suture methods, Electrosurgical colpotomy.

How to cite this article: Maciel R, Freitas T. Vaginal Cuff Dehiscence after Minimal Invasive Hysterectomy: Laparoscopic Surgical Techniques. *World J Laparosc Surg* 2013;6(2):81-85.

Source of support: Nil

Conflict of interest: None declared

INTRODUCTION

Vaginal cuff dehiscence (VCD) after hysterectomy is an adverse event with potential severe morbidity.

VCD had complicated gynecologic surgery long before the advent of laparoscopic approach to hysterectomy. In older reviews of vaginal evisceration, most cases that were reported in the literature had occurred after vaginal hysterectomy (63%).¹ However, the distribution of reported cases has changed significantly over the past 5 years.²

The reported incidence of VCD following hysterectomy is, nowadays, approximately 0.24%.³⁻⁵ In a large case series, there were 28 cases of VCD among 11,606 patients (0.24%) who underwent total hysterectomy.⁵ The incidence of VCD after any type of pelvic surgery is 0.03% and varies by surgical approach.⁶

However, the true incidence of VCD after hysterectomy is unknown since:

1. The complication is likely under-reported.
2. Patients with cuff dehiscences may present to a different physician or hospital than for the initial hysterectomy, making data collection difficult and
3. Case reports of VCD generally do not include for comparison in the number of hysterectomies that were not associated with this complication.⁷

Despite the difficulty just described, it is reported that the incidence of VCD after total laparoscopic hysterectomy (TLH) varies between 0.3 and 3.1%.³⁻¹⁰ This is higher compared with the abdominal (AH) and vaginal (VH) approach (0.1–0.3%).^{1,3} Currently, 50% of the cases of VCD that have been reported in the literature occurred after TLH or robotic hysterectomy.

After abdominal total hysterectomy, the vaginal cuff can be sutured closed or left open. In the open technique, the edges of the vaginal cuff seal gradually via granulation. It does not appear that either technique is superior for preventing cuff dehiscence.^{5,12}

In several studies, the vaginal route suturing of vault approach, in the total laparoscopic hysterectomy, is described to reduce the incidence of VCD (0.18%).¹⁰ However, other parameters must be considered are as follows:

1. In TLH, vaginal vault closure by laparoscopic route requires statistically significant less time for completion as compared to vaginal route.
2. Postoperative complications, like vault infection and pain, are suggested to be significantly lower in the laparoscopic route as compared to vaginal route suturing for vault closure.
3. The mean postoperative vaginal length was significantly more in the laparoscopic closure than in the vaginal route suturing of vault approach.¹² Given the fact that transvaginal closure can not always be accomplished in all women, alternatives to this suturing method should be studied.

Since, the continuous increment in the number of hysterectomies performed laparoscopically, the etiology of VCD and explanations for its association with TLH have been subjected to research. Patient characteristics, such as smoking, diabetes, advanced age, radiation therapy and chronic steroid administration, next to precipitating factors, such as sexual intercourse, postoperative cuff infection and/or hematoma and increased abdominal pressure (e.g. coughing, vomiting and straining at toilet) have been addressed with regard to their association with VCD.^{4-6,13} Nevertheless, none of these factors are unique for TLH.

Because studies have pointed to the possibility of increased risk of dehiscence with minimally invasive techniques, some potential differences in surgical technique that could contribute to this problem have been studied.^{3,7}

Different from total vaginal hysterectomy and total abdominal hysterectomy for TLHs:

1. Use of energy sources to make the vaginal colpotomy may result in tissue destruction beyond the incision, potentially increasing tissue necrosis and leading to poor healing of the vaginal cuff compared with a sharp colpotomy that is made using a scalpel or scissors. Different electrosurgical instruments (e.g. bipolar and monopolar devices) or ultrasonic devices produce varying amounts of tissue destruction.
2. Laparoscopic magnification of the surgical field may distort the view and cause the surgeon to place sutures too close to the vaginal cuff edge (<1 cm) or not achieve full thickness closure.
3. Laparoscopic suturing to close the vaginal cuff requires advanced training to achieve secure knots via extracorporeal or intracorporeal techniques. Inappropriate use of the laparoscopic knot pusher or poor intracorporeal knot tying technique may compromise suture integrity.

Recently, several studies compared the influence of various vaginal vault closure techniques on the incidence of VCD after TLH. Internationally, the etiology of VCD is still a matter of concern. Either in its technique (TLH) as in the used technology (electrosurgical colpotomy and/or suturing method), an explanation could be found for the higher incidence of VCD.¹³ Preventive measures to minimize the risk of VCD after hysterectomy are uncertain since the causes are not well-established.⁷

This study aims to review laparoscopic surgical techniques in the minimal invasive hysterectomy and its association with VCD.

A literature review was performed using PubMed, Medscape reference, HighWire Press and Up-to-date. The search was conducted using the keywords 'laparoscopic vaginal vault dehiscence', 'laparoscopic vaginal cuff closure techniques', 'vaginal cuff laparoscopic suture methods' and 'electrosurgery laparoscopic hysterectomy'.

Fifty-eight citations were found. Among these studies, a second selection of articles was performed according the purpose of this review. The selected papers were also screened for further references. At the end of the process, 29 articles were reviewed.

LAPAROSCOPIC SUTURING METHODS

Interrupted vs Running Sutures with Knot

Although techniques for suturing of the vaginal cuff have changed rapidly over the past years, only one prospective study on this subject has been published.¹⁴ This study compared laparoscopic closure with interrupted and running sutures, however, with a double-layer suturing method and with an extracorporeal knotting technique. The study

revealed no statistically significant difference between the two suture methods (incidence of VCD: 1.2%).

Several methods are described for laparoscopic intra-abdominal cuff closure. Interrupted or continuous sutures may be tied intracorporeally with a needle driver and grasper or extracorporeally with a knot pusher.¹⁵

TEM Clips

Another method already adopted, off label, in the vaginal cuff closure, is a suturing technique commonly used in transanal endoscopic microsurgery (TEM).

In this technique, a regular Vicryl no. 0 with a suture staple placed at the distal end of the wire is sutured from the right to the left angle of the vaginal cuff, after which another suture staple is placed at the proximal end to secure the suture (suture clip forceps for TEM, Richard Wolf GmbH, Knittlingen, Germany). In all suturing methods, both uterosacral ligaments are incorporated in the repair, and the peritoneum is unclosed.

This way, cuff closure using a running vicryl suture with TEM clips, is a newly appointed alternative to other suturing techniques currently in use. Although it is an easy method to adopt, based on data, no statistical superiority of this suturing procedure could be proven.¹³

Barbed Suture

Barbed suture is a relatively recent concept in gynecologic surgery. The Quill SRS bidirectional barbed suture (Angiotech Pharmaceuticals, Inc Vancouver BC, Canada) was FDA approved for soft tissue approximation in 2004¹⁶ and has been commercially available in the United States since 2007.

Bidirectional barbed sutures are created by cutting barbs into the suture with the barbs facing in an opposite direction to the needle. The barbs change direction at the midpoint of the suture¹⁷ (Fig. 1) and needles are swaged onto both ends of the suture. Due to its decreased effective diameter, the straight-pull tensile strength of barbed suture is rated one suture size greater than smooth suture (e.g. A 0 barbed suture equals a 2-0 smooth suture).

The anchoring of bidirectional barbed suture resists migration and can be conceptualized as a 'continuous interrupted' suture without knots and has been shown to have at least equal tissue holding performance as comparable knot anchored suture has.^{18,19} This offers several advantages. Since, bidirectional barbed sutures self anchor and are balanced by the countervailing barbs, no knots are required. Furthermore, barbed suture self anchors at every 1 mm of tissue, yielding more consistent wound opposition. Finally, knotless barbed suture can securely reapproximate tissues with less time, cost and aggravation.^{20,21}

The safety and effectiveness of barbed sutures, in closure of the vaginal cuff, has already been demonstrated in two studies.^{16,22} However, one was noncomparative and, in the other, a more time-consuming double-layer suturing method was used. In both, the use of this suture reduced the incidence of the VCD. Furthermore, the barbed suture proved to be relatively easy to learn dehiscence while not increasing the rate of postoperative bleeding, cuff cellulitis or granulation tissue. Some concern is expressed regarding adhesion formation of the intestine to the tail of the barbed suture, which in turn potentially could cause bowel obstruction.²³

Suture Material

Several studies did address the type and class of suture material as a possible cause for VCD.^{3,24,25} Up-to-date review suggests the use of a delayed absorbable monofilament suture [e.g. polydioxanone (PDS IITM)]: Preferred for the theoretical advantage of lower infectious risks.⁷

However, there is neither data demonstrating evidence nor consensus on the preferred suture material, concerning monofilament vs multifilament and delayed absorbability of the thread.

According to the data, there is no superiority of one of the suturing method over the others.

ELECTROSURGERY

Some authors state that electrosurgical colpotomy, often used in TLH, is responsible for suboptimal vaginal cuff healing, due to tissue necrosis and prolonged devascularization.^{14,25-27}

Colpotomy technique may account for the observed increased risk of VCD associated with TLH as compared with TVH and TAH. In the latter procedures, the colpotomy is often made sharply using heavy scissors or a knife. However, during TLH, the colpotomy is often made using

electrosurgery, which may yield thermal damage at the cuff site, weakening the tissue and increasing the risk of dehiscence.⁸

It is known that monopolar energy in the coagulation mode, is frequently used, for the colpotomy in THL. Coagulation mode is an interrupted, high-voltage current dispersed over a large surface area, while cutting mode is a continuous, low-voltage current concentrating the energy in a small area, resulting in more rapid tissue heating and less thermal spread. Coagulation mode may result in more tissue damage, although is better at sealing vessels in vascular areas like the vaginal cuff.⁸

A recent study, conducted in swines, analyzed energy-induced damage (ultrasonic, monopolar and bipolar), to the vagina during laparoscopic hysterectomy, using the distal scalpel-cut margin was used as reference. All energy sources demonstrated tissue damage, with ultrasonic showing the least and bipolar the greatest.²⁷

Further study of tissue damage relative to cuff closure at laparoscopic hysterectomy is warranted, as also its possible association with vaginal dehiscence.

CONCLUSION

VCD is a potentially severe adverse event and is still a matter of concern to those who perform minimal invasive hysterectomy. Its exact etiology remains unclear.

Data on additional risk factors for cuff dehiscence are limited and conflicting.² Although one study reported no difference in age, tobacco use or diabetes mellitus between women with and without cuff dehiscence, it likely was underpowered to detect a clinically meaningful difference.²⁸ Although it seems biologically plausible that any condition that could compromise wound healing would increase the risk of VCD, the data on such risk factors are sparse. The inconsistency of the reporting of risk factors in studies and case reports, the rarity of the VCD, and the lack of comparison of risk factors between women with and without dehiscence in most retrospective studies makes it impossible to assess the significance of each of these potential risk factors.

Some questions remain are as follows:

1. If in the abdominal hysterectomy, VCD is not increased in patients who had an unclosed cuff closure technique, why would be the suture method, the cause of this complication in the laparoscopic procedure?
2. If electrosurgical colpotomy, overused in laparoscopic hysterectomy, is the cause of damage and wound healing complications, why these exist a superiority of transvaginal closure compared with laparoscopic closure (concerning VCD), in the same electrosurgical damaged tissues?



Fig. 1: Bidirectional barbed suture with barbs that change direction in the middle¹⁷

3. Why would be the preoperative morbidity factors the cause for the superior incidence of VCD, in TLH? Are not the patients the same?
4. What about postoperative conditions in TLH? Lower indices of pain, earlier work return, better predisposition to restart sexual intercourse. Won't be these advantages of the laparoscopic procedures the mainly risk factors of VCD?

Vaginal vault dehiscence is a rare complication after hysterectomy, but more common after a laparoscopic approach. The relationship between cuff dehiscence and mode of hysterectomy would be assessed best by a very large randomized controlled trial (RCT) study design. In fact, much of what is known about VCD comes from case reports and case series, which makes it difficult to truly assess possible risk factors and whether these risk factors differ by type of surgical procedure, mode of hysterectomy, etc. It is unknown whether variations in the surgical management of the vaginal cuff influence the risk of dehiscence.

Despite of this, techniques specific to TLH are pointed to be the main factor of the increased risk of vaginal vault dehiscence seen after laparoscopic hysterectomy.

More research is necessary to identify modifiable risk factors for VCD and methods for its prevention.

ACKNOWLEDGMENT

I would like to thank Dr Rajneesh Mishra and all the collaborators of the World Laparoscopy Hospital, New Delhi, India for their valuable support.

REFERENCES

1. Ramirez PT, Klemer DP. Vaginal evisceration after hysterectomy: A literature review. *Obstet Gynecol Surv* 2002 July;57(7):462-467.
2. Cronin B, Sung V, Matteson A. Vaginal cuff dehiscence: Risk factors and management. *Am J Obstet Gynecol* 2012 Apr;206(4):284-288.
3. Hur HC, Guido RS, Mansuria SM, Hacker MR, Sanfilippo JS, Lee TT. Incidence and patient characteristics of vaginal cuff dehiscence after different modes of hysterectomies. *J Minim Invasive Gynecol* 2007 May-Jun;14(3):311-317.
4. Iaco PD, Ceccaroni M, Alboni C, Roset B, Sansovini M, D'Alessandro L, Pignotti E, Aloysio DD. Transvaginal evisceration after hysterectomy: is vaginal cuff closure associated with a reduced risk? *Eur J Obstet Gynecol Reprod Biol* 2006 Mar;125:134-138.
5. Hur HC, Donellan, NM, Mansuria, NM, Barber RE, Guido R, Lee T. Vaginal cuff dehiscence after different modes of hysterectomy. *Obstet Gynecol* 2011 Oct;118(4):794-801.
6. Croak AJ, Gebhart JB, Klingele CJ, Schroeder G, Lee RA, Podratz KC. Characteristics of patients with vaginal rupture and evisceration. *Obstet Gynecol* 2004 Mar;103(3):572-576.
7. Hur HC. Vaginal cuff dehiscence after hysterectomy. UpToDate 2012 Oct. Available at: <http://www.uptodate.com>. Accessed November, 2012.
8. Robinson BL, Liao JB, Adams SF, Randall TC. Vaginal cuff dehiscence after robotic total laparoscopic hysterectomy. *Obstet Gynecol* 2009 Aug;114:369-371.
9. Agdi M, Al-Ghafri W, Antolin R, Arrington J, O'Kelley K, Thomson AJ, Tulandi T. Vaginal vault dehiscence after hysterectomy. *J Minim Invasive Gynecol* 2009 May-June; 16(3): 313-317.
10. Uccella S, Ghezzi F, Mariani A, Cromi A, Bogani G, Serati M, Bolis P. Vaginal cuff closure after minimally invasive hysterectomy: our experience and systematic review of the literature. *Am J Obstet Gynecol* 2011;205(2):119.e1-12.
11. Shen CC. Comparison of one- and two-layer vaginal cuff closure and open vaginal cuff during laparoscopic-assisted vaginal hysterectomy. *J Am Assoc Gynecol Laparosc* 2002 Nov; 9(4):474-480.
12. Singh K, Shah B, Patel V, Goswami M, Shah MB. Vaginal vault closure techniques in total laparoscopic hysterectomy: a comparison between laparoscopic route vault suturing and vaginal route suturing. *Nati J Commun Med* 2011;2(2):289-292.
13. Blikkendaal MD, Twijnstra A, Pacquee S, Rhemrev JP, Smeets MJ, De Kroor CD, Jansen FW. Vaginal cuff dehiscence in laparoscopic hysterectomy: influence of various suturing methods of the vaginal vault. *Gynecol Surg* 2012 Nov; 9(4):393-400.
14. Jeung IC, Baek JM, Park EK, Lee HN, Kin CJ, Park TC, Lee YS. A prospective comparison of vaginal stump suturing techniques during total laparoscopic hysterectomy. *Arch Gynecol Obstet* 2010 Dec;282(6):631-638.
15. Lange S, Higgins R. Laparoscopic hysterectomy. Medscape Reference 2011 July. Available at: <http://emedicine.medscape.com/article/1839957-overview>. Accessed November 2012.
16. Einarsson J, Vellinga T, Twijnstra A, Chavan NR, Suzuki Y, Greenberg JA. Bidirectional barbed suture: an evaluation of safety and clinical outcomes. *JSLs* 2010 Jul-Sep;14(3):381-385.
17. Leung JC. Barbed suture technology: recent advances. *Med Textiles* 2004 Oct;26-27:62-80.
18. Rashid RM, Sartori M, White LE, et al. Breaking strength of barbed polypropylene sutures: rater-blinded, controlled comparison with nonbarbed sutures of various calibers. *Arch Dermatol* 2007 Jul;143(7):869-872.
19. Rodeheaver GT, Pineros-Fernandez A, Salopek LS, Rodeheaver PA, Leung JC, Ruff GL, Batchelor SD. Barbed sutures for wound closure: in vivo wound security, tissue compatibility and cosmesis measurements. *Society for Biomaterials 30th Annual Meeting Transactions* 2004; 229:232.
20. Greenberg JA, Einarsson JI. The use of bidirectional barbed suture in laparoscopic myomectomy and total laparoscopic hysterectomy. *J Minim Invasive Gynecol* 2008 Sep-Oct; 15(5):621-623.
21. Moran ME, Marsh C, Perrotti M. Bidirectional-barbed sutured knotless running anastomosis vs classic van velthoven suturing in a model system. *J Endourol* 2007 Oct;21(10):1175-1178.
22. Siedhoff MT, Yunker AC, Steege JF. Decreased incidence of vaginal cuff dehiscence after laparoscopic closure with bidirectional barbed suture. *J Minim Invasive Gynecol* 2011 Mar-Apr;18(2):218-223.

23. Donnellan NM, Mansuria SM. Small bowel obstruction resulting from laparoscopic vaginal cuff closure with a barbed suture. *J Minim Invasive Gynecol* 2011 Jul-Aug;18(4):528-530.
24. Yuce K, Dursun P, Gultekin M. Posthysterectomy intestinal prolapse after coitus and vaginal repair. *Arch Gynecol Obstet* 2005 Jun;272(1):80-81.
25. Walsh CA, Sherwin JR, Slack M. Vaginal evisceration following total laparoscopic hysterectomy: case report and review of the literature. *Aust N Z J Obstet Gynaecol* 2007 Dec;47(6):516-519.
26. Nezhat CH, Nezhat F, Seidman DS, Nezhatc. Vaginal vault evisceration after total laparoscopic hysterectomy. *Obstet Gynecol* 1996 May;87:868-870.
27. Gruber DD, Warner WB, Lombardini ED, Zahn CM, Bullor JL. Laparoscopic hysterectomy using various energy sources in swine: A histopathologic assessment. *Am J Obstet Gynecol* 2011;205(5):494-496.
28. Nick AM, Lange J, Frumovitz M, Soliman PT, Schmeler KM, Schlumbrecht MP, dos Reis R, Ranirez PT. Rate of vaginal cuff separation following laparoscopic or robotic hysterectomy. *Gynecol Oncol* 2011 Jan;120(1):47-51.

ABOUT THE AUTHORS

Raquel Maciel (Corresponding Author)

Department of Gynecology and Obstetrics, Centro Hospitalar do Porto Maternidade Júlio Dinis, Porto, Portugal, e-mail: raquelmaci@aeiou.pt

Tânia Freitas

Resident, Department of Obstetrics and Gynecology, Hospital Dr Nélcio Mendonça, Madeira Island, Portugal

Energy System and Endosuturing in Single Incision Laparoscopy Surgery

B Beena Kumari

ABSTRACT

Background: SILS is a newer laparoscopic technique emerging in this era. So this article aims to provide an overview on safer surgical skills by understanding basic principles and proper application of energy source and endosuturing techniques.

Materials and methods: Articles of relevant studies are explored from Google, HighWire Press, PubMed, SpringerLink using keywords—single incision laparoscopy surgery (SILS), energy source in SILS, suturing in SILS.

Aim: The main aim is to evaluate the best energy source which can be used in SILS with better ergonomics and to define the good suturing technique in single port laparoscopic surgery.

Results: Most of the studies show that newer energy devices, such as LigaSure, harmonic and EnSeal, are being used with advantage of less smoke, less operative time, very minimal blood loss, less drop in hemoglobin value postoperatively, and reduced duration of hospital stay. Endosuturing using roticulators, Endo-stitch is easier, though intracorporeal and extracorporeal knotting can also be performed same like conventional laparoscopy.

Conclusion: LigaSure, harmonic and EnSeal can be safely used as multifunctional devices in the available space in SILS without changing the instruments frequently as in conventional laparoscopy. Both intracorporeal and extracorporeal knot can be put by practice and with aid of newer suturing devices.

Keywords: Energy system and SILS, Harmonic, LigaSure and SILS, Suturing in SILS.

How to cite this article: Kumari BB. Energy System and Endosuturing in Single Incision Laparoscopy Surgery. *World J Laparosc Surg* 2013;6(2):86-92.

Source of support: Nil

Conflict of interest: None declared

INTRODUCTION

Minimally invasive surgery is one of the most significant surgical advances of the 21st century and has become the standard treatment for many gynecological pathologies. In the last decade, numerous studies have demonstrated that laparoscopic approach for various gynecologic benign and malignant diseases is feasible and results in shorter hospital stay, improved quality of life, shorter operating time and decreased perioperative complications when compared to open procedures.

Single incision laparoscopic tubal ligations have been performed for more than 30 years after the innovation of the single-port laparoscopic tubal ligation by gynecologist Dr Clifford Wheelless.¹ Reports of performing more advanced laparoscopic procedures using single-port surgery

came years later, with the first single-port laparoscopic hysterectomy reported in 1991 by Pelosi et al.² Today, the trend in gynecological laparoscopic procedures changes to 'single incision laparoscopic surgery' (SILS). Single incision (or port) laparoscopic surgery (SILS) has emerged in an attempt to further reduce morbidity and enhance the cosmetic benefits of conventional laparoscopic surgery.

The scope of electrosurgery extends beyond tubal ligation; now tools enable us to perform many procedures and manage anatomic difficulties with increased patient safety. Many new instruments and methods have been developed for suturing and knot tying in SILS to overcome these difficulties.

AIM

The main aim is to evaluate the best energy source which can be used in SILS with better ergonomics and to define the good suturing technique in single-port laparoscopic surgery.

MATERIALS AND METHODS

A literature review was performed using SpringerLink, HighWire press, Journal of MAS and major search engines like Google, Yahoo, MSN, PubMed, etc. The search terms were energy system and SILS, harmonic, LigaSure and SILS, suturing in SILS. The articles were selected based on the type of energy system used, special instruments used for energy and suturing and its safety and reliability in SILS.

PRINCIPLES OF ENERGY SYSTEMS

A surgeon must understand the fundamental principles of energy-based surgery and the relative strength and weakness of any device in this context and take the device to a higher level of performance, achieving otherwise impossible tissue effects.³⁻⁵

Bipolar Electrosurgery

A high frequency alternating current applied to living tissue by an active electrode, flow through the tissue by pathways offering the least resistance and return to an opposing electrode. The flow of electrons or electric current (I) is set in motion and sustained by electromotive force termed voltage (V) to complete the circuit across the differences in electrical potential between the two electrodes. Greater voltage produces greater thermal necrosis.

Thermal injury correlates to the maximum tissue temperature, total volume of heated tissue, rate of temperature rise and duration of temperature elevation. If living tissue is heated to above 50°C for a sufficient duration of time, irreversible damage occurs; cellular water evaporates at 90°C (desiccation); cell walls rupture at 100°C (vaporization) and tissue begins to carbonize and char at 250°C. The temporal relationship between tissue temperature and thermal injury is nonlinear owing to the complex effects of conduction and convection on the entire process.

Practically, thermal effects can be moderated by altering the power setting, the type of output current (cut vs blend vs coagulation), the electrode dwell time, the proximity of the tissue to the active electrode and the current density (i.e. electrode surface area). The behavior of electricity in living tissue is generally governed by Ohm's law $V = I \times R$. Derivatively, current is directly proportional to voltage and inversely proportional to resistance (R). To complete a circuit, force or voltage must increase as resistance increases.

Power is keyed into an electrosurgical generator as watt (W), corresponding to the rate of work being performed. The relationship between voltage and resistance. The relationship between voltage and resistance is restated by the derivation of power, $W = I^2/R$ and $W = V^2/R$; at any particular power setting (W) using a conventional electrosurgery generator, higher R as with desiccation, fat or char will drive higher output V to maintain the desired tissue end point.

Ultrasonic Surgery

This type of surgery owes its efficacy to the fact that ultrasound travels easily through water, which makes up roughly 80% of all soft tissue. High intensity focussed ultrasound transfers a significant amount of energy to the targeted tissue, causing a rise in temperature.

Coagulation with ultrasound requires coaptation of blood vessels; H^+ bonds are broken, and protein in the cells is denatured. Denatured protein forms a sticky coagulum. Internal tissue heat generated from friction then seal or weld vessel walls. Simultaneous cutting and coagulation takes place at a lower temperature than in electrosurgery with minimal lateral thermal spread.

New Energy Devices

Evaluation of newer energy systems should be based on the following characteristics:⁵

- Reliability
- Efficiency
- Ergonomics

- Handedness
- Response to variable tissue content
- Smoke production
- Capacity to dissect
- Tissue sticking
- Tissue color
- Cost
- Degree of innovation

Instrumentation to expand Surgical Options

One of the disadvantages of SPLS has been the restriction of movement that arises because of the close proximity of instruments and instrument handles. The latest designs have made articulation possible for tissue graspers, scissors, vessel sealers and scopes. The value of articulation is apparent inside the abdomen, where it allows perfect positioning of the area of dissection. Outside the abdomen, the handles can be arranged in an angled pattern to allow the surgeon and assistant to operate comfortably. The latest instruments are designed to dissect, cauterize and cut, thereby decreasing the number of instrument exchanges necessary.^{6,7} New bipolar technology seals blood vessels to withstand high systolic pressure.

There are three bipolar platforms that utilizes low constant voltage, pulsed current and impedance feedback along with a paired ligating cutting device.^{4,5} This intricate combination complete the sealing. Consequently, there is minimal plume, carbon formation and tissue sticking:

LigaSure vessel sealing device (Covidien, Boulder, CO) applies a high coaptive pressure during the generation of tissue temperature under 100°C hydrogen cross-links that are first ruptured and then renatured, resulting in a vascular seal that has high tensile strength.

The second instrument, the PlasmaKinetic cutting forceps (Gyrus/ACMI/Olympus), lacks the compressive pressure needed to create a true vessel seal but provides efficient coagulation with visibly pulsed energy that is moderated by impedance feedback.

The third device, the EnSeal laparoscopic vessel fusion system (EES, Cincinnati, OH) utilizes temperature-sensitive polymeric material (PTC) embedded with nanometer-sized spheres of carbon that automatically controls a locally regulated current, regulating temperature at about 100°C. Desiccation with this device is facilitated by advancing an innovative 'I-blade' that provides extremely high pressure along the length of the jaw to both cut and squeeze the tissue bundle, eliminating tissue water and steam. So when we 'follow the bubble', tissue becomes easier to cut which can be achieved by advancing I-blade at a rate of 1 mm/sec. It produces only 1 mm of spread, used for transecting larger vessels. In EnSeal, there are two ways to deliver energy,

single tap and double tap. Single Tap is a 15 seconds cycle which will tell us when the tissue has reached 450 Ohm or complete coagulation has been reached. Double tip is a 2 minutes cycle, which does not confirm this tissue impedance.

- **Harmonic device:** Using the dynamic tissue effects of mechanical energy, ultrasonic blades and shears, tissue effects from ultrasonic energy using the harmonic scalpel (EES, Cincinnati, OH) are actuated by a titanium blade of variable excursion that vibrates nearly 55,500 Hz/sec from an in-line piezoelectric crystals housed in the hand piece of the device. It is not regulated through impedance. The high frequency vibration in tissue causes a low temperature protein denaturation by rupturing the hydrogen bonds of tissue proteins. Tissue cutting from cavitation fragmentation naturally evolves from the mechanical vibration and percussive effects of steam that emanates through the tissue parenchyma. Differing from the volumetric thermal tissue effects during electrosurgery, lateral thermal damage with ultrasonic energy is limited by the linear nature of energy propagation through the tip of the blade.

Properties of laparoscopic vessel sealing devices:⁸

Devices	Mean burst pressure (mm Hg)	Mean seal time (sec)
LigaSure V	386	10
Gyrus PK	290	11.1
Harmonic scalpel	204	14.3
EnSeal PTC	255	19.2

Evaluation conducted on 5 mm bovine arteries

Thunderbeat™ (TB) (Olympus, Japan): It simultaneously delivers ultrasonically generated frictional heat energy and electrically generated bipolar energy. TB has a higher versatility compared with the other instruments like: Harmonic® ACE, LigaSure™ V and EnSeal tested with faster dissection speed, similar bursting pressure and acceptable thermal spread. This new energy device is an appealing, safe alternative for cutting, coagulation and tissue dissection during surgery and should decrease time and increase versatility during surgical procedures.⁹

APPLICATION OF ENERGY SYSTEM IN SIL SURGERIES

Harmonic energy: Harmonic ACE can be used for peritoneal separation, to amputate the cervix, coagulating and cutting across the infundibulopelvic ligament, ovarian ligament/pedicle, colpotomy, excision of endometriosis, to release adhesions and distortion, appendectomy and myomectomy. Near the vital structures, like ureter, bladder or bowel, harmonic will be the option.^{5,10,11} In one case report,¹² the ovarian cyst wall was cut with harmonic scalpel on coagulation mode and the epithelial lining in the residual

cyst was removed by electrocauterizing with a monopolar cautery hook. Ismail H et al¹³ reported that harmonic ACE can be used safely for Nissen fundoplication. Harmonic is also one of the choice for colectomy in colon cancer which was shown by Egi et al¹⁴ study where 20 patients were operated with 10 cases each with SIL and conventional laparoscopic colectomy. They have shown less operative time, less blood loss and conversion rate.

LigaSure: The LigaSure has 5 mm blunt tip laparoscopic sealer, 37 cm long shaft and is capable of sealing and dividing vessels up to 7 mm in diameter. The 44 cm instrument allow to access difficult to reach areas, such as those near the spleen, hilum or gastroesophageal junction. A 20 cm shaft can be used in pediatric age group.¹⁵ Parag WD et al describes in his techniques that LigaSure tissue fusion technique, LigaSure advance and Valleylab are ideal hemostatic tool for minimal access surgery. Ultrasonic devices, like harmonic, AutoSonix (Autosuture) and SonosurgX (Olympus), have been well established. Ogura et al report the development of a new compact articulating ultrasonically activated device (USAD) prototype in 5 and 10 mm size with a bendable tip that offers coagulating dissection performance.¹⁶

Ligasure gives a promising results in SIL hysterectomy with excellent tissue dissection, less operative time, less blood loss and reduced duration of hospital stay.¹⁷⁻²⁰ Young et al²⁰ performed SIL-LAVH on 100 patients wherein he used LigaSure system (Valleylab) for all patients.

Mathew et al conducted animal study (N = 45) and concluded that the acute *ex vivo* study demonstrated a significant difference in the cystic duct bursting pressure between surgical clips and ultrasonic coagulating shears and between electrothermal bipolar vessel sealer and ultrasonic coagulating shears. The ultrasonic coagulating shears and electrothermal bipolar vessel sealer failed to maintain seal integrity in the *in vivo* animal study. Given the failure of the ultrasonic coagulating shears and electrothermal bipolar vessel sealer in the animal model, these energy sources should not be used for transection of the cystic duct or major hepatic ducts during hepatobiliary surgery.²¹ In one of the case report published by Ondrer S, it is mentioned that, for vessel sealing, the shaft of LigaSure is parallel to uterine artery instead of perpendicular to their axis. They had used LigaSure, harmonic scalpel for adnexal dissection, bipolar cautery (for hemostasis at cut surface of cervix). Cervix was transected with lap unipolar scissor. For sacrocolpopexy-bladder was retracted away from vagina and vesicovaginal space by fine dissection using 5 mm harmonic scalpel.²² Exploring the safer techniques of SILS surgery in children Joshi M et al says that SIL splenectomy can be performed utilizing combination of harmonic scalpel and LigaSure.²³

Combination of energy sources can also be used in hysterectomy as mentioned in few searched articles;^{24,25} in their study, IP was sealed and cut with 10 mm LigaSure. The bladder peritoneum was dissected with 5 mm Harmonic ACE uterine artery which was skeletonized and dissected by 10 mm LigaSure™. Anterior and posterior colpotomies were performed with Harmonic ACE®. In another study, colpotomy was performed using monopolar hook or scissor.

EnSeal: EnSeal device comes either as a round tipped 5 mm device or as a curved 3 mm device that looks like a curved surgical clamp. It is effective for large vascular bundles and for separating the leaves of broad ligament or opening the bladder flap. It can be used for adnexal dissection.^{5,26} EnSeal can also be used for splenectomy, studies have stated that blood loss was <10 ml.²⁷

PKS (Gyrus): It was applied in 30 cases—10 mono/bilateral adnexectomies and 20 cystectomies. They used PKS as it was multifunctional with comparable results to LigaSure/Harmonic.²⁸ Mean blood loss was 10 ml, overall operative time was 39.5 minutes. Hospital stay was for 1.3 days and no postoperative complication was done.

Bipolar forceps/scissors: Maxime M et al did salpingectomy in 37 patients using bipolar forceps/scissor. Operative time was longer (50 minutes) but duration of hospital stay was shorter (1.5 days).²⁹

SUTURING IN SILS

Among searched articles, only few mentioned about the correct endosuturing methods in SILS. Suturing through a single port can be a challenge. When endoscopic suturing is required, standard suturing using both intracorporeal and extracorporeal methods is possible. Suturing aids, such as the Endo Stitch (Covidien) or LapraTy (Ethicon), Roticulator, are helpful. One author recommends Quill bidirectional, self-retaining suture with barbs (Angiotech) to avoid the need for knot-tying. The MiniLap (Stryker) is a 2.3 mm grasper that is inserted percutaneously directly through the abdominal wall without an incision. It can be used to set the needle on the needle driver or manipulate tissue while suturing. The resulting skin incision is barely visible and does not require closure.⁶

Toshiaki E have devised a remarkably simple knot-tying technique that can be applied during SILS with a SILS port with a Roticulator and a straight-type needle driver. We determined that, after transfixing the needle, the long tail of the thread should be grasped at around 90° relative to the long axis of tip of the Roticulator, which is articulated at 80°. This automatically forms an ideal C-loop because of gravitation. The needle attached to the long tail should face

the distal side from the tip of Roticulator (from the surgeon's perspective). The apex of the C-loop is then toward the proximal side from the tip of the Roticulator (from the perspective of the surgeon). This thread position is important during the knot-tying process. The upper arm of the C-loop should then be entwined by applying a series of axial spinning movements to the rod of the needle driver. At this time, the jaws of the needle driver should be kept open so the thread does not slip off of the rod. The benefit of this technique is that it does not require any special skills; any surgeon able to perform intracorporeal suturing should also be able to easily tie knots during SILS.³⁰

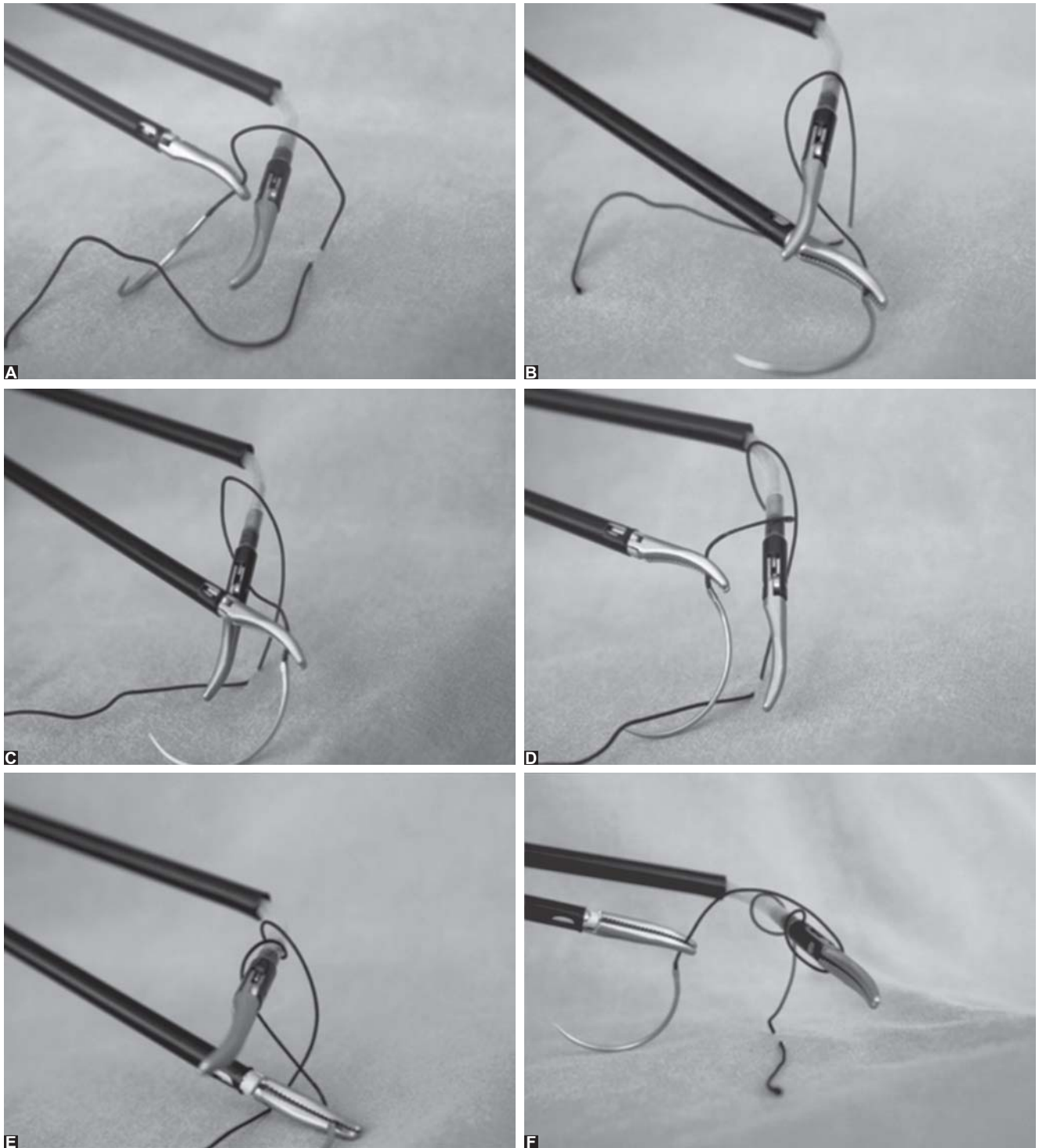
Another method noted in literature for suturing in SILS:³¹

In the first step, the Roticulator Endo Grasp is opened in the knotting area, and the suture is wound around twice (Figs 1A to F). The suture is grasped with the Roticulator instrument at a point a few centimeters distal to the exit of the suture from the tissue (Fig. 2). The reef knot is converted into a slip knot by applying distracting forces on the suture material at the two opposite points (Fig. 3). After the first knot has been tightened, the instrument is removed, and the procedure is repeated until the desired number of knots has been made. Finally, after the knot has been tightened, the suture is cut (Figs 1A to F, 2 and 3).

The majority of these methods required special, often disposable, devices that were expensive (i.e. Endo Stitch).¹² The 'side winding' technique makes laparoscopic suturing feasible, especially when the angle between the hand instruments is not ideal and the working space is limited. With this simple technique, the disadvantages of the single incision are overcome with the aid of flexible instruments. It is also helpful when the length of the suture is short. With this technique, laparoscopic suturing may be performed by using routine instruments, thus providing cost-effectiveness, feasibility and minimal instrument transfer. Moreover, with this technique, the instruments are pulled away from the tissue during knotting, so it is safer than the conventional approach. It reduces the possibility of inadvertently catching the organs in the suture.

In gynecology, hysterectomy is the most common surgery done. So in modern day, we should be thorough with SILS hysterectomy whether it is supracervical or LAVH or total. In hysterectomy, endosuturing of vaginal cuff can be closed with either intracorporeal or extracorporeal separate sutures. Extracorporeal sutures were performed by using a Clarke-Reich knot pusher, same as in conventional laparoscopic cuff closure^{24,22} (Figs 4A and B).

Bidirectional barbed sutures reduce the difficulty of technique intracorporeally knotting compared with



Figs 1A to F: The Roticulator Endo Grasp is opened on the knotting area, and the suture is wrapped around twice

traditional sutures, the benefits of the bidirectional self-retaining sutures with tissue retainers (barbs) include speed and economy of suture placement.²⁶

The flexible endostapler (Endo GIA Roticulator™, Autosuture; Covidien Norwalk, CT, USA) and the Endostitch™ suture system (Autosuture; Covidien, Norwalk, CT, USA) introduced through a Quadport™ or Triport (advanced surgical concepts) to fashion the enterocolonic anastomosis with extracorporeal knot tying after the initial

holding stitch. Use of a 10 mm endoscopic suturing device (SILS™ Stitch, Covidien, Norwalk, CT, USA) has been described for MISS Nissen's fundoplication.¹⁶

The feasibility of linear salpingotomy with suturing for ampullary tubal pregnancy via single incision laparoscopic surgery (SILS) was studied in three patients with ampullary tubal pregnancy. The linearly incised fallopian tube was intracorporeally sutured using an articulating suturing device dedicated to SILS. The mean surgical duration was



Fig. 2: The suture is grasped with the Roticulator instrument at a point that is a few centimeters distal to the exit of the suture from the tissue

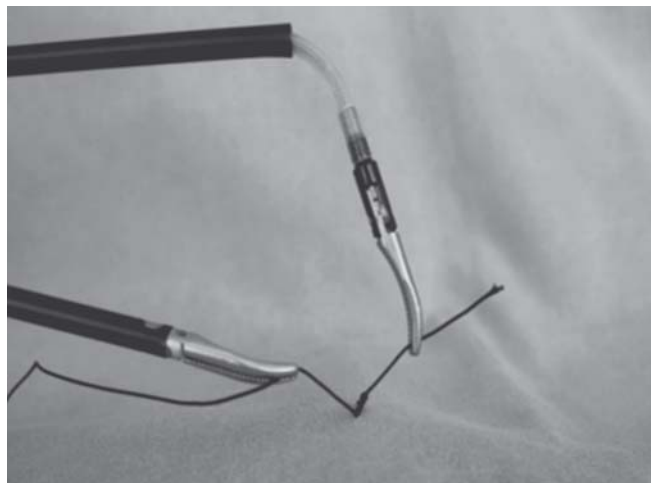
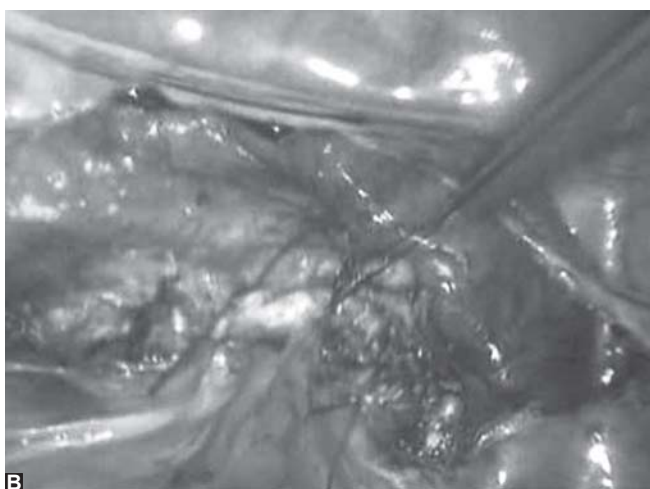
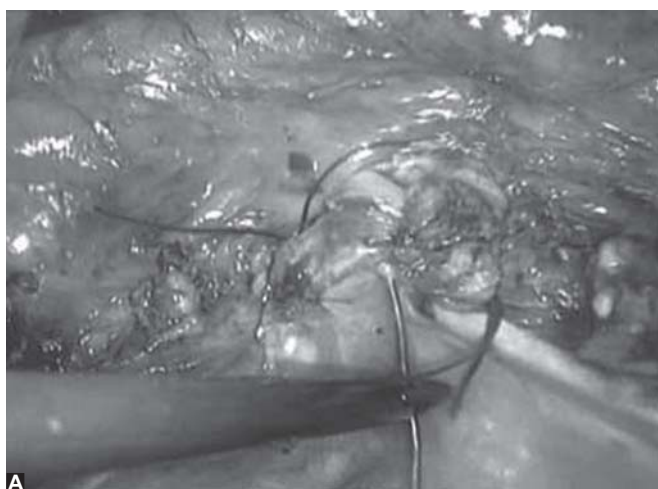


Fig. 3: The reef knot is converted into a slip knot by applying distracting forces on the suture material at the two opposite points



Figs 4A and B: (A) Flattened needle was used during vaginal cuff suturing using Vicryl 0, (B) extracorporeal sutures were performed by using a Clarke-Reich knot pusher

54 minutes. Tubal preservation by linear salpingotomy was accomplished for all patients without up-conversion to conventional laparoscopy.³²

CONCLUSION

The days of clamp-cut-tie or desiccate-cut are gone. Gaining control over the energy and moderating tissue effects is the key. Assess new energy based device not just for thermal characteristics, but for use-ability to lift, grasp and dissect tissue and its performance in heterogenous desiccated, fatty or vascular tissue. Evaluate its ergonomics and its cost and, most importantly, whether it is safer than other devices. LigaSure, Harmonic and EnSeal can be safely used as multifunctional devices in the available space in SILS without changing the instruments frequently as in conventional laparoscopy.

SILS is a new and promising technique, but suturing is more difficult in this procedure due to the port position and

the angle of the hand instruments. It is particularly challenging to form a loop around the hand instrument when there is limited working space. Both intracorporeal and extracorporeal knot can be put by practice and with aid of newer suturing devices.

REFERENCES

1. Wheelless CR Jr. Elimination of second incision in laparoscopic sterilization. *Obstet Gynecol* 1972 Jan;39(1):134-136.
2. Pelosi MA, Pelosi MA 3rd Laparoscopic hysterectomy with bilateral salpingo-oophorectomy using a single umbilical puncture. *NJ Med* 1991 Oct;88(10):721-726.
3. Brill AI. Energy systems for operative laparoscopy. *Am J Assoc Gynecol Laparosc* 1998 Nov;5(4):333-349.
4. Brill AI. Bipolar electrosurgery: convention and innovation. *ClinObstet Gynecol* 2008 Mar;51(1):153-158.
5. Brill AI. Advanced energy systems for laparoscopic gynecology procedure. *Supplement to OBG Management* 2009 Nov;1-8.
6. Atkin PR, Nimaroff ML, Bhavsar V. Applying single-incision laparoscopic surgery to gyn practice: What's involved. *OBG Management* 2011 April;23(4):28-36.

7. Yao DC, Ying WNG, Yoke FF. Laparoendoscopic single-site surgery (LESS) for a large ovarian tumour: first clinical case report. *J Minim Invasive Surg* 2011;2011:105643.
8. Lamberton GR, His RS, Jin DH. Prospective comparison of four laparoscopic vessel ligation devices. *J Endourol* 2008;22(10):2307-2312.
9. Jeffrey M, Koiana T. Evaluation of the safety, efficacy, and versatility of a new surgical energy device (Thunderbeat) in comparison with Harmonic ACE, LigaSure V, and EnSeal devices in a porcine model. *J Laparoendosc Adv Surg Tech A* 2012 May;22(4):378-386.
10. Pulkit N, Bhatia I, Bhatia P. Ten steps of 'Scarless' single incision total laparoscopic hysterectomy. *Newsonline-Bhatia Global Hospital and Endosurgery Institute* 2010 Feb;10(2).
11. Bhandarkar D, Katara A, Udwadia TE. Single incision bilateral laparoscopic oophorectomy. *J Minim Access Surg* 2011 Jan-Mar;7(1):87-89.
12. Garg P, Misra S, Song J. Single incision laparoscopic surgery—ovarian cystectomy in large benign cyst by using conventional instruments. *J Minim Access Surg* 2011 Oct-Dec;7(4):232-235.
13. Hamzaoglu I, Karahasanoglu T, Aytac E. Transumbilical totally laparoscopic single port nissen fundoplication: a new method of liver retraction. The Istanbul technique. *J Gastrointest Surg* 2010 Jun;14(5):1035-1039.
14. Egi H, Hattori M, Hinoi T, Takakura Y, Kawaguchi Y, Shimomura M, Tokunaga M, Adachi T, Urushihara T, Itamoto T. Single-port laparoscopic colectomy versus conventional laparoscopic colectomy for colon cancer: A comparison of surgical results. *World J Surg Oncol* 2012;10:61;1-6.
15. Eid GM, Mikami J. Advances in vessel sealing for laparoscopic bariatric surgery. *Clin Exp* 2012 Jun;39:6.
16. Dhumane PW, Diana M, Lorey J, Marescaux J. Minimally invasive single-site surgery for the digestive system: a technological review. *J Minim Access Surg* 2011 Jan-Mar;7(1):40-51.
17. Dubuc LJ. Use of a new energy based vessel ligation device during laparoscopic gynaecologic oncologic surgery. *Surg Endosc* Mar 2003;17(3):466-468.
18. Estelles JG, Aguilar JG, Castello JM. Transumbilical single incision laparoscopic hysterectomy for large uterus: Feasibility of the technique. *Gynecol Surg* 2010 Mar;7:143-148.
19. Koyanagi T, Motomura S. Transumbilical single incision laparoscopic surgery: application to laparoscopically assisted vaginal hysterectomy. *Arch Gynecol Obstet* 2011 Feb;283(2):305-309.
20. Young SC, Shin K-S, Choi J, Park J-N, Oh Y-S, Rhee T-E. Single-port access laparoscopy-assisted vaginal hysterectomy: Our initial experiences with 100 cases. *Minim Invasive Surg* 2012;2012:1-5.
21. Matthews BD. Effectiveness of the ultrasonic coagulating shears, LigaSure vessel sealer, and surgical clip application in biliary surgery: A comparative analysis. *Am Surg* 2001 Sep;67(9):901-906.
22. Onder S, Ilknur IG. Laparoscopic supracervical hysterectomy, bilateral salpingo-oophorectomy, sacrocolpopexy and burch colposuspension performed during the same operative session via a single port. *Arch Gynecol Obstet* 2011;283 (Suppl 1): S127-S131.
23. Felix CB, Timothy D. Single-port laparoscopic surgery in children: Concept and controversies of the new technique. *Minim Invasive Surg* 2012;2012:1-6.
24. Sendag F, Tarun V, Zeybek B, Bilgin O. Transumbilical single-incision total laparoscopic hysterectomy: technique and initial experience in Turkey. *Ginekolo Pol* 2012 Aug;83(18):581-585.
25. Orawee C, Chailert P. Transumbilical single incision laparoscopic hysterectomy with conventional laparoscopic instruments in patients with symptomatic leiomyoma and/or adenomyosis. *Arch Gynecol Obstet* 2011 Oct;284(4):893-900.
26. Liliana M, Alessandro P, Giada C, Luca M. Single port access laparoscopic hysterectomy: a new dimension of minimally invasive surgery. *J Gynecol Endosc Surg* 2011 Jan-Jun;2(1): 11-17.
27. Erik NH, Oliver JM. Single incision laparoscopic splenectomy in a 5-year-old with hereditary spherocytosis. *JSLs* 2010 April-Jun;14(2):286-288.
28. Fagotti A, Fan fani F, Rossitto C, Morocco F, Gallotta V. Laparoendoscopic single site surgery for the treatment of benign adnexal disease: a prospective trial. *Diag Therap Endo* 2010; 2010:1-4.
29. Maxime M, Lamouredieu C, Lazard A, Crallello L, Gamorre M, Agostini A. Salpingectomy for ectopic pregnancy by transumbilical single site laparoscopy with the SILS system. *Eur J Obstet Gynecol Reprod Biol* 2012 May;162(1):67-70.
30. Toshiaki E. A remarkably easy knot-tying technique for single-incision laparoscopic surgery with the SILS port for gynecologic diseases. *J Minimal Invasive Gynecol* 2011 July; 18(14):500-502.
31. Ekc, IB. A simple knot tying technique in SILS. *Clinics* 2010; 65(10):1055-1057.
32. Jun K. Linear salpingotomy with suturing by single incision laparoscopic surgery for tubal ectopic pregnancy. *Acta Obstet Gynecol Scand* 2010 Dec;89(12):1604-1607.

ABOUT THE AUTHOR

B Beena Kumari

Assistant Professor, Department of Obstetrics and Gynecology, PES Institute of Medical Sciences and Research, Kuppam, Andhra Pradesh India, e-mail: drbeenaakumari@gmail.com

A Review of Randomized Controlled Trials comparing Single Port Laparoscopic Cholecystectomy with Conventional Laparoscopic Cholecystectomy

Chukwuemeka Chukwunwendu Osuagwu

ABSTRACT

Aim: To determine the safety and benefits of single port laparoscopic cholecystectomy.

Materials and methods: A search for randomized controlled trials comparing single port laparoscopic cholecystectomy with conventional laparoscopic cholecystectomy was conducted using Google scholar, HighPress and SCOPUS.

Results: Single port laparoscopic cholecystectomy has a longer operating time, with equivocal postoperative pain, and offers better cosmetic result with low morbidity.

Conclusion: Single port laparoscopic cholecystectomy is at least as safe as conventional laparoscopic cholecystectomy in carefully selected patients.

Keywords: Single incision laparoscopic cholecystectomy, Conventional laparoscopy, Randomized controlled trial.

How to cite this article: Osuagwu CC. A Review of Randomized Controlled Trials comparing Single Port Laparoscopic Cholecystectomy with Conventional Laparoscopic Cholecystectomy. *World J Laparosc Surg* 2013;6(2):93-97.

Source of support: Nil

Conflict of interest: None declared

INTRODUCTION

Gallstone disease is a common surgical condition. Everhart et al in a national survey in the United States found that 6.3 million men and 14.2 million women who were within the age range of 20 to 74 years were afflicted with gallbladder disease. Gallstone disease is a least twice as common in females as in males.¹ In Europe, the prevalence was found to vary from 5.9% in Italy to 21.9% in Norway.² The incidence rate in Europe is about 0.63 to 0.93/100 persons/year^{3,4} which may reflect the increasing demand for cholecystectomy. In Taiwan, a lower prevalence of gallstone disease was noted 4.6% in men and 5.4% in women; however, there was no difference in sex prevalence.⁵ In Africa, a hospital prevalence of 747 cases in 4 years with a male to female ratio of 1:5 was also reported.⁶

Cholecystectomy is the proven treatment for symptomatic gallstone disease.⁶ Open cholecystectomy is the mainstay of surgical treatment of gallbladder disease; however, it has evolved in terms of the access to the gallbladder. Muhe in 1985 introduced laparoscopic cholecystectomy,⁷ which subsequently, became the gold standard of care⁸ because it offered better cosmetic outcome, reduced postoperative pain with early return to normal

physical activity⁹ as well as comparative levels of patient safety. During conventional, traditional, four-port laparoscopic cholecystectomy complementary procedures, such as laparoscopic intraoperative cholangiography using contrast may be performed¹⁰ to define the extrahepatic biliary anatomy and determine the presence of common bile duct stone. Some authors have also performed transcystic duct balloon dilatation of sphincter of Oddi during conventional laparoscopic cholecystectomy which is effective in flushing common bile duct stones into the duodenum in 85% of cases.¹¹

In 1997, Navarra performed the first single incision laparoscopic cholecystectomy.¹² Single incision laparoscopic cholecystectomy also goes by other terminologies, such as transumbilical laparoscopic cholecystectomy,¹³ single port laparoscopic cholecystectomy,¹⁴ natural orifice transumbilical surgery (NOTUS)¹⁵ cholecystectomy and laparoendoscopic single site (LESS) cholecystectomy.¹⁶ The popularity of single incision laparoscopic surgery is driven by reports of improved cosmesis,¹⁷ further reduction in postoperative pain alongside comparative safety.¹⁸ However, there are difficulties with swording of instruments and loss of triangulation¹⁹ as well as increased operating time, and port site hernia, and increased risk of conversion. The safety of single port laparoscopic cholecystectomy should be determined compared with the standard of care as recent reports suggest that advanced procedures, such as laparoscopic cholangiography is being undertaken during single port laparoscopic cholecystectomy with some success.^{20,21} Therefore, it is necessary to review randomized control trials that compared the single port laparoscopic cholecystectomy with the four-port laparoscopic cholecystectomy.

AIM

To compare safety of single incision laparoscopic cholecystectomy with conventional laparoscopic cholecystectomy with emphasis on the operating time, postoperative pain, and cosmesis (Table 1), and bile duct injuries as well as conversion rate.

MATERIALS AND METHODS

A search of published randomized controlled trails comparing single port laparoscopic cholecystectomy with

Table 1: Randomized controlled trials comparing single-port laparoscopic cholecystectomy with conventional laparoscopic cholecystectomy

Authors	Number of patients in single port laparoscopic cholecystectomy study arm	Number of patients in single port laparoscopic cholecystectomy controls	Operation time	Postoperative pain	Cosmesis	Difficult exposure and bile duct injuries	Conversion	Postoperative wound infection
1. Bucher P, Pugin F, Buchs N, Ostermann S et al ²³	75	75	Similar	SPLC; reduced postoperative pain ($p < 0.001$)	Better cosmetic outcome and body image scar scale ($p < 0.001$)	None	2 SPLC converted 1 LC converted to SPC due to adhesions	SPLC; CLC 3:4 for seroma/hematoma
2. Aprea G, Bottazz E, Guida F, Masone S et al ²³	25	25	Operation time was longer in SPLC ($p < 0.04$)	No difference in postoperative pain	Better cosmesis with SPLC ($p = 0.05$)	None	None	None
3. Marks J, Tacchino R, Roberts K, Onders R et al ²⁵	50	33	Longer in SPLC ($p < 0.003$)	No difference in pain	SPLC had better body image cosmesis from 1 week, $p = 0.0002$ - 0.0004 at 3 months	None	One SPLC to four-port LC	Incisional hernia at 3 months in SPLC
4. Lirici, M, Califano, A, Angelini, P, Corcione F ¹⁶	20	20	Double blinded longer operation time in SPLC (0.001)	CLC less painful first day postoperative pain $p = 0.04$	Better cosmesis ($p = 0.025$)	D + (0.004)	No conversion	None
5. Lai E, Yang G, Tang C, Yih P, Chan O, Li M ³⁰	24	27	Longer for SPLC	SPLC more painful on day 7 compared to LC	SPLC has better cosmesis	None	None	None
6. Ma J, Maria S, Georg O, Hammill C et al ²⁷	21	22	Significantly longer operation time in SPLC ($p < 0.05$)	No difference	No difference	—	—	No difference
7. Tsimogiannis EC, Tsimogiannis KE, Pappas-Gogos G et al ¹⁸	20	20	Operation time is longer in SPLC	Two blinded independent less pain in SPLC	—	CBD leakage in one CLC and two SPLC had postoperative bile leakage	—	—
8. Chang S, Wang Y, Shen L, Iyer S, Shaik A, Lomanto D et al ²⁴	24	26	Similar operation time	SPLC lower pain at umbilical (0.002 at rest and during movement) and other sites (0.004)	Cosmesis better in SPLC but it is not statistically significant	—	—	—
9. Zheng M et al ²⁸	28	30	Operation time longer in SPLC (0.03)	SPLC less post-operative pain and mean pain index lower ($p = 0.0003$)	SPLC better satisfaction (0.012)	—	Two SPLC were converted	—
10. Phillips M, Marks J, Roberts K, Tacchino R et al ²⁶	117	80	Blinded multicenter RCT (10 centers) Operation time Longer in SPLC ($p < 0.00001$)	Postoperative pain less in CLC ($p = 0.028$)	Cosmesis better for SPLC ($p = 0.002$)	None	Conversion to CLC in one patient	Wound infection higher in SILS ($p = 0.047$) but hernia were equal in both arms

SPLC: Single port laparoscopic cholecystectomy; CLC: Conventional laparoscopic cholecystectomy; RCT: Randomized controlled trials

conventional cholecystectomy in databases such as Google Scholar, Highwire press, and PubMed, and SCOPUS between 1st January 2009 and 20th February 2013 was made using search terms, such as single incision laparoscopic cholecystectomy, single port cholecystectomy, and minimally invasive cholecystectomy. Other synonyms were included in the search, such as transumbilical laparoscopic cholecystectomy, nearly scarless cholecystectomy and laparoendoscopic single site cholecystectomy, NOTUS cholecystectomy. These studies must compare conventional laparoscopic cholecystectomy, or its synonyms, such as traditional laparoscopic cholecystectomy and Four-port laparoscopic cholecystectomy.

Inclusion Criteria

- Articles published in English.
- Publications between 1st January 2009 and 20th February 2013.
- Randomized controlled trials.
- The patients are adults aged 18 years up to 90 years old.
- The articles must evaluate any of the following criteria, operating time, postoperative pain and cosmesis, and bile duct injury and postoperative wound infection and conversion.

Exclusion Criteria

Randomization with bias or Quasi randomization. Eleven randomized controlled trials were found, but one study was excluded because the randomization was biased, hence, 10 studies were considered.

DISCUSSION

Operating Time

Operating time is an important consideration because it offers some idea about the difficulty of a surgical procedure. Single incision cholecystectomy is associated with crossing of instrument intracorporeally as well as the ends of trocars and handles of the hand instruments impeding the extracorporeal instrumentation. It depicts the time from the first incision on the patient to the closure of the last incision on the patient. There were no differences in the mean operation time in two studies (Figs 1 and 2),^{23,24} similarity in the operating time noted in these results may be as a result of the similarity in the instruments used which are the chip on tip flexible telescope and the articulated instruments. While the mean operating time for conventional laparoscopic cholecystectomy was shorter and statistically significant ($p = 0.003$,²⁵ $p = 0.001$ ¹⁶ and $p = 0.00001$).²⁶ These variations may be partly explained by the differences in the level of skill of different surgeons' involved in the

trials as well as the learning curve within each trial group. A decline in operating time of about 21 minutes was observed between the first five single port laparoscopy procedures and the last five procedures, more so, two surgeons with more than 15 years experience in advanced laparoscopic surgery and transanal endoscopic microsurgery performed all the procedures.¹⁶ Other studies showed mean operating times for conventional laparoscopic cholecystectomy that were marginally statistically significant ($p = 0.03$),²⁷ $p = 0.05$.²⁶ Phillips et al demonstrated a highly statistically significant difference in the mean operating time in a multicenter study involving 10 centers which enrolled a large number of participating patients.

Postoperative Pain

The reduction in postoperative pain is a one of the benefits of single incision laparoscopic cholecystectomy. Conventional laparoscopic cholecystectomy involves about three to four multiple incision, rather than one umbilical incision used in single port laparoscopic cholecystectomy. Other factors that may cause postoperative pain include irritation of the peritoneum under the diaphragm by the carbon dioxide used in creating the pneumoperitoneum, and

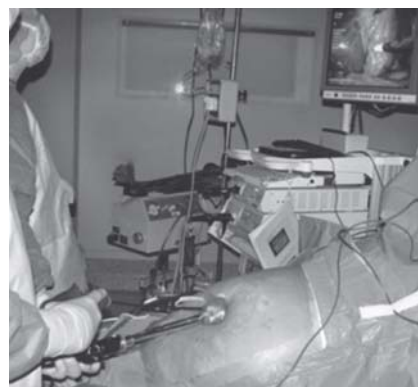


Fig. 1: Laparoendoscopic single-site cholecystectomy²³

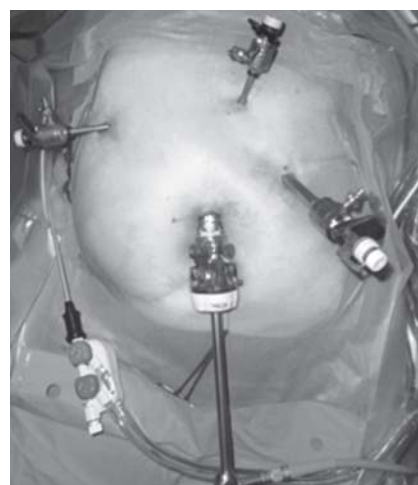

Fig. 2: Conventional laparoscopic cholecystectomy²³

pressure at the port sites. Postoperative pain parameter was accessed in all the randomized controlled trials. There was no difference in the severity of postoperative pain experienced by the study group and controls.^{24,26,28} Other authors noted that postoperative pain was lower in patients who underwent conventional laparoscopic cholecystectomy ($p = 0.04$,¹⁶ $p = 0.028$).²⁵ Some results noted that single port laparoscopic cholecystectomy resulted in less postoperative pain as ($p = 0.001$,²² $p = 0.002$).²³ These conflicting results may arise from the difference in the timing used in assessing the postoperative pain.

Cosmesis and Body Image

Cosmetic appearance of the abdominal wound after surgery was assessed using the scar satisfaction scale. Cosmesis was assessed in all the studies reviewed except for Tsimoyiannis et al.¹⁸ The cosmetic outcome was in favor of single port laparoscopic cholecystectomy except for one study that reported that there was no difference.²⁶ Another study noted that the reported difference was not statistically significant.²³ However, seven of the studies reviewed reported a better cosmetic appearance outcome^{16,22,24,25,27-29} which were statistically significant. The study that detected the highest statistically significant difference in cosmesis ($p = 0.0002$) had assessed cosmesis after single port laparoscopic cholecystectomy at 2 weeks.²⁴ All the cosmetic evaluations in clinical trials reviewed were done within the first 3 months of surgery. The cosmetic appearance of conventional laparoscopic cholecystectomy after 4 years was judged to be excellent by a retrospective study.^{31,32} This may be considered in choosing the between single port cholecystectomy and conventional laparoscopic cholecystectomy.

Bile Duct Injuries and Conversion

Bile duct injuries were uncommon in the studies reviewed. Two cases of postoperative bile duct leaks were reported following single port laparoscopic cholecystectomy while one bile duct injury occurred following conventional laparoscopic cholecystectomy. This is similar to the finding of bile duct leaks in (0.6%) of procedures performed as single port laparoscopic cholecystectomy.³⁰ These bile leaks resolved spontaneously following closed drainage.¹⁸ These leaks may arise from the accessory hepatic duct, from the cystic duct stump or from the common bile duct as a result of use of energy devices. There were seven conversions from single incision laparoscopic cholecystectomy to conventional laparoscopic cholecystectomy in very few procedures^{22,24,25,27} while one conventional laparoscopic cholecystectomy was converted to single port chole-

cystectomy due to upper abdominal adhesions obscuring port placement.²² This is an unusual conversion which should be borne in mind as an advantage of single port laparoscopic cholecystectomy.

Postoperative Wound Infections and Other Wound Complications

Wound hematoma was noted in three cases of single incision laparoscopic surgery compared to four cases observed following conventional laparoscopic cholecystectomy²⁴ this is similar to about 17 cases observed in a review of 1,180 cases.³⁰ Wound infections were uncommon, and occurred more frequently in the single port laparoscopic cholecystectomy, and was statistically significant ($p = 0.04$).²⁵ This may be due to the pressure necrosis from the snugly fit port as well as extraction of the inflamed gallbladder through the umbilicus. Umbilical hernia occurred more frequently following single port laparoscopic cholecystectomy. Other studies found that these were evenly distributed between the two arms;²⁵ however, umbilical incisional hernia may be related more to technical failure in the repair of the umbilical port.

CONCLUSION

The randomized controlled trial that were available were relatively few, and the sample sizes were small, this may explain the failure to detect statistically significant differences in many of the safety criteria evaluated. However, improved cosmesis is the most consistent benefit derived from the trials, it is also noteworthy that bile duct leaks were low and no mortality was reported. These remarkably good outcomes may be spurious considering the meticulous criteria adopted in selecting the patients that participated in this study. Large scale multicenter trials are needed to challenge the findings in this review.

REFERENCES

1. Everhart JE, Khare M, Hill M, Maurer KR. Prevalence and ethnic differences in gallbladder disease in the United States. *Gastroenterology* 1999;117(3):632-39. [http://dx.doi.org.ezproxy.liv.ac.uk/10.1016/S0016-5085\(99\)70456-7](http://dx.doi.org.ezproxy.liv.ac.uk/10.1016/S0016-5085(99)70456-7)
2. Barbara L, Sama C, Morselli Labate AM, et al. A population study on the prevalence of gallstone disease: The Sirmione study. *Hepatology* 1987;7:913-17.
3. Angelico F, Del-Ben M, Barbato A, et al. Ten-year incidence and natural history of gallstone-disease in a rural population of women in central Italy. The Rome Group for the Epidemiology and prevention of Cholelithiasis (GREPCO). *Ital J Gastroenterol* 1997;29:249-54.
4. Jorgensen T, Hougaard JT. Eleven-year cumulated incidence of gallstone formation in an unselected Danish population. *Gastroenterology* 1996;110(Suppl 4):A21.

5. Chen CH, Huang MH, Yang JC, Nien CK, Etheredge GD, Yang CC, et al. Prevalence and risk factors of gallstone disease in an adult population of Taiwan: An epidemiological survey. *J Gastroenterol Hepatol* 2006;21:1737-43. DOI: 10.1111/j.1440-1746.2006.04381.x <http://onlinelibrary.wiley.com.ezproxy.liv.ac.uk/DOI/10.1111/j.1440-1746.2006.04381.x/full>
6. Ersumo T. Gallstone disease in a teaching hospital, Addis Ababa: A 5-year review. *Ethiop Med J* 2006;44(1):49-59. <http://www.ncbi.nlm.nih.gov/pubmed/17447363>.
7. Litynski GS. Erich Mühe and the rejection of laparoscopic cholecystectomy (1985): A surgeon ahead of his time. *JSLs* 1998;2:341-46.
8. Begos DG, Modlin IM. Laparoscopic cholecystectomy: From gimmick to gold standard. *J Clin Gastroenterol* 1994;19(4):325-30. PMID: 7876516. <http://europepmc.org/abstract/MED/7876516/reload=0;jsessionid=VKrURaNI8mhVBJZXBt8c.0>
9. McMahon AJ, Baxter JN, Anderson JR, Ramsay G, O'Dwyer PJ, Russell IT, et al. Laparoscopic versus minilaparotomy cholecystectomy: A randomised trial. 1994;343(8890):135-38. DOI: org.ezproxy.liv.ac.uk/10.1016/S0140-6736(94)90932-6, <http://www.sciencedirect.com.ezproxy.liv.ac.uk/science/article/pii/S0140673694909326>
10. Huang SM, Wu CW, Chau GY, Jwo SC, Lui WY, P'eng FK. An alternative approach of choledocholithotomy via laparoscopic choledochotomy. *Arch Surg* 1996;131(4):407-11. DOI: 10.1001/archsurg.1996.01430160065012. <http://archsurg.jamanetwork.com.ezproxy.liv.ac.uk/article.aspx?articleid=596490>.
11. Carroll B, Phillips E, Chandra M, Fallas M. Laparoscopic transcystic duct balloon dilatation of the sphincter of Oddi. *Surg Endosc* 1993;7(6):514-17. <http://link.springer.com.ezproxy.liv.ac.uk/article/10.1007%2FBF00316692?LI=true>
12. Navarra G, Pozza E, Occhionorelli S, Carcoforo P, Doninin I. One-wound laparoscopic cholecystectomy. *Br J Surg* 1997; 84:695.
13. Piskun G, Rajpal S. Transumbilical laparoscopic cholecystectomy utilizes no incisions outside the umbilicus. *J Laparoendosc Adv Surg Tech A* 1999;9(4):361-64.
14. Mutter D, Callari C, Diana M, et al. Single port laparoscopic cholecystectomy: Which technique, which surgeon, for which patient? A study of the implementation in a teaching hospital. *J Hepatobiliary Pancreat Sci* 2011;18(3):453-57.
15. Nguyen NT, Reavis KM, Hinojosa MW, Smith BR, Wilson SE. Laparoscopic transumbilical cholecystectomy without visible abdominal scars. *J Gastrointest Surg* 2009;13:1125-28.
16. Lirici M, Califano A, Angelini P, Corcione F. Laparo-endoscopic single site cholecystectomy versus standard laparoscopic cholecystectomy: Results of a pilot randomized trial. *Am J Surg* 2011;202:45-52.
17. Cuesta M, Berends F, Veenhof A. The invisible cholecystectomy: A transumbilical laparoscopic operation without a scar. *Surg Endosc* 2008;22(5):1211-13.
18. Tsimoyiannis EC, Tsimogiannis KE, Pappas-Gogos G, Farantos C, Benetatos N, Mavridou P, et al. Different pain scores in single transumbilical incision laparoscopic cholecystectomy versus classic laparoscopic cholecystectomy: A randomized controlled trial. *Surg Endosc* 2010;24:1842-48.
19. Yilmaz H, Alptekin H, Acar F, Ciftci I, Tekin A, Sahin M. Experiences of single incision cholecystectomy. *Intl J Med Sci* 2013;10(1):73-78.
20. Ishikawa N, Arano Y, Shimizu S, Morishita M, Kawaguchi M, Matsunoki A, et al. Single-incision laparoscopic surgery (SILS) using cross hand technique. *Minim Invasive Ther Allied Technol* 2009;18:322-24.
21. Patel A, Murgatroyd B, Carswell K, Belgaumkar A. Fundus-first transumbilical single-incision laparoscopic cholecystectomy with a cholangiogram: A feasibility study. *Surg Endosc* 2011; 25(3):954-57.
22. Yeo D, Mackay S, Martin D. Single-incision laparoscopic cholecystectomy with routine intraoperative cholangiography and common bile duct exploration via the umbilical port. *Surg Endosc* 2012;26(4):1122-27.
23. Bucher P, Pugin F, Buchs N, Ostermann S, Morel P. Randomized clinical trial of laparoendoscopic single-site versus conventional laparoscopic cholecystectomy. *BJS* 2011;98:1695-702. DOI: 10.1002/bjs.7689
24. Chang S, Wang Y, Shen L, Iyer S, Shaik A, Lomanto D. Interim report: A randomized controlled trial comparing postoperative pain in single-incision laparoscopic cholecystectomy and conventional laparoscopic cholecystectomy. *Asian J Endosc Surg* 2013;6:14-20. ISSN 1758-5902.
25. Marks J, Tacchino R, Roberts K, Onders R, Denoto G, Paraskeva P, et al. Prospective randomized controlled trial of traditional laparoscopic cholecystectomy versus single-incision laparoscopic cholecystectomy: Report of preliminary data. *Am J Surg* 2011;201:369-73.
26. Phillips MS, Marks JM, Roberts K, Tacchino R, Onders R, DeNoto G, et al. Intermediate results of a prospective randomized controlled trial of traditional four-port laparoscopic cholecystectomy versus single-incision laparoscopic cholecystectomy. *Surg Endosc* 2012;26:1296-303.
27. Ma J, Cassera MA, Spaun GO, Hammill CW, Hansen PD, Aliabadi-Wahle S. Randomized controlled trial comparing single-port laparoscopic cholecystectomy and four-port laparoscopic cholecystectomy. *Annals Surg* 2011;254(1):22-27.
28. Zheng M, Qin M, Zhao H. Laparoendoscopic single-site cholecystectomy: A randomized controlled study. *Minimally Invasive Therapy* 2012;21:113-17.
29. Aprea G, Bottazz E, Guida F, Masone S, Persico G. Laparoendoscopic single site (LESS) versus classic video-laparoscopic cholecystectomy: A randomized prospective study. *J Surg Res* 2011 Apr;166(2):e109-12.
30. Lai E, Yang G, Tang C, Yih P, Chan O, Li M. Prospective randomized comparative study of single incision laparoscopic cholecystectomy versus conventional four-port laparoscopic cholecystectomy. *Am J Surg* 2011;202(13):254-58. [http://www.americanjournalofsurgery.com/article/S0002-9610\(11\)00209-1/fulltext](http://www.americanjournalofsurgery.com/article/S0002-9610(11)00209-1/fulltext)
31. Fransen S, Stassen L, Bouvy N. Single incision laparoscopic cholecystectomy: A review on the complications. *J Minim Access Surg* 2012;8(1):1-5. <http://www.ncbi.nlm.nih.gov/pmc/articles/PMC3267328/>
32. Bignell M, Hindmarsh A, Nageswaran H, Mothe B, Jenkinson A, Mahon D, et al. Assessment of cosmetic outcome after laparoscopic cholecystectomy among women 4 years after laparoscopic cholecystectomy: Is there a problem? *Surg Endosc* 2011 Aug;25(8):2574-77.

ABOUT THE AUTHOR

Chukwuemeka Chukwunwendu Osuagwu

Consultant General Surgeon, Department of Surgery, University of Nigeria Teaching Hospital Enugu, Ituku-Ozalla, Enugu State, Nigeria
e-mail: osuagwuemy@yahoo.com

Laparoscopic Management for Hydatid Disease of Liver: Experience of Single Center

Ridvan Yavuz, Firat Demircan

ABSTRACT

Objectives: The objectives of this study were to investigate the characteristics and outcome of patients with hydatid disease of the liver who were laparoscopically managed at our clinic and to define technical details of the method.

Materials and methods: Between January 2011 and June 2012, 11 patients with hydatid disease of the liver were considered for laparoscopic surgery in our department. All the patients underwent to laparoscopic surgical interventions.

Results: In all patients, laparoscopic cystotomy, unroofing with laparoscopic cutting and sealing instruments for surgical dissection and omentoplasty were performed. No conversion to laparotomy was necessary. No radiological recurrences was observed in a mean follow-up of 11 months (range: 3-18 months).

Conclusion: Laparoscopy is quite feasible to perform in hydatid disease of the liver and, the use of laparoscopic cutting and sealing instruments allows effective dissection and partial cystectomy. Cyst size and grade is not restrict laparoscopic surgery for liver hydatid disease. Obliteration of the residual cystic cavity decreases postoperative complication rates, so an effective omentoplasty is essential especially for laparoscopic procedures. The use of helical fasteners allows effective omental flap fixation.

Keywords: Hydatid disease, Laparoscopy, Laparoscopic cutting and sealing instruments.

How to cite this article: Yavuz R, Demircan F. Laparoscopic Management for Hydatid Disease of Liver: Experience of Single Center. World J Laparosc Surg 2013;6(2):98-101.

Source of support: None

Conflict of interest: In this study, we want to share our experience with you. We think that, laparoscopic management is practicable for liver hydatid disease in selected cases. But open technique is favored especially peripheral hospitals. We think surgeons can be more brave in this subject. Also about the technique, using laparoscopic cutting and sealing system and helical fastener is helpful.

INTRODUCTION

Echinococcus granulosus, a cestode that is commonly lodged in the liver, causes human hydatid disease. Several endemic regions exist; however, the disease may be observed anywhere in the world.¹ Surgery is the main modality of treatment, despite advances in medical and minimally invasive radiological therapies.² In the last decade, laparoscopic surgery has become apart of the discussion of this issue, and several studies have reported encouraging results.^{3,4} Whatever the technique, surgeons should focus on safe evacuation and sterilization of the cyst's cavity.

Herein, we report our series of patients with hydatid disease of the liver who underwent to laparoscopic surgery, including the use of laparoscopic cutting and sealing instruments for dissection and unroofing completed omentoplasty and fixation of the omentum with helical fasteners.

PATIENTS AND METHODS

Between January 2011 and June 2012, 11 patients (three male and eight female), mean age of 30 years (range: 14-58 years) with hydatid disease of the liver were considered for laparoscopic surgery at our department. Nine patients had single cysts, and two patients had two cysts. Six cysts were in the right lobe, and three were in the left. In the patients who had two, one cyst was in the right and the other in the left lobe. The mean diameter of the cysts was 11 cm (range: 4-22 cm). Diagnostic procedure was based on radiological examinations including computerized tomography (CT), ultrasonography (US), and specific serological examinations. Nevertheless, cysts that were diagnosed on ultrasonographic examination were also confirmed by tomographic studies. No evidence or suspicion of biliary rupture existed upon clinical findings and radiological studies (history of cholangitis or jaundice, evidence of dilatation of the biliary tree, or connection with the cyst). Serological test, such as indirect hemagglutination tests (IHA) and ELISA were positive in all patients. The patients who had evidence of biliary rupture, a history of recurrence, cysts deep or difficult to access in liver (central or posterior localizations), and cysts with calcified walls were not considered as candidates for laparoscopy.

OPERATIVE TECHNIQUE

All patients received general anesthesia. The urinary bladder was catheterized, a nasogastric tube was placed, and antibiotics were administered half an hour prior to the operation. The operation was performed in the lithotomy position. The first trocar was inserted at the umbilicus by open technique and insufflation for pneumoperitoneum. Thirty-degree laparoscope was used to visualize the peritoneal cavity. The operating surgeon stood between the patient's legs; the camera assistant managed the laparoscope from the left for right-sided cysts and from the right for left-sided cysts. Two additional 10 mm trocars were

inserted from the optimum points chosen during exploration. A 5 mm trocar was inserted from optimum points for using second aspirator too. The cyst then was punctured from the apex with a Veress needle and the cyst's fluid was aspirated as much as possible (Fig. 1). The cyst was refilled with 20% hypertonic saline, which is a potent scolical agent and left for 5 minutes. During this procedure, a 5 mm aspirator was placed beside the puncture point to prevent any fluid spillage into the peritoneal cavity. The cyst's content was reaspirated. Thereafter, Veress needle was extracted and puncture was enlarged with electrocautery for replace a 5 mm laparoscopic irrigation and sucking instrument. The cyst was refilled with 20% hypertonic saline and left 5 minutes. During this procedure, fluid spillage was prevented by second 5 mm aspirator (Fig. 2). The cyst's contents, including germinative membrane and daughter cysts, were aspirated. Irrigation with 20% saline was again performed. The superficial and visible part of the cystic wall was dissected with 10 mm laparoscopic cutting and sealing instrument (Ligasure Atlas™, Covidien, Norwalk, Connecticut, USA) and electrosurgical hook, and the specimen was removed from the abdominal cavity within an endobag (Fig. 3). The cystic cavity was then explored with a laparoscope to check whether any remnants of the cyst, biliary rupture, or hemorrhage were present. An adequate portion of greater omentum was pulled and inserted into the cyst's cavity. The omentum was fixed to the cut edges of the cyst wall with a helical fastener (Pro Tack, Autosuture, Norwalk, Connecticut, USA) (Fig. 4). The abdominal cavity was irrigated and aspirated with saline solution. Two drain was placed into the cyst's cavity and rectovesical process. A clear diet was allowed the next day. The drain was removed and the patient was discharged if no bile or ascites drainage were present. Albendazole was administered, 10 mg/kg/day, for a month preoperatively and for 3 months postoperatively, and an intermittent therapy regimen was planned as a 3-week course of drug therapy and 1 week of no treatment. Radiological controls with CT and US were performed in the 6 months, and then annually.

RESULTS

In all patients, laparoscopic cystotomy, partial cystectomy, and omentoplasty were performed. No conversion to laparotomy was necessary, and the procedures were accomplished uneventfully. The mean operation time was 80 minutes (range: 60-130 minutes). No perioperative or postoperative complication was seen.

The mean hospital stay was 6 days (range: 3-9 days). No radiological recurrence was observed in a mean follow-up duration of 11 months (range: 3-18 months).

DISCUSSION

Since 1990s, laparoscopic treatment of hydatid disease of the liver has been carried out in many centers. The general approach is like open surgery. Regardless of the method,

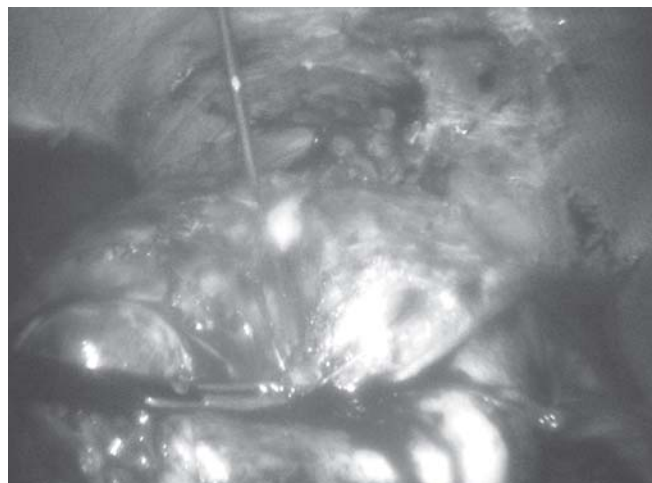


Fig. 1: Aspiration of cyst fluid with Veress needle



Fig. 2: Aspiration cyst contents with 5 mm aspirator and controlling the spillage with another one

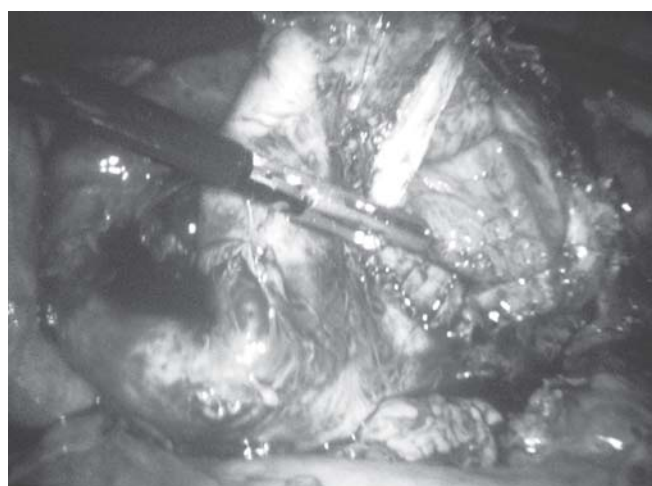

Fig. 3: Resection of partial cyst wall with electrosurgical hook and Ligasure

the surgical principles are sterilization of the cyst cavity, careful evacuation of the cyst's content without intraperitoneal spread, investigation of the biliary rupture, and obliteration of the cyst's cavity. To succeed in laparoscopic hydatid disease surgery, these objectives are best reached with the studiously selection of patients. As for current opinion, most laparoscopic surgeons prefer

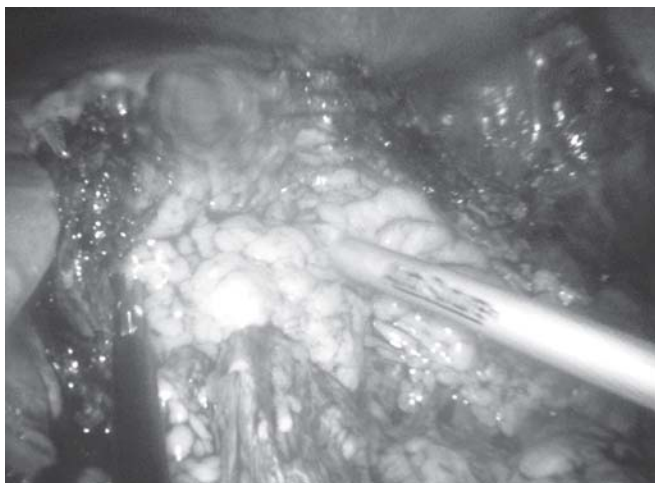

Fig. 4: Fixation of omentum to the cyst cavity with helical fastener

simple drainage procedures with or without partial cystectomy.^{3,4}

In our series, we excluded the patients who had deep parenchymal cysts, allocated posterior liver, evidence of biliary rupture and recurrent cysts. Posterior or deep in liver parenchymal cysts are difficult for laparoscopic approach. Deep allocated liver hydatid cysts are increased risk of biliary rupture and inconvenience the laparoscopic exploration. Some authors suggest to exclude the patients with cysts larger than 15 cm, grade IV-V cysts.⁵ In our series, we did not limited cyst size and grade. For one of the case who had 22 cm cyst allocated right lobe, we performed laparoscopic partial pericystectomy and omentoplasty (Fig. 5). We performed laparoscopic surgery for 7 patients; four of them have grade III and three of them have grade IV hydatid cysts. None of 7 patients experienced biliary rupture. We have seen that the laparoscopic approach is suitable for the large and grade III-IV cysts for the liver hydatid disease. We used lithotomy position and standing between the legs of patient. Some authors report they used different positions like a lateral decubitus or supine. We use 20% hypertonic saline for scholosomal solution as like the authors. In some recent reports, different techniques and

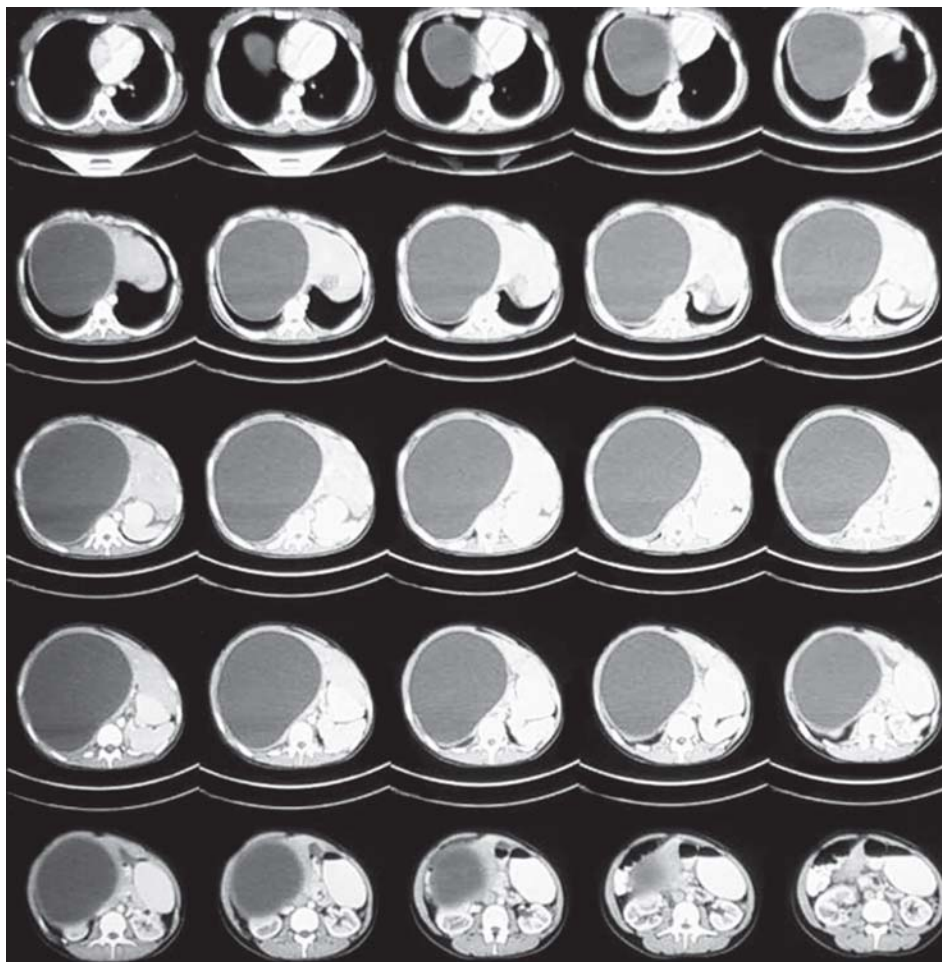


Fig. 5: Computer tomographic image of giant hydatid cyst in right lobe

instruments had been used to sterilize the cyst contents and to prevent any fluid spillage into the peritoneal cavity. Acarli et al report aspirator and grinder apparatus system to sterilize cyst contents.⁶ Altinli et al used inserting a locking trochar into the cyst cavity to minimize the contamination and laparoscopic aspirator for prevent the fluid spillage.⁵ Al-Shareef et al used liposuction device for perforation and aspiration cyst contents.⁷ In our series we aspirated germinatif membrane and doughter cysts with 5 mm aspirator and controlled the spillage with second 5 mm aspirator which was inserted from another trochar.

Ligasure combined with electrocooter for dissection of the cyst wall from the adhesions and resection of cyst wall for unroofing is safe and fast technique. Omentoplasty was recommended for prevention of postoperative abdominal complications.⁸ For this purpose, some authors have defined original omentoplasty techniques for laparoscopic hydatid disease surgery. Ertem et al reported an omentoplasty technique with staples.⁴ Altinli et al modified it by securing an omental flap to the edges of the excised cavity with helical fasteners and we agree that it is really fast and effective.⁵ In our series, we operated two patients who had two cysts that allowed easy access. We did not added any more trochar for second cyst. The preoperative CT images and patient body type can be helpful to decide laparoscopic or open approach with the multiple hydatid cysts.

Laparoscopic surgery for liver hydatid disease has been performed since 1990. Several authors improved various techniques in elapsed time. However, the laparoscopic approach for hydatid disease was limited in the central clinics which interested in a growing number of physicians already prefer open surgery for hydatid disease especially in peripheral states. The common reasons to avoid laparoscopic surgery depend on spillage of cyst contents in to the abdominal cavity, communion with biliary tree, fair of anaphylaxis and postoperative recurrence risk.^{6,8,9}

CONCLUSION

With growing experience, laparoscopy seems to be quite feasible in hydatid disease of the liver. However,

laparoscopy should not limit the surgeon's performance in every surgical step of hydatid disease surgery. In many instances, omentoplasty with helical fasteners provides an easy and effective obliteration of the cyst's cavity during laparoscopic access.

REFERENCES

1. Ammann RW, Eckert J. Cestodes echinococcus. *Gastroenterol Clin North Am* 1996;25:655-89.
2. King CH. Cestodes. In: Mandell GL, Benett JE, Dolin R (Eds). *Principles and practice of infectious diseases* (5th ed). Philadelphia, PA: Churchill Livingstone Inc 2000:2957-63.
3. Seven R, Berber E, Mercan S, Eminoglu L, Budak D. Laparoscopic treatment of hepatic hydatid cysts. *Surgery* 2000;128:36-40.
4. Ertem M, Uras C, Karahasanoglu T, Erguney S, Alemdaroglu K. Laparoscopic approach to hepatic hydatid disease. *Dig Surg* 1998;15:333-36.
5. Altinli E, Saribeyoglu K, Pekmezci S, Uras C, Tasci H, Akcal T. An effective omentoplasty technique in laparoscopic surgery for hydatid disease of the liver. *JSLs* 2002;6:323-26.
6. Acarli K. Controversies in the laparoscopic treatment of hepatic hydatid disease. *HPB Surg* 2004;6:213-21.
7. Al-Shareef Z, Hamour OA, Al-Shlash S, Ahmed I, Mohamed AA. Laparoscopic threatment of hepatic hydatid cysts with a liposuction device. *JSLs* 2002;6:327-30.
8. Dziri C, Paquet JC, Hay JM, et al. Omentoplasty in the prevention of deep abdominal complications after surgery for hydatid disease of the liver: A multicenter, prospective randomized trial. *French Associations for Surgical Research. J Am Coll Surg* 1999;188:281-89.
9. Khoury G, Jabbour-Khoury S, Soueidi A, Nabbout G, Baraka A. Anaphylactic shock complicating laparoscopic treatment of hydatid cysts of the liver. *Surg Endosc* 1998;12:452-54.

ABOUT THE AUTHORS

Ridvan Yavuz (Corresponding Author)

Specialist, Department of General Surgery, Diyarbakir Education and Research Hospital, Diyarbakir, Turkey, Phone: +904122580074 e-mail: dridvanyavuz@hotmail.com

Firat Demircan

Specialist, Department of General Surgery, Diyarbakir Education and Research Hospital, Diyarbakir, Turkey

Hysteroscopic Findings in an Unusual Case of Adenomyosis

Priya Bhav Chittawar, Shilpa Sapre, Shilpa Bhandari

ABSTRACT

Adenomyosis is the presence of ectopic endometrial glands and stroma in the myometrium. It traditionally presents with pelvic pain, menorrhagia and dysmenorrhea in the fourth or fifth decade of life. Here, we present a case of adenomyosis presenting with severe menorrhagia at the age of 23 years.

Traditionally, adenomyosis is diagnosed in histopathologically, in hysterectomy specimens or myometrial biopsies. Noninvasive modalities, such as transvaginal ultrasound and magnetic resonance imaging aid in diagnosis in the office before treatment is undertaken. Office hysteroscopy is an established tool in the diagnosis of abnormal uterine bleeding and infertility. While hysteroscopy does not have pathognomonic features of adenomyosis, certain patterns have been described in association with adenomyosis, including endometrial defects, abnormal vascularization and cystic hemorrhagic lesions.

In this case of adenomyosis, typical appearance of circumscribed endometrial defects on hysteroscopy was seen. This appearance has been described in literature but is the first report from India.

Hysteroscopy has the potential to be an important additional procedure for the evaluation of uterine pathology, even in the case of adenomyosis, because it offers the main advantage of direct visualization of the uterine cavity and the possibility of obtaining histological specimens under visual control.

With shifting focus toward conservative and fertility preserving management of adenomyosis, office hysteroscopy is likely to emerge as an important tool in the diagnostic armamentarium for adenomyosis.

Keywords: Adenomyosis, Hysteroscopy, Abnormal uterine bleeding.

How to cite this article: Chittawar PB, Sapre S, Bhandari S. Hysteroscopic Findings in an Unusual Case of Adenomyosis. *World J Laparosc Surg* 2013;6(2):102-104.

Source of support: Nil

Conflict of interest: None declared

INTRODUCTION

Adenomyosis is a benign disorder that is being increasingly diagnosed by noninvasive modalities, like transvaginal ultrasound and magnetic resonance imaging (MRI). Hysteroscopic picture of endometrial defects in adenomyosis has been described in literature once. We report one more case of adenomyosis presenting at an early age of 23 years with menorrhagia, with characteristic hysteroscopic picture of multiple circumscribed endometrial defects at the fundus.

CASE REPORT

Mrs S, a 23-year-old nulligravida, was admitted in emergency with heavy bleeding since 20 days. She was admitted outside and given progesterone in high doses, 4 units of blood transfusions and referred to us as a case of

fibroid uterus for myomectomy. There was no history of preceding amenorrhea.

Her previous cycles were prolonged with progressively worsening bleeding, flooding and passage of clots since 2 years. She was married for 3 years, not using any contraception and was desirous of conception. She was pale with stable vitals. Examination revealed a uterus of 14 weeks in size, soft, mobile and tender with free fornices. Investigations revealed Hb of 7 gm%, beta hCG <1 IU/ml, thyroid function was normal, viral screen was negative and coagulation profile was normal. Transvaginal ultrasound scan revealed a bulky uterus with thick posterior wall and myometrial cysts (Figs 1 and 2). She was taken for an MRI which showed bulky uterus with T1 bright foci suggestive of blood in myometrium and T2 bright areas in myometrium suggestive of myometrial cysts (Figs 3 and 4).

She continued to bleed despite progesterone and was planned for a hysterolaparoscopy proceed. Hysteroscopy showed enlarged uterine cavity with endometrial defects at the fundus. The endometrial defects were seen as multiple punched out, circumscribed lesions in the fundal area. A myometrial biopsy was attempted but tissue was inadequate for comment histopathologically. Both ostia were deep seated and right ostium showed periosteal fibrosis. Decision to undertake laparoscopy was taken to ascertain tubal status and consider adenomyoma resection, if focal disease was found (Figs 5 and 6). On laparoscopy, a bulky uterus covered with dense omental adhesions was found; an adhesiolysis was done (Fig. 7). The posterior wall of the uterus was diffusely enlarged and we decided against focal resection. Endometriotic blebs were seen in the POD.

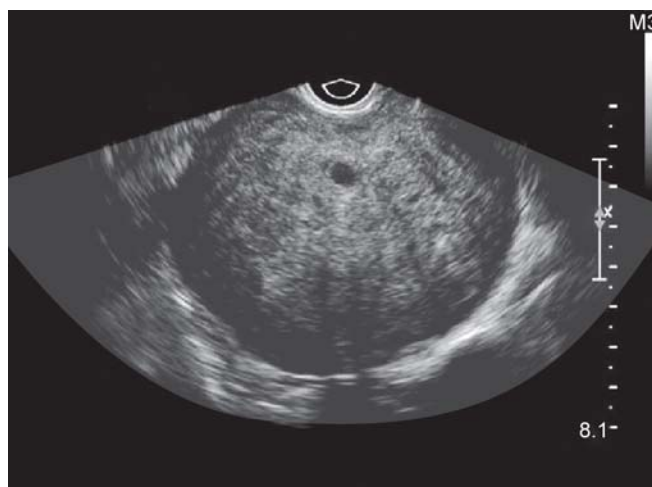

Fig. 1: Transvaginal ultrasound showing bulky uterus with myometrial cyst

POD was completely obliterated with dense bowel adhesions. Right ovary was normal. Left ovary was buried in POD. Final diagnosis was adenomyosis with stage IV endometriosis. Considering the wish for fertility, she was put on injection Lupron depot for 3 months and planned for IVF subsequently.

DISCUSSION

Adenomyosis usually presents as dysmenorrhea, menorrhagia and chronic pelvic pain in multiparous women in the fourth or fifth decade of life.

The diagnosis was traditionally histopathological with hysterectomy specimens. With availability of imaging modalities, more and more cases are being diagnosed with transvaginal ultrasound and color Doppler and magnetic resonance ultrasound.

Also, atypical presentations are coming to the fore. In this patient, the disease presented early at the age of 23 years. We could not find any similar report in the literature of early presentation of adenomyosis. Menorrhagia was the presenting complaint in this case. All other causes of excessive bleeding were ruled out.

McCauseland et al postulated that myometrial hypertrophy is caused by the ectopic endometrial glands.¹ This dysfunctional myometrium is inefficient in contracting and tamponading the bleeding myometrial arterioles. Brosens showed that widened junctional zone has reduction in peristalsis compared to normal menstruating subendometrial zone and results in the menorrhagia.²

In this case, the patient was referred as a case of fibroid uterus.

Transvaginal ultrasound has a sensitivity, specificity, positive and negative predictive values of 76.4, 92.8, 73.8 and 88.8% respectively, in the diagnosis of adenomyosis. Typical ultrasound features of adenomyosis differentiating it from fibroid uterus are described.³

The features that differentiate it from fibroid are echo texture which is not uniform, with poorly defined borders, minimal mass effect on the endometrium or the serosa relative to the size of the lesion, elliptical rather than globular shape, lack of edge shadowing; 'shaggy' or whorled appearance of the endometrium, small myometrial cysts or spaces scattered throughout the myometrium, echogenic

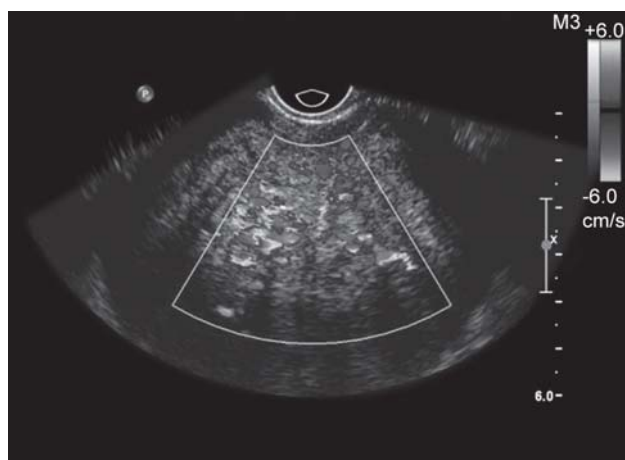


Fig. 2: Transvaginal color Doppler showing diffuse color flow

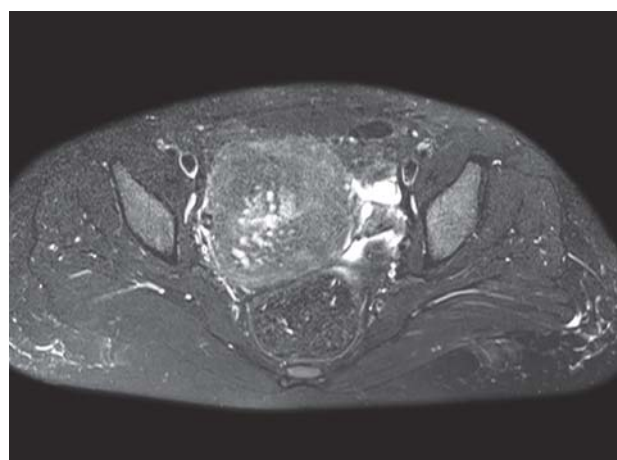


Fig. 4: MRI: T2 axial image showing symmetrically enlarged uterus with T2 bright areas suggestive of myometrial cysts

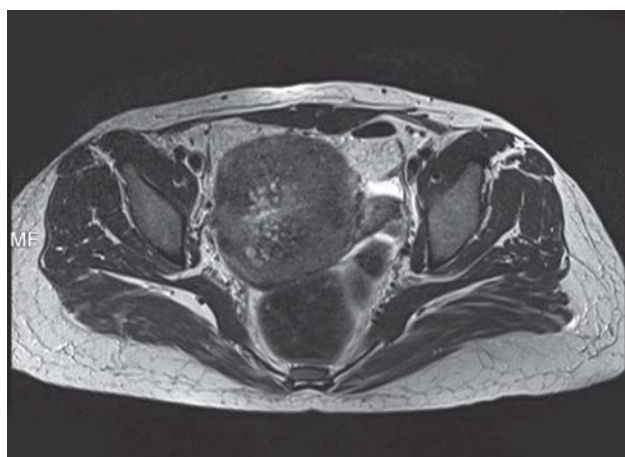

Fig. 3: MRI: T1 axial image showing bulky uterus with T1 bright areas suggestive of hemorrhage in the myometrium

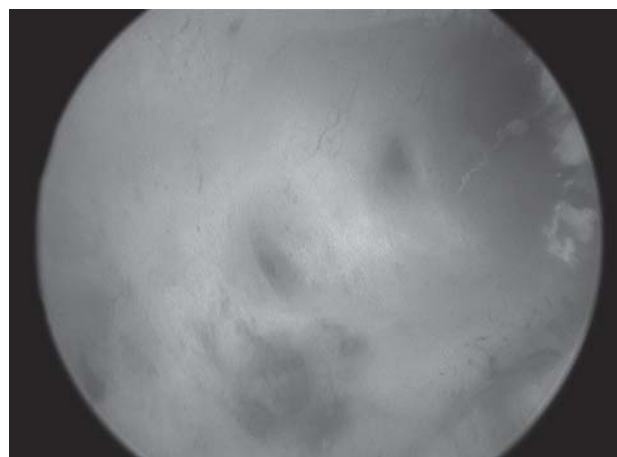

Fig. 5: Hysteroscopy showing defects at the fundus

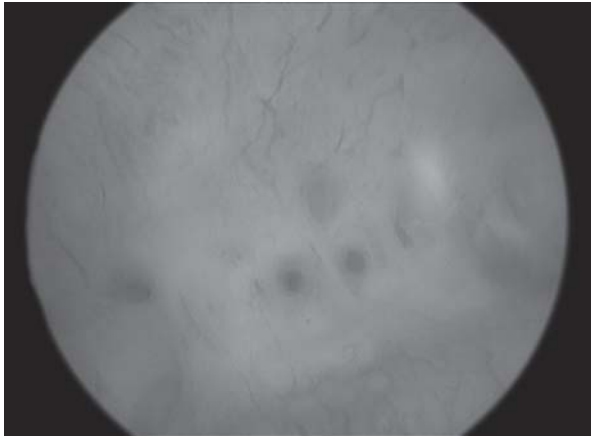


Fig. 6: Multiple circumscribed fundal lesions seen on hysteroscopy

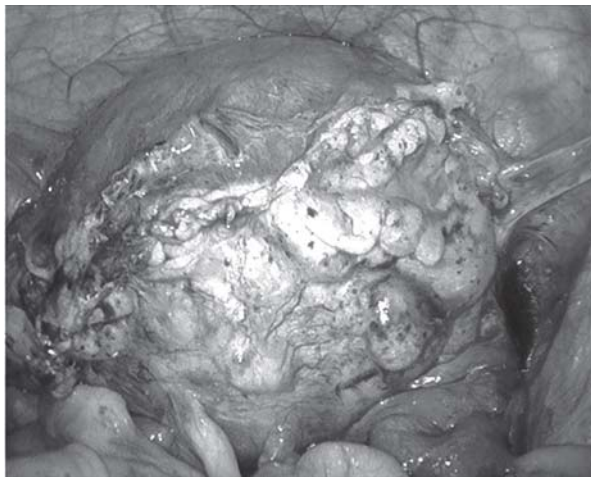


Fig. 7: Laparoscopy showing bulky uterus with omental adhesions

nodules or linear striations radiating out from the endometrium into the myometrium and the absence of circular vascularization at the border of the lesion. MRI is particularly amenable to diagnosis with an accuracy of almost 99%.⁴ Hysteroscopy has been demonstrated to be an important additional procedure for the evaluation of uterine pathology, even in the case of adenomyosis, because it offers the main advantage of direct visualization of the uterine cavity and the possibility of obtaining histological specimens under visual control.⁵

Campo et al described characteristic appearance of endometrial cavity on hysteroscopy, including abnormal endometrial vascularity, irregular endometrium with defects or small openings on the surface and cystic hemorrhagic lesions in the cavity.⁵ In this case, an appearance exactly similar to that described by Campo et al was observed on hysteroscopy showing endometrial defects in the fundal area.

While hysteroscopy alone cannot diagnose or rule out adenomyosis, the typical endometrial lesions associated with it can aid in the diagnosis when accompanied by a transvaginal ultrasound. This can enable clinicians to decide on taking an endomyometrial biopsy when the hysteroscopic picture is suggestive of adenomyosis.

An office hysteroscopy has emerged as one of the primary investigations in cases of abnormal uterine bleeding and infertility. If the diagnosis of adenomyosis is not kept in mind, the appearance of circular endometrial defects can be confused with intrauterine adhesions leading to unnecessary operative intervention. Such a picture has been reported only once but is probably under-reported due to low awareness among clinicians.

Awareness of the hysteroscopic picture can aid clinicians in clinching the diagnosis of adenomyosis early thereby tailoring the treatment according to the symptoms and conditions.

Recognition and research on the endometrial effects of adenomyosis will also help in elucidating the etiology of the negative impact adenomyosis has on implantation and pregnancy rates in IVF.⁶

ACKNOWLEDGMENT

We gratefully acknowledge the contribution of Dr Kailash Patel, Department of Radiodiagnosis and Imaging, for his help.

REFERENCES

1. McCauseland V, McCauseland A. The response of adenomyosis to endometrial ablation/resection. *Hum Reprod Update* 1998 June-Aug;4(4):350-359.
2. Brosen JJ. Diagnostic criteria for adenomyosis. *Gynecol Endosco* 1997;6:12.
3. Bazot M, Cortez A, Darai E, Rouger J, Chopier J, Antoine JM, et al. Ultrasonography compared with magnetic resonance imaging for the diagnosis of adenomyosis: Correlation with histopathology. *Hum Reprod* 2001;16(11):2427-2433.
4. Keckstein J. Hysteroscopy and adenomyosis. *Contrib Gynecol Obstet* 2000;20:41-50.
5. Molinas CR, Campo R. Office hysteroscopy and adenomyosis. *Best Pract Res Clin Obstet Gynaecol* 2006 Aug;20(4):557-567.
6. Tremellen K, Russell P. Adenomyosis is a potential cause of recurrent implantation failure during IVF treatment. *Aust NZJ Obst Gynaecol* 2011 June;51(3):280-283.

ABOUT THE AUTHORS

Priya Bhawe Chittawar (Corresponding Author)

Professor, Department of Reproductive Medicine, Sri Aurobindo Institute of Medical Sciences, Indore, Madhya Pradesh, India, e-mail: priyabhawe1@gmail.com

Shilpa Sapre

Associate Professor, Department of Obstetrics and Gynecology, Sri Aurobindo Institute of Medical Sciences, Indore, Madhya Pradesh, India

Shilpa Bhandari

Associate Professor, Department of Reproductive Medicine, Sri Aurobindo Institute of Medical Sciences, Indore, Madhya Pradesh, India

Unusual Presentation of Endometriosis

Hana Alhomoud

ABSTRACT

A rare case of endometriosis in an umbilical hernia is presented. The clinical course and management of the patient with a literature review of the unusual site of endometriosis is discussed.

Keywords: Endometriosis, Umbilical hernia, Extrapelvic endometriosis.

How to cite this article: Alhomoud H. Unusual Presentation of Endometriosis. *World J Laparosc Surg* 2013;6(2):105-106.

Source of support: Nil

Conflict of interest: None declared

INTRODUCTION

Endometriosis is a condition in which endometrial stroma and glands are found outside of the uterine cavity. It is found in 8 to 15% of all menstruating women.

The endometrial tissue is generally found within the pelvic cavity and involves the ovaries, uterine ligaments, fallopian tubes, pouch of Douglas or pelvic side wall.

Extrapelvic sites also have been reported, including the abdominal viscera, abdominal wall, extremities, lungs and brain.

However, endometriosis in the umbilical hernia is very rare site of occurrence of the disease and accounts for only 0.5 to 1% of all endometriosis cases.¹

CASE PRESENTATION

A 42 years old lady, referred to the clinic for repair of an umbilical hernia.

She has a history of umbilical hernia for the last 5 years, but for the last 5 months, there is a history of tender umbilical hernia that had increased in size gradually, pain and size of hernia increases in relation to her menstrual cycle.

Her only history of abdominal surgery was a cesarean section to deliver twins 5 years earlier, which had left a low transverse incision scar.

Physical examination revealed 5 × 5 cm, irreducible umbilical hernia with dark skin discoloration, no other masses were observed in the abdomen or by the low transverse scar.

Surgical exploration revealed an umbilical hernia. Part of the irreducible omentum was excised. The hernia defect was repaired, the surgical specimen was sent to pathology for evaluation.

Microscopic sections revealed, histological features consistent with umbilical endometriosis, endometrial glands

and stroma with surrounding fibrosis and hemorrhage are identified in the material Figs 1 and 2.

The patient was discharged home the next day of the procedure, recovered well from surgery.

DISCUSSION

There are a variety of theories regarding the cause of endometriosis. None have been proven, nor does any one theory explain all the different manifestations of the disease.²

The retrograde theory, which contends that endometrial tissue reflexes through the fallopian tubes during menstruation and implants at ectopic sites, would explain the high percentage of cases occurring in the pelvis.

The presence of remote, extrapelvic sites is better explained by the metaplasia theory, which suggests that

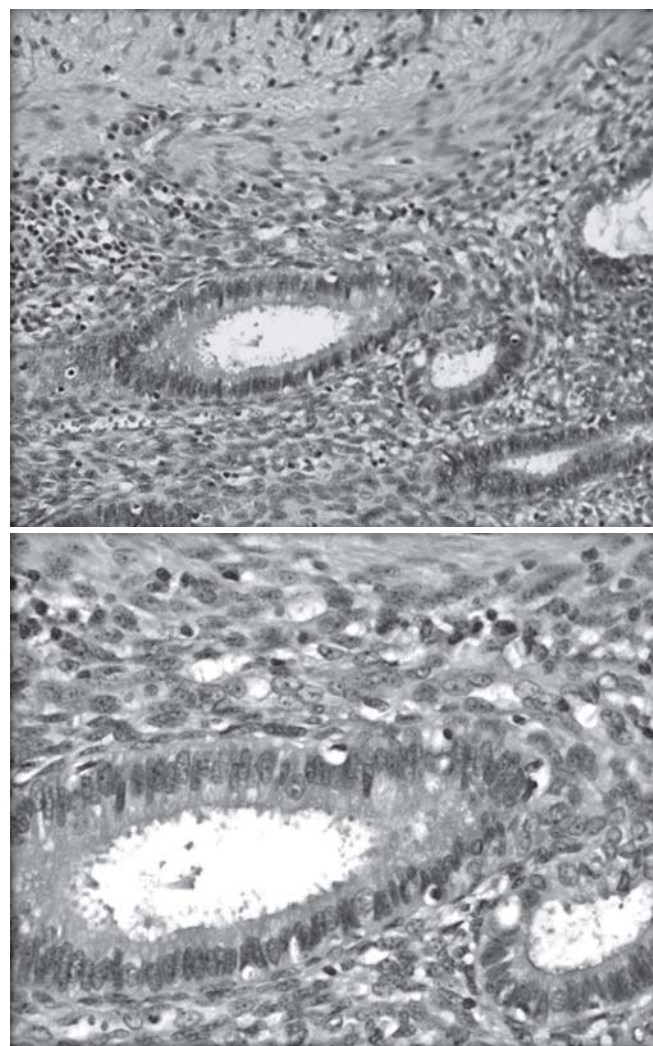


Fig. 1: Endometriosis by pathology

multipotential cells can develop into endometrial tissue, often stimulated by inflammation.

In 1994, Yu and associates described their experience with a 30-year-old woman who had an 18-month history of cyclic umbilical pain and bleeding. A $1.5 \times 1.5 \times 1.0$ cm lesion was found in the umbilical area, adjacent to a small umbilical hernia. Histological analysis of the lesion revealed endometriosis with chronic inflammation, hemosiderin and fibrosis.³

In 2000, Ramsanahie and associates reported a case of endometriosis in the scarless abdominal wall of a 33-year-old woman. She had a 2-year history of intermittent pain associated with an umbilical mass and underlying umbilical hernia. The mass increased in size and tenderness prior to menstruation. Physical examination revealed a 2×1 cm, firm, round, cherry red nodule at the umbilicus with an underlying umbilical hernia. Postoperative histological analysis showed endometriosis.⁴

In 2001, Yuen et al reported the case of 43-year-old woman who for several months had experienced umbilical pain that came on during her menses. She had a lower midline incision scar from a cesarean section that had been performed 9 years earlier. Physical examination revealed a tender, irreducible umbilical hernia with skin discoloration. Histological analysis showed a focus of endometrial tissue within the lower dermis.⁵

In 2007, Waxman et al reported a case of 29-year-old woman, presented with a 7-month history of tender umbilical mass; the initial impression was that she had an incarcerated hernia with possible bowel strangulation. Microscopic sections revealed an admixture of benign endometrial glands and stroma consistent with endometriosis.⁶

Between 0.5 and 1% of all endometriosis cases involve the umbilicus, endometriosis and umbilical hernia is not only rare, it can present as a diagnostic pitfall to the general surgeon.

Thus, it should be considered in the differential diagnosis of all premenopausal women presenting with umbilical swellings.

The diagnosis is often made incidentally by histological examination after surgical exploration and excision of the lesion.

The fact that up to 50% of these affected women may have concomitant pelvic endometriosis, further pre-operative diagnostic investigations, is advisable. MRI is recommended as the best investigation. This modality of imaging has been shown to be useful for delineating the size and location of extrapelvic endometriosis and in excluding intra-abdominal extension of the disease.

CONCLUSION

Extrapelvic endometriosis in the umbilical hernia sac is rare. This case highlights the importance of considering endometriosis in the differential diagnosis of any premenopausal woman who presents with umbilical swelling and pain, regardless of whether the pain correlates with her menses.

REFERENCES

1. Nirula R, Greaney GC. Incisional endometriosis; an under-appreciated diagnosis in general surgery. *Am Coll Surg* 2000 Apr;190(4):404-407.
2. Seydel AS, Sickel JZ, Warner ED, Sax HC. Extra-pelvic endometriosis: Diagnosis and treatment. *Am J Surg* 1996 Feb; 171(2):239-241.
3. Yu CY, Perez-Reyes M, Brown JJ, Borrello JA. MR appearance of umbilical endometriosis. *J Comput Assist Tomogr* 1994 Mar-Apr;18(2):269-271.
4. Ramsanahie A, Giri SK, Velusamy S, Nessim GT. Endometriosis in a scarless abdominal wall with underlying umbilical hernia. *Ir J Med Sci* 2000 Jan-Mar;169(1):67-68.
5. Yuen JS, Chow PK, Koong HN, Ho JM, Girija R. Unusual sites (thorax and umbilical hernia sac) of endometriosis. *JR Coll Surg Edinb* 2001;46(5):313-331.
6. Waxman KS. Umbilical hernia and endometriosis. A diagnostic consideration. *Surg Found* 2007 Aug;30(5):380-383.

ABOUT THE AUTHOR

Hana Alhomoud

Senior Registrar, Department of Surgery, Al-Sabah Hospital, Kuwait
e-mail: hana_alhomoud@hotmail.com

Laparoscopic Myomectomy for Large Fibroids with Synchronized use of Uterine Artery Embolization

MW Kamran, TK Madhuri, WJ Walker, SA Butler-Manuel

ABSTRACT

Objective: To determine the feasibility and efficacy of the laparoscopic myomectomy for large fibroids (>10 cm) with use of synchronous uterine artery embolization.

Design: A prospective observational case series of laparoscopic myomectomy performed for single and multiple uterine fibroids.

Setting: A tertiary referral center for gynecological oncology and minimal access surgery.

Population: A 15 premenopausal women with large fibroids who wished to conserve their uterus from March 2005 to August 2011.

Materials and methods: Laparoscopic myomectomy was performed using harmonic scalpel with synchronized pre-operative uterine artery embolization (UAE) following multidisciplinary team discussion. Tissue retrieval was performed by morcellation.

Main outcome measures: Early discharge and reduced intra-operative blood loss.

Results: Of all 15 cases, mean number of fibroids removed was 2 (range: 1-4) and mean mass of tissue excised was 450 gm (range: 320-1540). The mean diameter of the fibroids removed was 13 cm (range: 10-20 cm). Mean estimated blood loss was 156 ml (range: 25-1,000 ml) and the mean operating time was 113 minutes (17-200 minutes). All cases were successfully completed laparoscopically with no conversions to open surgery. One patient who had a 13 cm broad ligament fibroid required a 2 unit blood transfusion intraoperatively and another patient developed a single port-site infection 2 weeks following the procedure. Histology confirmed benign leiomyomas in all cases.

Conclusion: Laparoscopic myomectomy with use of synchronized UAE using harmonic scalpel is feasible and efficient procedure for single or multiple large fibroids within an experienced multidisciplinary setting.

Keywords: Large fibroids, Laparoscopic myomectomy, Uterine artery embolization.

How to cite this article: Kamran MW, Madhuri TK, Walker WJ, Butler-Manuel SA. Laparoscopic Myomectomy for Large Fibroids with Synchronized use of Uterine Artery Embolization. *World J Laparosc Surg* 2013;6(2):107-110.

Source of support: Nil

Conflict of interest: None declared

INTRODUCTION

Symptomatic uterine fibroids are a common problem, particularly for premenopausal women in their later reproductive years. They principally cause either heavy periods or pressure symptoms, especially on the bladder

and other abdominal viscera. Prevalence rates vary widely depending on the age and racial mix of the study population.

A diagnostic study in the UK identified uterine fibroids in 36% of premenopausal women with abnormal uterine bleeding.¹ According to hospital episode statistics, UK 10,559 hysterectomies were performed due to menorrhagia in 2002.² A patient preference study in the UK showed that approximately 85% women would consider a 50:50 chance of treatment failure to avoid a hysterectomy.³

The successful management of uterine fibroids should depend on the presenting symptoms, size, number and location of the fibroids. A successful outcome also depends on the patient's expectations and desire or otherwise to retain her uterus and fertility. However, the standard treatment performed for large fibroids in the UK and USA remains hysterectomy, the majority of which are performed by conventional abdominal open surgery. Open myomectomy is much less frequently performed and is also associated with significant morbidity, but myomectomy is the preferred choice for patients wishing to conserve their uterus.^{4,5}

Laparoscopic removal of fibroids has been shown to be possible since the early 1990s but has not been widely adopted, especially for large fibroids, presumably due to limitations in surgical expertise and training required.^{6,7} Laparoscopic myomectomy has the great advantages of short hospital stay, reduced analgesic requirement, rapid recovery to normal activity, reduced risk of adhesions, and almost immediate symptomatic benefit. Laparoscopic myomectomy is restricted by the size and the location of the fibroids. Large fibroids limit the amount of space available within which to manipulate the uterus and laparoscopic instruments.⁸

Multiple smaller intramural or interstitial fibroids may be best treated by nonsurgical means, such as UAE alone with very good symptomatic and pregnancy outcomes.⁹ Not all patients are suitable for UAE however, including those with pedunculated fibroids, while others find the prospect of fast recovery and minimal discomfort of laparoscopic surgery appealing.

MATERIALS AND METHODS

Design and Setting

The study population includes 15 otherwise healthy non-pregnant premenopausal women with symptomatic large

fibroids undergoing laparoscopic myomectomy within a tertiary referral center for gynecological oncology and minimal access surgery. The data was collected from March 2005 to August 2011. The decision to undertake laparoscopic myomectomy combined with preoperative uterine artery embolization (UAE) was jointly taken in 15 cases of anticipated heavy intraoperative blood loss following multidisciplinary review with interventional radiology and gynecological oncology input. This approach was adopted to gain the maximum knowledge about the size, number and characteristics of abdominopelvis mass. Particular emphasis was placed on excluding any features suggestive of malignancy, such as atypical appearance of mass, retroperitoneal disease or associated ovarian pathology. Therefore, the patient exclusion criteria for the combined procedure included small uterine mass of less than 10 cm, calcification, single pedunculated lesion, clinical and or radiological features suggestive of malignancy.

INVESTIGATIONS

All patients had preoperative full blood count, blood grouping and serum saved. All cases were assessed pre-operatively with ultrasound as well as MRI abdomen and pelvis scans to estimate the size, number, location and characteristics of fibroids (Figs 1 and 2). No preoperative hormonal therapy was used and surgery was not timed with any particular point in the menstrual cycle.

INTERVENTIONS

All patients were counselled appropriately in outpatient department by two specialists involved in providing care regarding the procedure and associated risks including premature ovarian failure, prospects of future pregnancy and failure of the procedure requiring further in future.

The patients were admitted on the day of surgery and remained for one night postoperatively. The selective uterine artery embolization was carried out by a single interventional radiologist through the groin approach using local anesthesia and intravenous sedation on the day of the operation in the interventional vascular suite following pelvic angiogram. Unilateral or bilateral uterine artery embolization was undertaken with 355 to 500 micron polyvinyl alcohol (PVA) particles and coils based on the angiogram.

These patients were then observed on the ward prior to surgery. All laparoscopies were undertaken by a single gynecological surgeon. Palmer's point entry in the left upper quadrant was preferred using a 5 mm laparoscope as the fibroid masses often extended close to or above the umbilicus. A second 5 mm port was inserted in the left lower quadrant, and one 12 mm port inserted through the umbilicus. This was then later exchanged for the morcellator

following excision of the fibroids. A third 5 mm port was used in 4 cases to aid with the dissection.

Following insertion of all ports and setup, confirmation was made that the planned procedure was feasible before proceeding further with the dissection. Dissection of the fibroid(s) was then performed, followed by repair of any uterine defect with a layered closure using 2/0 absorbable braided monofilament sutures using intracorporeal knot tying. In all cases harmonic scalpel was used for the uterine and other tissue dissection. Bipolar forceps were available for additional hemostasis for larger vessels. Tissue extraction was performed by laparoscopic morcellation. The blood loss was measured by volume collected in the suction apparatus. A final check laparoscopy and lavage was performed, with infiltration of local anesthesia, prior to closure of the ports.

RESULTS

The mean age of myomectomy in our population was 37 years (31-49). All 15 cases had synchronized uterine artery embolization on the day prior to the laparoscopic myomectomy. In total 34 fibroids were excised and the mean number of fibroids removed was 2. Of all those, there were 22 fundal, 8 anterior or posterior uterine wall, 2 lateral uterine wall/broad ligament and 2 cervical leiomyomas. 26 fibroids were intramural and 8 subserosal (including 2 cervical fibroids). The mean weight of the excised fibroid tissue was 450 gm (350-1,540 gm). The mean fibroid size in largest dimension was 13 cm (10-20 cm). The mean estimated blood loss measured in suction was 156 ml and the mean operating time was 113 minutes (65-200 minutes). One patient who had broad ligament fibroid received a 2 unit blood transfusion postoperatively due to an estimated intraoperative blood loss of 1 liter from the aberrant blood vessels in the broad ligament. The blood transfusion was

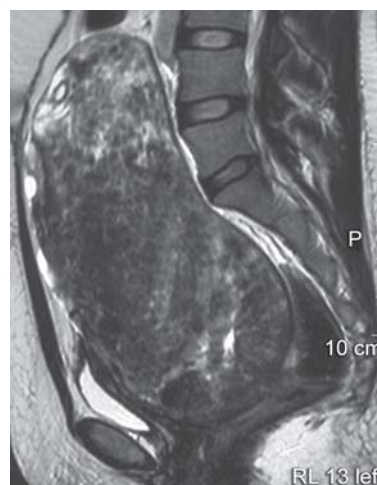


Fig. 1: MRI sagittal view showing large fibroid uterus

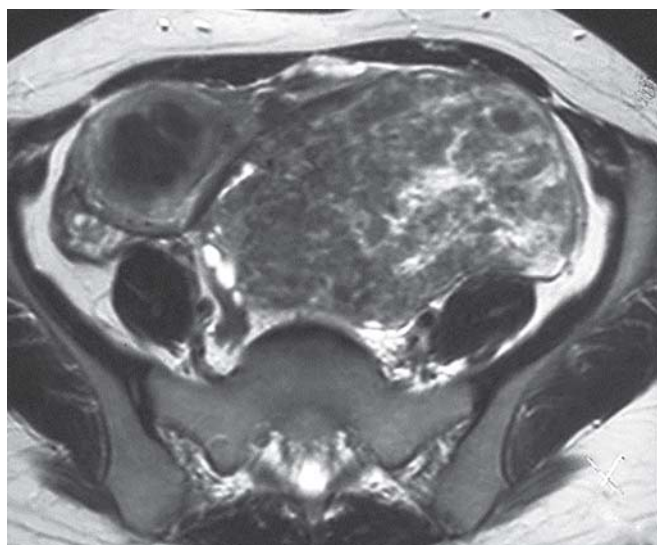

Fig. 2: MRI pelvis showing fibroid

given due to the clinical symptoms and a drop in post-operative hemoglobin (Hb) by 2.1 gm/dl (preop Hb 9.4 gm/dl). Another patient had single port site infection, which required a course of oral antibiotic treatment. All patients were discharged home within 24 hours after an overnight stay. Tissue specimen histology confirmed leiomyomas in all cases. One patient subsequently delivered a healthy infant at 37 weeks gestation by an elective cesarean section. None of these women have undergone subsequent hysterectomy or further treatment for their fibroids. All cases were successfully completed laparoscopically without conversion to open surgery.

DISCUSSION

Size and intractable intraoperative bleeding has been cited in previous published series as a common reason for conversion from a laparoscopic approach to laparotomy in 41.4% cases¹⁰ or even hysterectomy¹¹ but that has not been our experience. An upper limit of size for laparoscopic myomectomy has been suggested at 10 cm to minimize blood loss.¹² Numerous preoperative and intraoperative chemical and mechanical interventions have been described to reduce the intraoperative blood loss during uterine myomectomy.^{6,13} These include the preoperative use of gonadotropin releasing hormone (GnRH) analogues, injection of vasopressin or other vasoconstrictive agents under the capsule of the fibroid, or the application of mechanical clips or tourniquets around the uterine vessels. All of these strategies have some merit. Use of vasopressin has been shown to reduce blood loss¹⁴ as have the use of either temporary or permanent laparoscopic clips.^{15,16} However, the application of clips on uterine vessels becomes more difficult, the larger the fibroid mass due to the restricted operating space available.

We have adopted a simple reproducible technique of myomectomy with no special pre- or peroperative measures, but with use of UAE in selected cases following multidisciplinary discussion and review of imaging. The use of preoperative UAE followed by laparoscopic myomectomy has proved to be a reliable method to help reduce intraoperative blood loss and also to treat multiple smaller intramural or interstitial fibroids simultaneously with surgical removal of the largest of the masses. This approach has enabled the most complex of cases to be managed laparoscopically without fear of intractable hemorrhage.^{17,18} Preoperative UAE makes uterine surgery simpler due to the bloodless field and does not increase the complication rate.¹⁹

Recent studies have suggested that UAE alone may not provide effective symptomatic relief in nearly 1 in 4 women and hence patients may need further intervention over time²⁰ and that nearly 30% patients with previous UAE may require a hysterectomy due to insufficient symptomatic improvement.²¹

The best symptomatic outcomes may be achieved by combining UAE with synchronized myomectomy which ideally should be undertaken laparoscopically to give patients the considerable benefits of endoscopic surgery. The advent of robotic surgery may well make such minimal access surgery more widely available to women with symptomatic fibroids, as it makes suturing of the uterine defect easier to perform than with 'conventional' laparoscopic surgery.

In all of these cases disposable morcellators were used. Tissue morcellation remains the most time-consuming part of laparoscopic myomectomy for large fibroids, and further improvements in mechanical tissue morcellation would further enhance these procedures and reduce operating time.

CONCLUSION

We have successfully demonstrated the feasibility and efficacy of laparoscopic myomectomy for large fibroids of diameter up to 20 cm using harmonic scalpel combined with preoperative UAE. The size of fibroids should not necessarily be the limiting factor to performing myomectomy laparoscopically. Laparoscopic myomectomy for large fibroids should be undertaken with multidisciplinary team approach in centers with particular expertise in both minimal access surgery and interventional radiology.

REFERENCES

1. Critchley HO, Warner P, Lee AJ, Beechin S, Guise J, Graham B. Evaluation of abnormal uterine bleeding: Comparison of three outpatient procedures within cohorts defined by age and menopausal status. *Health Technol Assess* 2001 Sep;8(34): 1-139.

2. National institute of clinical excellence (NICE) guideline, UK. CG44 Heavy Menstrual Bleeding 2007 Jan.
3. Nagele F, Rubinger T, Magos A. Why do women choose endometrial ablation rather than hysterectomy? *Fertil Steril* 1998 Jun;69(6):1063-1066.
4. Mukherjee SN. Role of hysterectomy and its alternatives in benign uterine diseases. *J Indian Med Assoc* 2008 Apr;106(4):232-234.
5. Mukhopadhyaya N, De Silva C, Manyonda IT. Conventional myomectomy. *Best Pract Res Clin Obstet Gynaecol* 2008 Aug;22(4):677-705.
6. Nezhat C, Nezhat F, Silfen S, Schaffer N, Evans D. Laparoscopic myomectomy. *Int J Fertil* 1991 Sep-Oct;36:275-280.
7. Dubuisson JB, Chapron C, Verspyck E. Laparoscopic myomectomy 102 cases. *Contracept Fertil Sex* 1993;21:920-922.
8. Madhuri T, Kamran W, Walker W, Butler-Manuel S. Synchronous uterine artery embolization and laparoscopic myomectomy for massive uterine leiomyomas. *JSLs* 2010;14:120-122.
9. Walker WJ, Barton-Smith P. Long-term follow-up of uterine artery embolisation—an effective alternative in the treatment of fibroids. *BJOG* 2006;113:464-468.
10. Darai E, Deval B, Darles C, Benifla L, Guglielmina JN. Laparoscopy or laparotomy. *Contracept Fertil Sex* 1996;24(10):751-756.
11. Sizzi O, Rossetti A, Malzoni M, Minelli L, Labrotta F, Soranno L, Panunzi S. Italian multicenter study on complication of laparoscopic myomectomy. *J Minim Invasive Gynecol* 2007 Jul-Aug;14(4):453-462.
12. Takeuchi H, Kuwatsuru R. The indications, surgical techniques, and limitations of laparoscopic myomectomy. *JSLs* 2003;7:89-95.
13. Kongnyuy EJ, Wiysonge CS. Interventions to reduce haemorrhage during myomectomy for fibroids. *Cochrane Database Syst Rev* 2011 Nov 9;11:CD005355.
14. Frederick J, Fletcher H, Simeon D, Mullings S, Hardie M. Intramyometrial vasopressin as a haemostatic agent during myomectomy. *BJOG* 1994 May;101(5):435-437.
15. Rosen DM, Hamani Y, Cario GM, Chou D. Uterine perfusion following laparoscopic clipping of uterine arteries at myomectomy. *Aust N Z J Obstet Gynaecol* 2009 Oct;49(5):559-560.
16. Wang CJ, Yuen LT, Han CM, Kay N, Lee CL, Soong YK. A transient blocking uterine perfusion procedure to decrease operative blood loss in laparoscopic myomectomy. *Chang Gung Med J* 2008 Sep-Dec;31(5):463-468.
17. Kuzel D, Mára M, Masková J, Fucikova Z, Kitz P, Dundr P, Zivny J. Combined treatment of uterine myoma (uterine arteries embolization followed by laparoscopic myomectomy). *Ceska Gynkol* 2004 Nov;69(6):497-500.
18. Tixier H, Loffroy R, Filipuzzi L, Grevoul J, Mutamba W, Cercueil J, Krause D. Uterine artery embolization with resorbable material prior to myomectomy. *J Radiol* 2008 Dec;89(12):1925-1929.
19. Dumoussset E, Chabrot P, Rabischong B, Mazet N, Nasser S, Darcha C, Garcier JM. Preoperative uterine artery embolization (PUAE) before uterine fibroid myomectomy. *Cardiovasc Intervent Radiol* 2008 May-June;31(3):514-520.
20. Hirst A, Dutton S, Wu O, Briggs A, Edwards C, Waldenmaier L, Maresh H. A multi-centre retrospective cohort study comparing the efficacy, safety and cost-effectiveness of hysterectomy and uterine artery embolisation for the treatment of symptomatic uterine fibroids. The hopeful study. *Health Technol Assess* 2008 Mar;12(5):1-248.
21. Van der Kooij SM, Hehenkamp WJ, Volkers NA. Uterine artery embolization vs hysterectomy in the treatment of symptomatic uterine fibroids: 5-year outcome from the randomized EMMY trial. *Am J Obstet Gynecol* 2010 Aug;203(2):105.

ABOUT THE AUTHORS

MW Kamran

Specialist Registrar, Department of Gynecological Oncology, Royal Surrey County Hospital, Surrey, UK

Correspondence Address: Postgraduate Medical School, University of Surrey, Daphne Jackson Road, Manor Park, Guildford, GU27WG UK, e-mail: waseemkamran@dubgyn.org

TK Madhuri

Royal Surrey County Hospital and Postgraduate Medical School University of Surrey, Surrey, UK

WJ Walker

Royal Surrey County Hospital and Postgraduate Medical School University of Surrey, Surrey, UK

SA Butler-Manuel

Royal Surrey County Hospital and Postgraduate Medical School University of Surrey, Surrey, UK