



# World Journal of Laparoscopic Surgery

*An Official Publication of the World Association of Laparoscopic Surgeons, UK*

*Editors-in-Chief*

**RK Mishra (India)**

**Jiri PJ Fronek (UK)**



**WJOLS**

Also available online at  
[www.jaypeejournals.com](http://www.jaypeejournals.com)  
[www.wjols.com](http://www.wjols.com)

Access Online Resources



For more details, visit  
[www.wjols.com](http://www.wjols.com)

*Bibliographic Listings:*

ProQuest, Scopus, Journals Factor,  
EBSCO, Genamics JournalSeek, Emcare, HINARI, Embase,  
J Gate, Google Scholar, Ulrich, CiteFactor, SIS,  
OAJI, MIAR, SIF, COSMOS, ESJI, SJIF, SJR, IJIF, ICI



**JAYPEE** Jaypee Journals

# Technical Modifications in Laparoscopic Appendectomy

Ali Aminian, Faramarz Karimian, Karamollah Toolabi, Rasoul Mirsharifi

Department of General Surgery, Imam Khomeini Hospital Complex, Tehran University of Medical Sciences, Tehran, Iran

## ABSTRACT

The technique of laparoscopic appendectomy has been modified several times in the past 20 years. In this report, we have described our modifications regarding the position of ports placement and closure of the base of appendix. Three surgeons successfully performed laparoscopic appendectomy in 108 cases with these modifications during the 3-year period. The first 10 mm port is placed in the periumbilical region. The second 10 mm and third 5 mm ports are inserted in the left and right side of abdomen below the pubic hairline respectively. Then the telescope is transferred from the periumbilical to the left suprapubic port. This mode of access leads to optimal ergonomics and cosmesis. For securing the base of appendix, only one Hem-o-lok clip (nonabsorbable polymer clip) is applied on each side. The use of Hem-o-lok clip is simple, safe and decreases the time and cost of laparoscopic appendectomy.

**Keywords:** Appendicitis, Laparoscopic appendectomy, Hem-o-lok clip, Polymer clip.

## INTRODUCTION

Since the first introduction of laparoscopic appendectomy by Semm in 1987, this procedure has been modified several times.<sup>1,2</sup> Two important issues in this procedure are mode of port placement and control of appendiceal stump.

Laparoscopic appendectomy is usually done through three ports. In some circumstances, one or two puncture techniques have been performed, and occasionally the fourth port became necessary. In standard technique, the telescope is inserted through periumbilical port. Then a 10 mm port is placed in left lower quadrant and a 5 mm port is placed in right lower quadrant. This configuration of port insertion has two drawbacks with respect to cosmesis and ergonomics. First, the cosmetic result is not ideal. The other disadvantage is that it requires the operating surgeon to stand in an ergonomically unfavorable position with one arm crossed over the patient's body.<sup>3,4</sup>

The standard technique for securing the base of the appendix is by double endoloop ligatures. However, application of endoloop requires dexterity and training. Another technique is application of endoscopic staplers. But this is a more expensive method for closure of the stump of the appendix, which is particularly important in developing countries.<sup>5,6</sup>

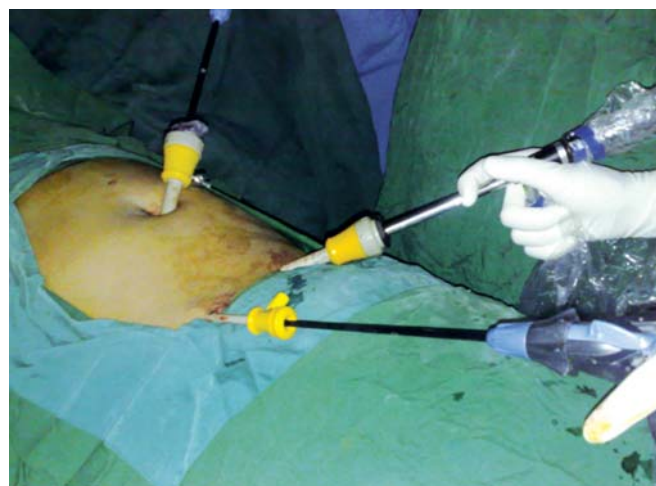In this report, we described our technique regarding configuration of ports and control of base of appendix during laparoscopic appendectomy.

## OPERATIVE TECHNIQUE

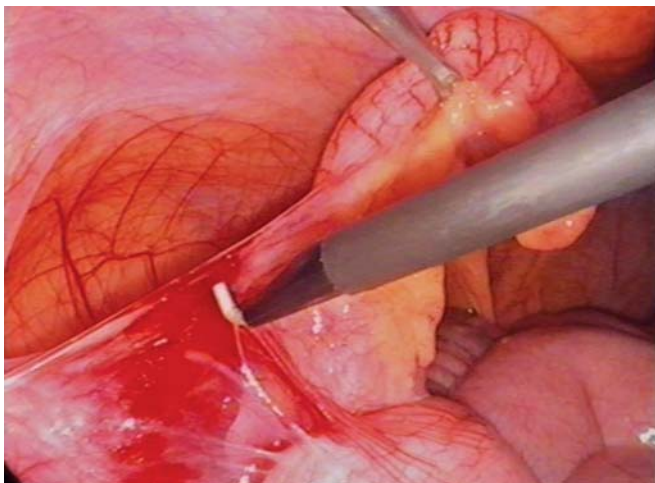
We have modified the position of ports placement and closure of base of appendix. Three surgeons performed laparoscopic appendectomy in 108 cases with these modifications during the past 3 years.

The first 10 mm port is placed in periumbilical region. Introducing telescope and careful transillumination of skin enables to find a suitable position of two other ports. The second 10 mm and third 5 mm ports are inserted in the left and right side of abdomen below the pubic hairline respectively (Fig. 1). Then we transfer the telescope from the periumbilical to the left suprapubic port. Ergonomically, this technique with the optical axis lying between the two working axes with wide manipulation angle is optimal for laparoscopic surgery (Fig. 2). Additionally, the elevation angle of the working instrument traversing the umbilical region (which is at a higher level than the suprapubic region in an inflated abdomen) is suitable (see Fig. 1).<sup>4</sup>

For securing the base of appendix and ligation of mesoappendix, Hem-o-lok clip (Weck Closure Systems, Research Triangle Park, NC, USA) is applied (Figs 3A to E).



**Fig. 1:** Ports position for laparoscopic appendectomy: Two ports in suprapubic region and reinserion of laparoscope through left suprapubic port

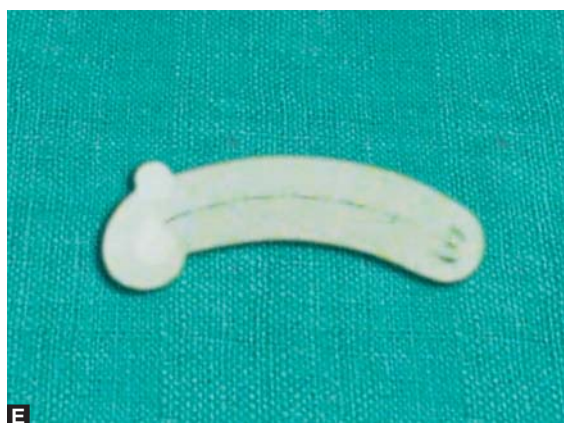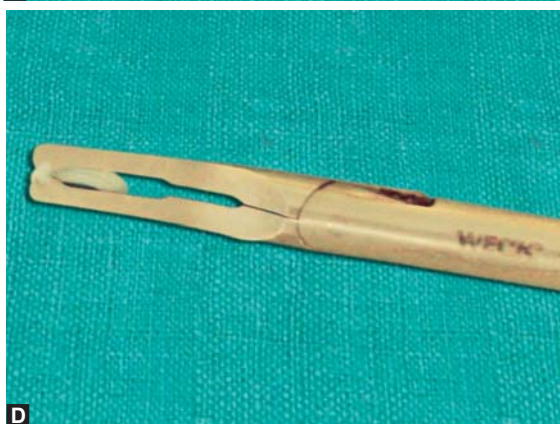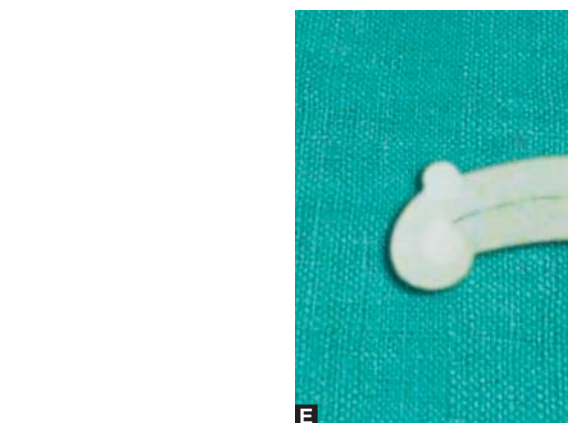
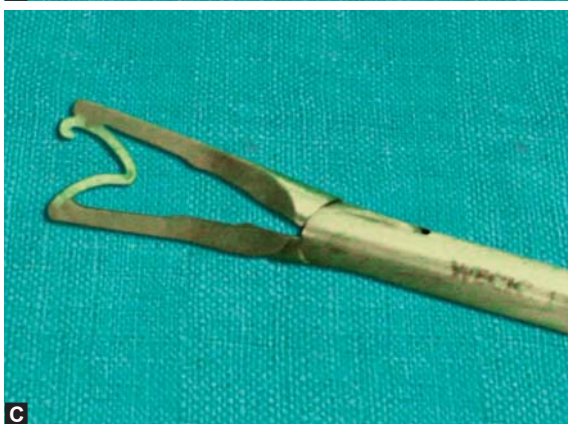
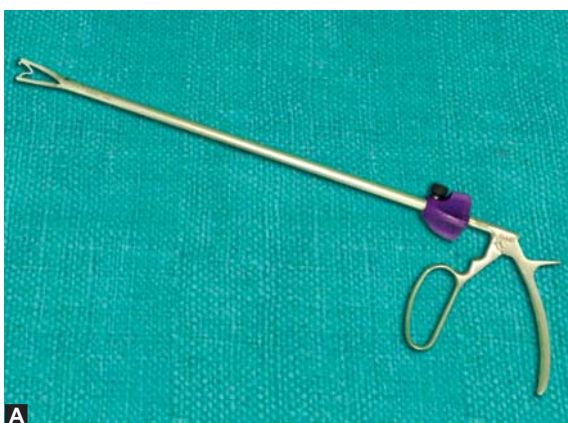


**Fig. 2:** Optimal working space: Optical axis lying between the two working instruments with wide manipulation angel

Application of the clips at the base of appendix is done by a special applier for the Hem-o-lok clip (Fig. 3A). Only one Hem-o-lok clip, size L or XL is placed at 90° to the base of the appendix on the proximal part and one on the distal part which would be removed (Figs 4A to F). We did not encounter any complications related to the use of Hem-o-lok clips, such as bleeding or leakage from appendiceal stump.

## DISCUSSION

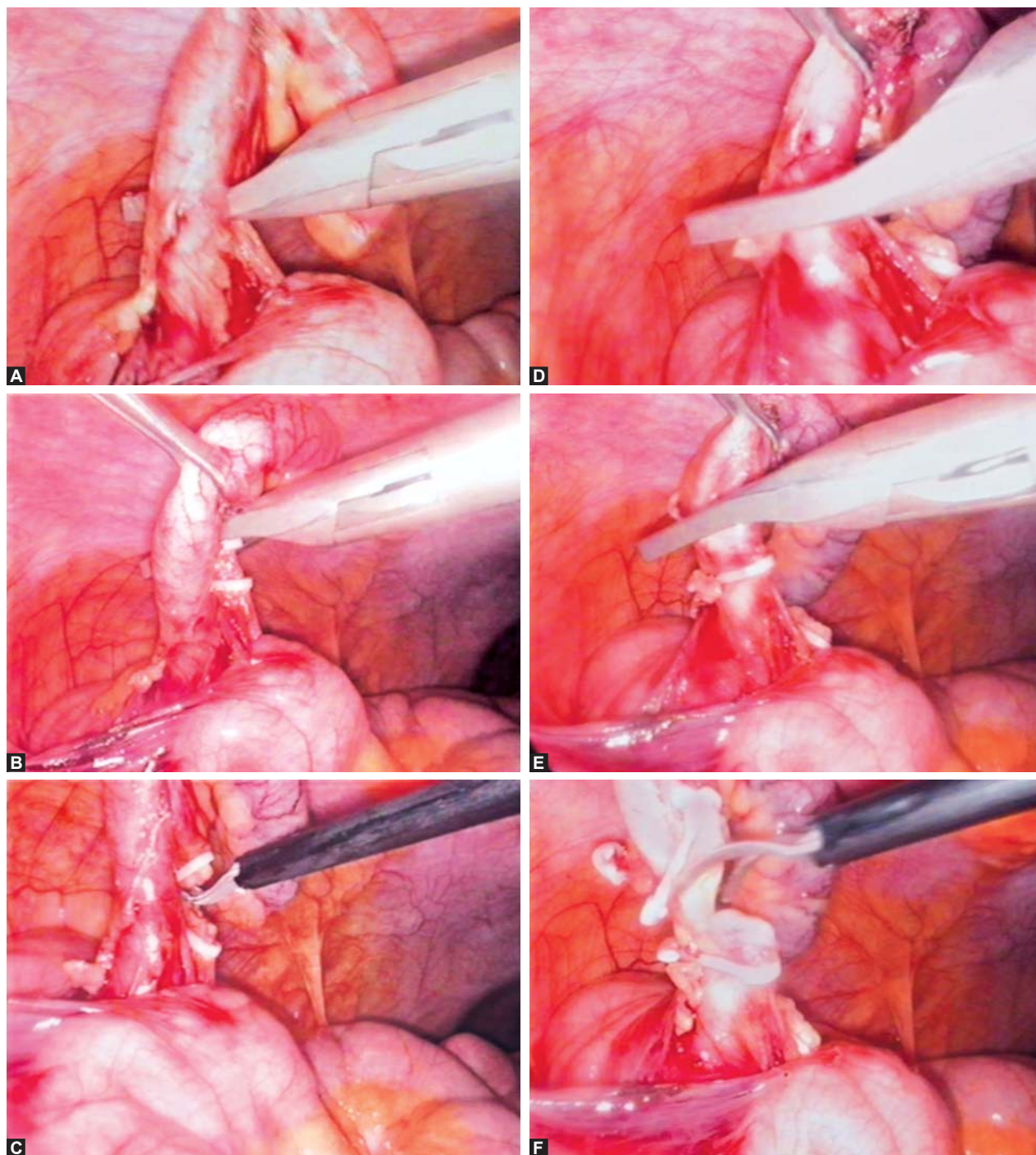
In practice, this mode of port placement offers several benefits. Two ports can be inserted below the pubic hairline with no visible scars. This modification not only improves the cosmetic result but also provides optimal ergonomics. First, the telescope, pointing upward and to the right, affords much better visualization of the base of appendix (see Fig. 2).



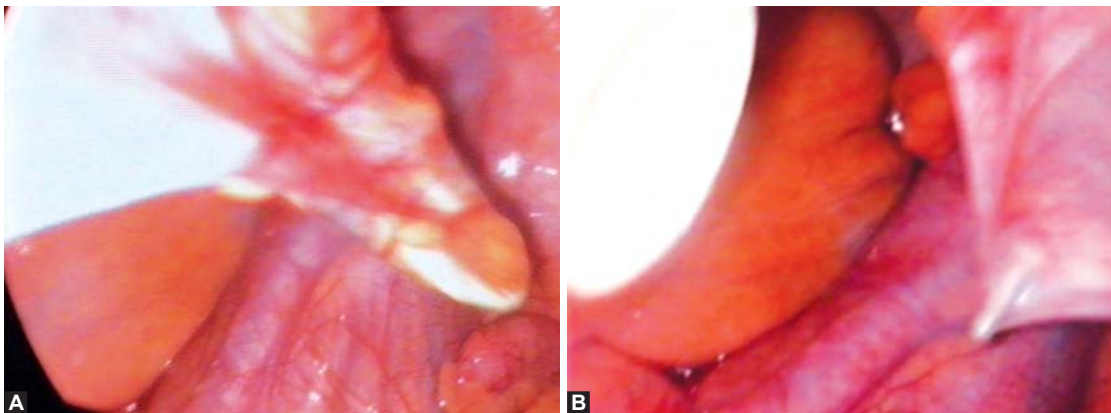
**Figs 3A to E:** Hem-o-lok clips and applier

In comparison, the visibility of a periumbilical telescope is less desirable as it might be impaired by a distended cecum. Second, with the tip of appendix retracted upward by the left hand grasper, the mesoappendix would assume a favorable position for dissection by a dissector inserted through the periumbilical port (see Fig. 2). Third, an instrument in this position carries less risk of electrocoagulation injury to the sigmoid loop compared to when it is inserted through the left lower quadrant port. Therefore, this configuration provides good and safe surgical

exposure for laparoscopic appendectomy.<sup>4</sup> However, there are some important technical points during trocar insertion in the suprapubic region. Selection of suitable position with careful transillumination is necessary to prevent bleeding from abdominal wall vessels. Insertion of trocars in this place can be slightly difficult because the suprapubic peritoneum is flexible and typically results in tenting of the peritoneum before the trocar tip penetrates into the abdominal cavity (Figs 5A and B). Routine use of Foley catheter prevents urinary bladder injury.<sup>3</sup>



**Figs 4A to F:** Closure of the mesoappendix (A-C) and base of appendix (D-F) with one hem-o-lok clip on patient side and one on specimen side



**Figs 5A and B:** Tenting of peritoneum during insertion of left 10 mm (A) and right 5 mm (B) suprapubic ports  
(A: Inflamed appendix in right inferior corner)

We have good experience with application of Hem-o-lok clip for securing the stump of appendix. The successful uses of Hem-o-lok clips, which are nonabsorbable polymer clips, have been shown in different procedures.<sup>5-7</sup> Design of its applier markedly decreases the chance of possible fall out of the clip (Fig. 3), and operative time is shorter in relation to application of the endoloop. The cost of Hem-o-lok clips is lower than endoscopic staplers and endoloop ligatures.<sup>5</sup> Moreover, its application is easy. Some technical points must be considered during the application of Hem-o-lok clip. Because of the locking mechanism, it is very important that the clip fits tightly around the base of the appendix prior to closure of the locking mechanism, as slipping off the base of the appendix may result in incomplete security. Every Hem-o-lok clip must be applied at 90° to the base of the appendix, which was shown to be important during the application of this clip on the vessel.<sup>5,7</sup>

## CONCLUSION

According to our experiences and previous reports,<sup>3-6</sup> the better ergonomics and cosmetic results are advantages of placement of two ports in suprapubic area and transferring the laparoscope to the left suprapubic port in comparison to standard port position. The feasibility of application, shorter time of operation and lower cost of Hem-o-lok clips are advantages of this technique for ligation of appendiceal stump in comparison to the standard endoloop ligature.

## ACKNOWLEDGMENTS

We would like to thank the staff of the operating room (number one) of Imam Khomeini Hospital, Tehran, Iran, for their cooperation.

## REFERENCES

1. Litynski GS. Kurt Semm and the fight against skepticism: Endoscopic hemostasis, laparoscopic appendectomy, and Semm's impact on the "laparoscopic revolution". *JLS* 1998;2:309-13.
2. Nicholson T, Tiruchelvam V. Comparison of laparoscopic-assisted appendectomy with intracorporeal laparoscopic appendectomy and open appendectomy. *JLS* 2001;5: 47-51.
3. Kollmar O, Z'graggen K, Schilling MK, Buchholz BM, Büchler MW. The suprapubic approach for laparoscopic appendectomy. *Surg Endosc* 2002;16:504-08.
4. Ng WT, Sze SY, Hui SK. Port placement for laparoscopic appendectomy with the best cosmesis and ergonomics. *Surg Endosc* 2003;17:166-67.
5. Delibegović S, Matović E. Hem-o-lok plastic clips in securing of the base of the appendix during laparoscopic appendectomy. *Surg Endosc* May 14, 2009.
6. Hanssen A, Plotnikov S, Dubois R. Laparoscopic appendectomy using a polymeric clip to close the appendicular stump. *JLS* 2007;11:59-62.
7. Simforoosh N, Aminsharifi A, Zand S, Javaherforooshzadeh A. How to improve the safety of polymer clips for vascular control during laparoscopic donor nephrectomy. *J Endourol* 2007;21: 1319-22.

# Stump Appendicitis: A Bane or Boon of Laparoscopic Appendectomy

<sup>1</sup>Sreeramulu PN, <sup>2</sup>Nikhil S Shetty, <sup>3</sup>Mahesh Babu B, <sup>2</sup>Asadulla Baig, <sup>2</sup>Supreeth CS

<sup>1</sup>Professor, Department of General Surgery, Sri Devaraj Urs Medical College, Kolar, Karnataka, India

<sup>2</sup>Resident, Department of General Surgery, Sri Devaraj Urs Medical College, Kolar, Karnataka, India

<sup>3</sup>Assistant Professor, Department of General Surgery, Sri Devaraj Urs Medical College, Kolar, Karnataka, India

## ABSTRACT

Appendiceal stump appendicitis is a very rare surgical event, though acute appendicitis is still the most common cause of abdominal surgeries worldwide. The incidence of appendiceal stump appendicitis is on a gradual rise possibly due to laparoscopic surgeries. In this study, we report a 54-year-old woman with preoperatively diagnosed stump appendicitis by ultrasound who underwent a laparoscopic appendectomy 8 years ago.

**Keywords:** Appendiceal stump appendicitis, Laparoscopic appendectomy.

## INTRODUCTION

Acute appendicitis is still the most common cause of abdominal surgeries worldwide. Even though the clinical features of stump appendicitis do not differ from those of acute appendicitis, the diagnosis is often not considered due to prior surgical history.

This paper reports a patient with preoperatively diagnosed stump appendicitis by ultrasound who had undergone a laparoscopic appendectomy 8 years ago.

## CASE REPORT

A 54-year-old woman was admitted with diffuse abdominal pain, nausea and vomiting since 2 days. There was no relevant medical history except a laparoscopic appendectomy performed 8 years ago. On physical examination, she had temperature of 39°C (axillary), blood pressure 110/70 mm Hg and pulse rate of 100/minute. Her abdomen was tender and there was a rebound tenderness and guarding in right iliac fossa.

Routine laboratory tests, such as total count was 15,500 with majority of polymorphonuclear leukocytes (PMN) (73%).

Examination of previous operation records confirmed laparoscopic removal of suppurative appendicitis. Abdominal ultrasound revealed small amount of fluid in right iliac fossa and increased thickness (8 mm) of the residual cecal appendix. A preoperative diagnosis of stump appendicitis was made.

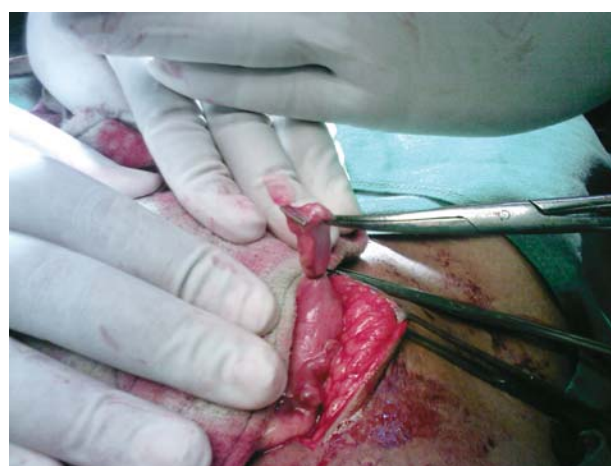Patient was posted for laparotomy procedure. Per-operative findings were cecal edema, and multiple adhesions between omentum and cecum. Further exploration revealed inflamed remnant appendiceal stump measuring around 4 cm (Figs 1 and 2). Stump appendectomy was done.

Abdomen was closed in layers. Histopathological examination confirmed stump appendicitis.

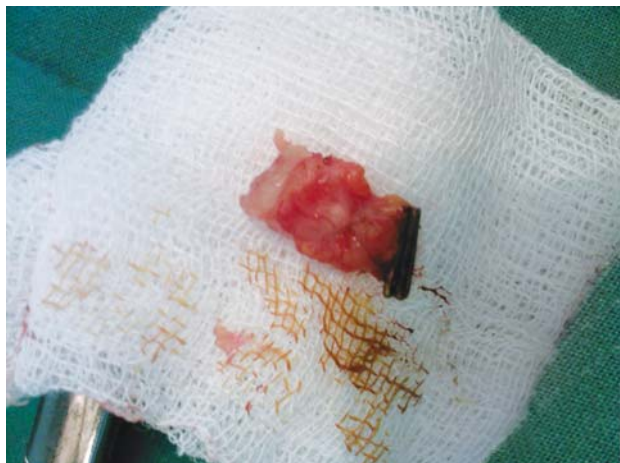## DISCUSSION

Stump appendicitis is a rare clinicopathological entity characterized by inflammation of appendiceal remnant after incomplete appendectomy. This clinical condition should be considered in differential diagnosis of acute abdominal pain and surgery should not be delayed.

Following the first case reported by Rose in 1945, around 36 cases have been reported in worldwide medical literature. Majority of the patients fall within 11 to 72 years. Clinical presentation of stump appendicitis may be acute or subacute and can occur as early as 2 months to 50 years after initial appendectomy. Appendiceal stump lengths are reported to range from 0.5 to 5.1 cm. Leaving a stump less than 3 mm long in the original surgery may prevent stump appendicitis. In our case, the length of the appendiceal stump



**Fig. 1:** Inflamed remnant appendiceal stump



**Fig. 2:** Appendectomy specimen

was 40 mm. CT scan and ultrasonography findings may not be specific for stump appendicitis. Associated changes, like pericecal inflammatory changes, cecal wall thickening, abscess formation and fluid in the right paracolic gutter may be seen.

Preoperative CT scan is a more effective technique to aid diagnosis. The incidence of stump appendicitis is increased possibly due to usage of laparoscopic surgical techniques.

Prior history of appendectomy cannot rule out possibility of appendicitis. This dilemma may sometimes delay in diagnosis and treatment. Therefore, a high index of suspicion is required for diagnosis.

## BIBLIOGRAPHY

1. Aschkenasy MT, Rybicki FJ. Acute appendicitis of the appendiceal stump. *J Emerg Med* 2005;28:41-43.
2. Baldisserotto M, Cavazzola S, Cavazzola LT, Lopes MH, Mottin CC. Acute edematous stump appendicitis diagnosed preoperatively on sonography. *Am J Roentgenol* 2000;175:503-04.
3. Carcacia ID, Vazquez JL, Iribarren M, Pardellas H. Preoperative diagnostic imaging in stump appendicitis. *Radiologia* 2007;49:133-35.
4. Erzurum VZ, Kasirajan K, Hashmi M. Stump appendicitis: A case report. *J Laparoendosc Adv Surg Tech A* 1997; 389-91.
5. Gupta R, Gernshiemer J, Golden J, Narra N, Hay dock T. Abdominal pain secondary to stump appendicitis in a child. *J Emerg Med* 2000;18:431-33.
6. Mangi AA, Berger DL. Stump appendicitis. *Am Surg* 2000;66:739-41.
7. Rao PM, Sagarin MJ, McCabe CJ. Stump appendicitis diagnosed preoperatively by computed tomography. *Am J Emerg Med* 1998;16:309-11.
8. Robledo-Ogazon F, Bojalil-Duran L, Vargas-Rivas A, Torres-Vieyra L, Valle-Carmona Y. Appendiceal stump appendicitis: A Case report. *Cir Cir* 2005;73:311-14.
9. Roche-Nagle G, Gallagher C, Kilgallen C, Caldwell M. Stump appendicitis: A rare but important entity. *Surgeon* 2005;3: 53-54.
10. Rose TF. Recurrent appendiceal abscess. *Med J Aust* 1945;32:652-59.
11. Shin LK, Halpern D, Weston SR, Meiner EM, Katz DS. Prospective CT diagnosis of stump appendicitis. *AJR Am J Roentgenol* 2005;184:62-64.
12. Thomas SE, Denning DA, Cummings MH. Delayed pathology of the appendiceal stump: A case report of stump appendicitis and review. *Am Surg* 1994;60:842-44.
13. Uludag M, Isgor A, Basak M. Stump appendicitis is a rare delayed complication of appendectomy: A case report. *World J Gastroenterol* 2006;12:5401-03.
14. Yigit T, Menten O, Eryilmaz M, Balkan M, Uzar AI, Kozak O. Stump resections resulting from incomplete operations. *Am Surg* 2007;73:75-78.

# Laparoscopic versus Open Management of Hydatid Cyst of Liver

Falih Mohssen Ali

Consultant Surgeon, Basrah Teaching Hospital, Iraq

## ABSTRACT

**Background:** To compare laparoscopic versus open management of the hydatid cyst of liver regarding recurrence rate, the surgical approach to liver *echinococcosis* is still a controversial issue. This study shows our results of surgical treatment of liver hydatid cysts during a 5 years period.

**Methods:** A prospective study of 32 patients operated on in a 5-year period (1999-2003) in Dubrava University Hospital, Zagreb, Croatia, with hepatic hydatid cyst. All patients were preoperatively treated with albendazole. In 32 patients, total pericystectomy without opening the cyst cavity was performed laparoscopically, other procedures were used as surgical approach.

**Results:** There was no mortality after 5 to 6 months follow-up, but in one patient, in the open partial pericystectomy group, recurrence of the disease occurred after 2 to 3 years. When a laparoscopic procedure was done, there were no complications or recurrence. The median operative duration for open surgery was 100.0 minutes (range 60.0-210.0) and for laparoscopic surgery 67.5 minutes (range 60.0-120.0). The median length of hospitalization for open surgery was 8.0 days (range 7.0-14.0) and for laparoscopic surgery 5.0 days (range 4.0-7.0).

**Conclusion:** Total pericystectomy without opening the cyst cavity, preceded by preoperative albendazole therapy is the method of choice for hepatic hydatid cyst treatment. Despite the small group of patients, our first results show laparoscopic total pericystectomy, without opening the cyst cavity, in the treatment of hepatic hydatid cyst.

**Keywords:** Laparoscopical treatment, Liver, Hydatid cyst, Abdominal approach.

## INTRODUCTION

Hydatid disease is a rare entity primarily affecting the population of developing countries. Septation and calcification of the cysts with a high antibody titer in the patient's serum confirm the diagnosis, although more sophisticated tests have been applied recently. Surgery constitutes the primary treatment with a variety of techniques based on the principles of eradication and elimination of recurrence by means of spillage avoidance.

1. Hydatid disease is endemic mainly in the Mediterranean countries, the Middle East, South America, India, Northern China and other sheep-raising areas; however, owing to increased travel and tourism all over the world, it can be found anywhere, even in developed countries. Hydatid disease is a zoonotic infection caused by adult or larval stages of the cestode *Echinococcus granulosus*.
2. The prevalence of hydatid disease among human was determined as 9.1% in a World Health Organization study in central Peruvian Andes.
3. In humans, most hydatid cyst occur in the liver and 75% of these are single cyst and other common organs included are lung, spleen and kidney.
4. The hydatid cyst of the liver has two layers: The ectocyst—a dense fibrous host reaction to the parasite, and the parasite—derived endocyst which has an outer laminated and an inner germinal layer. The single-celled

germinal membrane gives rise to broad capsules, which contain the scoleces and daughter cysts, which float freely in the clear cyst fluid.

5. Surgery remains the gold standard in terms of therapy for patients with hepatic hydatid cyst. Despite significant advances in medical treatment and interventional radiology, the conventional operative procedures of the hydatid cyst of the liver, like enucleation, cystectomy, evacuation, marsupialization, etc., which involve a significant morbidity especially in term of wound infection are used. Laparoscopic treatment of hepatic hydatid disease has been increasingly popular parallel to the progress in laparoscopic surgery.
6. Controversies about the role of laparoscopy in the management of liver hydatid cyst have not been resolved; these controversies include selection of patients and surgical technique. This study presents our experience and results in laparoscopic treatment of hepatic hydatid cysts.<sup>1-3</sup>

## PATIENTS AND METHODS

From November 2007 to January 2010, 32 patients with liver hydatid cyst were treated laparoscopically in the Department of General Surgery, Ain Shams University Hospital, Cairo, Egypt and New Al-Jedaani Hospital, Jeddah, Saudi Arabia. The study group consisted of 14 men and 18 women. Ages ranged from 26 to 63 years (mean

age 43.4 years). The most common complaints were dull pain at the right hypochondrium or/and epigastrium and palpable mass. Patients were diagnosed by ultrasonography (US) (Fig. 1), computed tomography (CT), magnetic resonance imaging (MRI) and confirmed by serological examination (immunoelectrophoresis which has a high sensitivity, being positive in 30 patients). We excluded cases with multiple liver hydatid cysts having more than two or cysts located in blind area for laparoscopic procedures, like segments 1, 2 and 7. Our exclusion criteria also included intraparenchymal location of the cyst or cysts with thick and calcified walls. All procedures were performed under general anesthesia and in the supine position. Prophylactic antibiotics were administered for 30 minutes before the operation. The surgeon and the camera assistant standing on the left side of the patient with the assistant and scrub nurse standing on the right side of the patient. Four ports were placed, a supraumbilical 10 mm port through which a 0° telescope inserted, another 10 mm port inserted at the epigastrium as near as possible to the cyst and used as a working channel and two additional 5 mm ports inserted according to the cyst location.<sup>4</sup> From the epigastric port, gauzes soaked with 20% hypertonic saline as scolical agent were introduced into the abdominal cavity and placed around the cyst. The cyst was punctured with long laparoscopic needles connected to vacuum suction through epigastric port; another sucker was introduced through the right 5 mm port to avoid accidental spillage of the cyst content. Cystic fluid was aspirated and then 100 ml of 20% hypertonic saline was injected inside cyst via the same needle then aspirated (Fig. 2), this procedure was repeated three times and then the needle was withdrawn while still connected to suction to prevent back spillage from needle, and then deflated cystic wall was suspended by two graspers, and cystotomy was performed by electrocautry, and the laminated membrane was carefully removed and put into endobag and retrieved through epigastric port, then the

laparoscope was inserted into the cyst to exclude any biliary communication or retained daughter cysts. The cystic cavity was irrigated with 20% hypertonic saline several times, and partial or near total cystectomy was done by using harmonic scalpel, then a drain was placed in the remaining cystic cavity, and gauzes were placed in an endosac and removed. Postoperative follow-up was very smooth, oral fluid intake was allowed next day of operation, drain was removed at 48 hours after operation if no apparent bile in the drain, patients were discharged to home and advised for follow-up at 2 weeks, 3 months and 6 months and then yearly by ultrasound and serological tests (immunoelectrophoresis test).<sup>5,8,11</sup>

### Indications

1. Single superficial cyst that may rupture
2. Large cyst with multiple daughter cysts
3. Cysts in communication with the biliary tree
4. Infected cysts
5. Cysts giving compression to the near vital organs.

### Contraindications

1. Dead cysts
2. Multiple cysts
3. Cysts difficult to access
4. Small cysts.

### LAPAROSCOPIC PROCEDURE

A lot of clinical studies that had been done to compare laparoscopic vs open hydatid liver particularly the recurrence rate, most of them advocate laparoscopy that is why in last years morbidity and mortality decrease.

Palanivelu planned a recent technique, the so-called Palanivelu Hydatid System (PHS). The PHS consists of a complex system of fenestrated trocar and cannulas through which it reduced at least the peritoneal spillage.

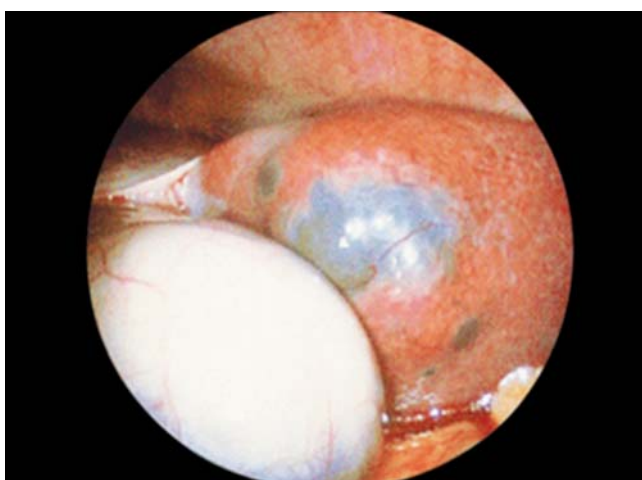

Fig. 1: Exposure of liver hydatid

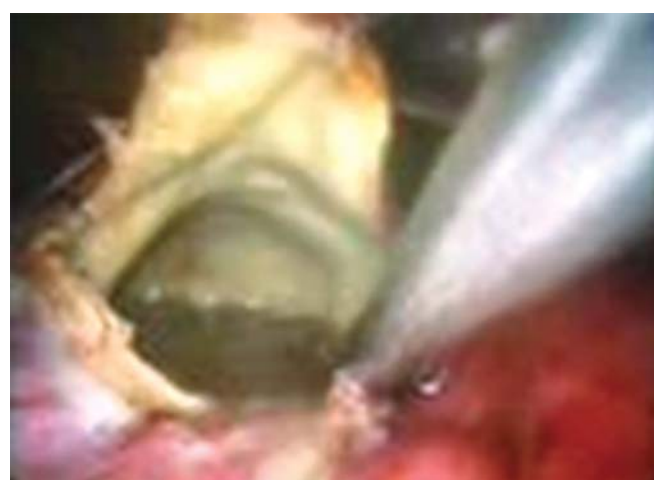

Fig. 2: Aspiration

## Radical Surgery

In the pericystectomy technique (Fig. 3), the cyst was totally removed together with 1 cm of the liver parenchyma, without opening the cavity. In a left lobe lateral segmentectomy, to secure the vasculature of the left lobe lateral segment, the segmentectomy was performed after taking the mesentery. In both situations, drain put in area of operative field.

## Conservative Surgery

The anterior wall of the cystic lesion was removed as widely as possible. All the components of the cyst were removed from the interior. After washing the operated area with saline or Betadine solution, one or two drains were placed. Omentopexy was not performed when cysts were located proximally but was performed when cysts were located inferior to the liver.<sup>5-7,9</sup>

## Contraindications

1. Deep intraparenchymal cysts
2. Posterior cyst
3. More than three cysts
4. Cysts with tick and calcified walls
5. Cysts characterized by heterogeneous complex mass (Gharbi type 4)
6. Cyst less than 3 cm in diameter
7. Serious coagulation abnormalities.

## TECHNIQUE

After creating pneumoperitoneum through the umbilicus and after identifying the hydatid cyst, the PDS trocar is introduced into the peritoneal cavity directly over the hydatid cyst. Once the trocar is removed only the cannula is advanced until its tip is in contact with the hydatid cyst surface. After suction with cannula, a 5 mm trocar joined

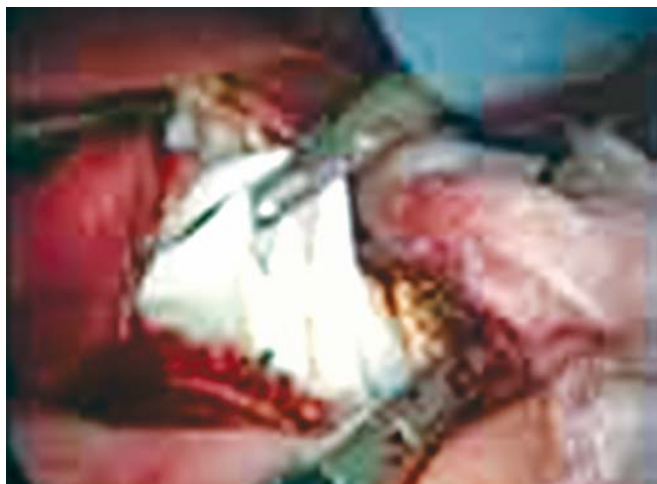

Fig. 3: Pericystectomy

to another suction machine is introduced into the cannula and is pushed into the cyst. The suction is immediate and happens either into the body of the hollow trocar and into the suction cannula, or into cannula and then into the suction side-channel. The trocar is removed, the peritoneal cavity is irrigated by the main channel while the suction is maintained all the time. After removing fluid, the telescope is introduced to visualize the interior of the cavity for control any cyst-biliary communication; a scolicedal agent is instilled into the cyst cavity and after 10 minutes it is suctioned and the cyst is marsupialized. In case of bile leakage, use of scolicedal agent is avoided.<sup>10,11</sup>

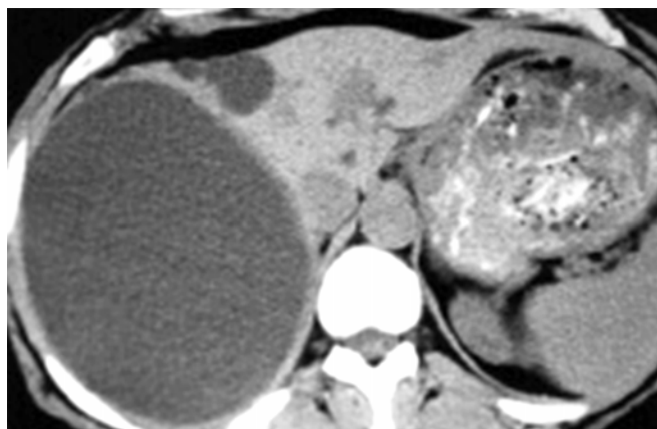
Although the rate of recurrence is lower with radical surgery, application is limited as the associated morbidity and mortality rates are high.<sup>6</sup> In the radical surgery cases in our study, four were in the left lobe lateral segment with straightforward localization and the other 14 were exophytic locations, therefore, there was no mortality or morbidity related to surgery. The laparoscopic approach is a treatment method developed in recent years using an umbrella trocar to perform partial or total cystectomy.<sup>6,7</sup>

## ALBENDAZOLE TREATMENT

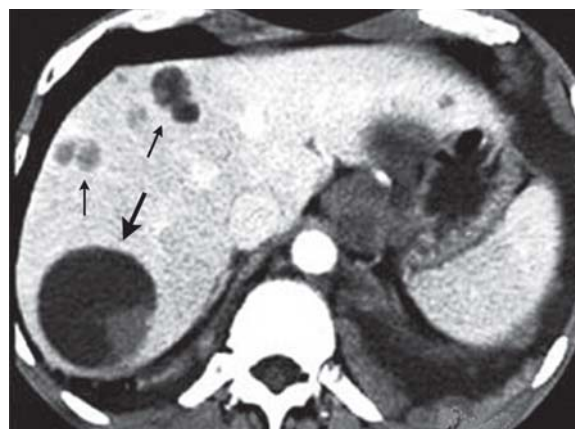
All patients with hydatid disease the size was seen to have increased, firstly albendazole treatment was administered. When the size continued to increase despite this, then surgery was planned at our clinic were administered 10 mg/kg albendazole for 14 to 21 days preoperatively. During this period, liver function tests were closely observed. For all patients undergoing surgery, the same treatment protocol was recommended on postoperative day 1 and continued for 14 to 21 days. If patients experienced recurrence during follow-up, again 14 to 21 days treatment was administered preoperatively, and the postoperative treatment period was 2 months (Figs 4 to 6).

## RESULTS

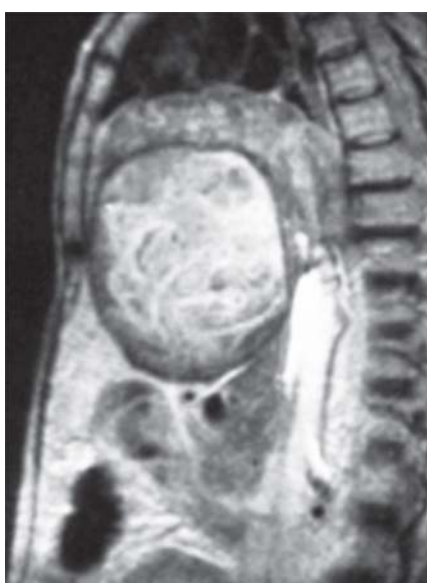Around 32 patients (18 women and 14 men) with liver hydatid cyst underwent laparoscopic cystotomy and partial cystectomy during the study period from November 2007 to January 2010. The presenting symptoms of patients is shown in Table 1. Abdominal ultrasound, abdominal computed tomography and serological examination (immunoelectrophoresis) confirmed the diagnosis of hepatic hydatid cyst in all patients. A total of 28 patients had solitary liver cyst and four patients had two cysts; 16 cysts located in segment 6, 12 cysts located in segments, four cysts located in segment 3 and four cysts located in segments 4. Mean operative time was 54 minutes (range 45-130 minutes). No conversion to open procedure was required. We had one case that devolped an aphyllaxis during procedure but recovered well, the anaphylaxis devolped secondary to direct



**Fig. 4:** Computed tomography (CT) scan appearance of a large hepatic cyst



**Fig. 6:** Multiple hydatids liver that required postoperative albendazole therapy



**Fig. 5:** Magnetic resonance imaging of sagittal hepatic cysts

contact of hydatid fluid to blood stream after accidental laceration of the liver. Bile leakage was observed in one patient on the second postoperative day, which was managed by endoscopic sphincterotomy. The leakage gradually ceased within 6 days. This patient was discharged on the tenth postoperative day, in other patient, an infected subhepatic collection developed after discharge from the hospital. This patient was rehospitalized with pain and high fever, and the collection was drained percutaneously guided by ultrasound. The mean length of hospital stay was 4.3 days (range 4-10 days). The mean follow-up was 15.6 months (range 6-25 months). Radiological and serological test results showed no recurrences for all patients.

**Table 1:** Symptomatology of patients with liver hydatid cyst

Symptom	No.	%
Pain	18	56.20
Abdominal mass	12	37.50
Dyspepsia	4	12.50
Jaundice	2	6.25

## DISCUSSION

In our study, 72.8% of the patients were symptomatic, while 27.2% were asymptomatic. In all of the patients, the cysts found were  $\geq 6$  cm. The choice of the better management of hydatid cyst of the liver is very difficult because of variable clinicopathological aspects. The treatment should be individualized to the morphology, size, number and location of the cysts. Hydatid liver disease is still endemic in certain regions of the world. The incidence of hydatid disease in Turkey ranges from 2/10,00,000 to 1/2,000 in different studies. The progresses fulfilled in the latest years by laparoscopic management have made the applications of this technique possible to a more and more number of growing cases. It is sure that the Palanivelu Hydatid System (PHS) has revolutionized the treatment of hydatid cyst of the liver because this sealed procedure not only avoids any spillage of the fluid but also allows intracystic magnified visualization for cyst biliary communications. By its application, fields are excluded only deep intraparenchymal or posterior cysts situated close to the vena cava. Consequently, reduced time range hospitalization that is for the laparoscopy, in the opinion of some authors, of 3 to 12 day against the mean hospitalization time range in the open that is of 9 to 20 days; mortality with the laparoscopic procedure goes down to almost 0% and morbidity has determinate dramatic and sensible reduction of the recurrence.<sup>8,9</sup>

## CONCLUSION

It is better and safe to use laparoscopy in treatment of hydatid liver with less morbidity, mortality and recurrence rate in comparison with open technique.

It is recommended to use postoperative albendazole therapy.

## REFERENCES

1. Derveniz C, Delis S, Avgerinos C, Madariaga J, Milicevic M. Changing concepts in the management of liver hydatid disease. *J Gastrointest Surg.* Jul-Aug 2005;9(6):869-77.

2. Stephan A, Keith DL, Zinner MJ, Schwartz SI, Harold Ellis. Liver abscess and hydatid cyst disease. *Mangot's abdominal operations* Prentice Hall International Inc 1997;1534-37.
3. Moro PL, McDonald J, Gilman RH, et al. Epidemiology of *Echinococcus granulosus* infection in central Peruvian Andes. *Bull: World Health Organization Organ* 1997;75(6): 553-61.
4. Perek A, Numan F, Durgan V, et al. Management of a patient with hepatic, thoracic–pelvic and omental hydatid cyst and post-operative biliocutaneous fistula. A case report. *Hepato gastroenterology* 1999.
5. Bach, Lefler E, Barash EF, Eitan A. Laparoscopic approach to hidatid liver cyst. Is it logical? Physical, experimental and practical aspects. *J Surgical Endoscopy* 1998;12(8).
6. Bickel A, Loberant N, Singer-Jordan J, Goldfeld M, Eitan A. The laparoscopic approach to abdominal hydatid cysts. *Arch Surg* 2001;136. Ertem M, Karahasanoglu T, Yavuz N, Erguney S. Laparoscopically treated liver hydatid cysts. *Arch Surg* 2002;137:1170-73.
7. Eren Berber is currently a fellow at The Cleveland Clinic Foundation Department of General Surgery. Istanbul University, Istanbul Faculty of Medicine, Department of Surgery, Istanbul, Turkey.
8. Jenkins DJ, Romig T, Thompson RC. Emergence/re-emergence of *Echinococcus* spp: a global update. *Int J Parasitol* 2005;35: 1205-19.
9. Topcu O, Sumer Z, Tuncer E, Aydin C, Koyuncu A. Efficacy of chlorhexidine gluconate during surgery for hydatid cyst. *World J Surg* 2009;33:1274-80.
10. Secchi MA, Pettinari R, Mercapide C, Bracco R, Castilla C, Cassone E, Sisco P, Andriani O, Rossi L, Grondona J, et al. Surgical management of liver hydatidosis: A multicentre series of 1412 patients. *Liver Int* 2010;30:85-93.
11. Aydin U, Yazici P, Onen Z, Ozsoy M, Zeytunlu M, Kiliç M, Coker A. The optimal treatment of hydatid cyst of the liver: Radical surgery with a significant reduced risk of recurrence. *Turk J Gastroenterol* 2008;19:33-39.

# A Review on the Role of Laparoscopy in Abdominal Trauma

Aryan Ahmed

Specialist General Surgeon, ATLS Instructor, Department of General Surgery, Hamad Medical Corporation, Doha, Qatar

## ABSTRACT

**Background:** The trauma victims are considered the top critical patients and require a rapid decision in the management. As the main fear is bleeding, so most of them ended having laparotomy, although almost 40% ended having a less invasive management like using laparoscopy.

**Materials and methods:** The use of laparoscopy as a diagnostic (with the facility to be used as a therapeutic) option at the same setting can be considered a very good tool provided the patient is hemodynamically stable. Classically, standard three ports (extraport can be added according to therapeutic technique) are used. Most of the intestinal, mesenteric and diaphragmatic injuries can be detected and repaired successfully as well as some parenchymal injuries, provided not bleeding actively and, if necessary, using some tissue adhesives.

**Results:** The laparoscopic technique as a diagnostic as well as therapeutic tool (in some cases) can be used safely and with fewer complications as it reduces the significant number of negative laparotomies.

**Conclusion:** An access to the abdominal cavity laparoscopically can achieve good results in hemodynamically stable patients and avoids the morbidities related to laparotomy, decreases hospital stay and considered as a cost-effective tool.

**Keywords:** Abdominal trauma, Laparoscopy.

## INTRODUCTION

The death rate due to trauma is increasing in the industrialized country, whether blunt or penetrating injury. Most of the victims are of young age groups. Most of the multiply injured patients dies before reaching hospital because of severe neurological or vascular injuries. Due to the increasing experience of the surgeon, minimal access surgery has found its way in the diagnosis as well as treatment of patients. As the patients are considered critical, so they need a rapid decision to be managed either surgically or conservatively. The hemodynamically unstable patients has a less chance of conservative approach, in reverse to that the stable one can be managed conservatively, although this is not applicable in all circumstances. In spite of using different tools to diagnose injuries, sometime a great challenge will phase the treating physician but that should not make a delay in proper management.<sup>1</sup>

## MATERIALS AND METHODS

The management of trauma patients should be through a systematic way according to ATLS protocol which implies a rapid and proper examination, knowing the mechanism and severity of injury, and a concise history, if possible which all together provides a clue to the possible injuries. Many diagnostic tools are available for quick assessment, like focused abdominal sonography for trauma (FAST), diagnostic peritoneal lavage (DPL) (Figs 1 to 3) and computerized tomography scan (CT scan).<sup>1,3</sup>

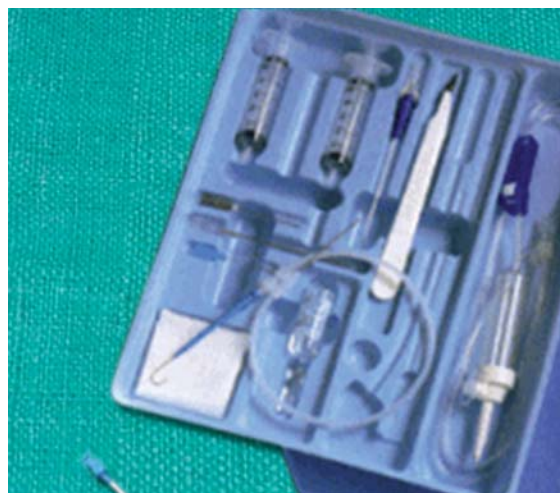

Fig. 1: Diagnostic peritoneal lavage kit

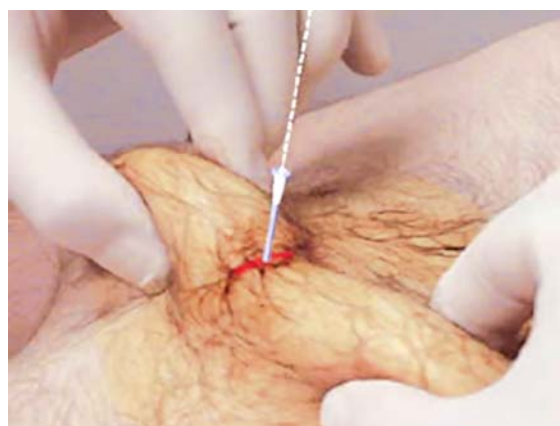
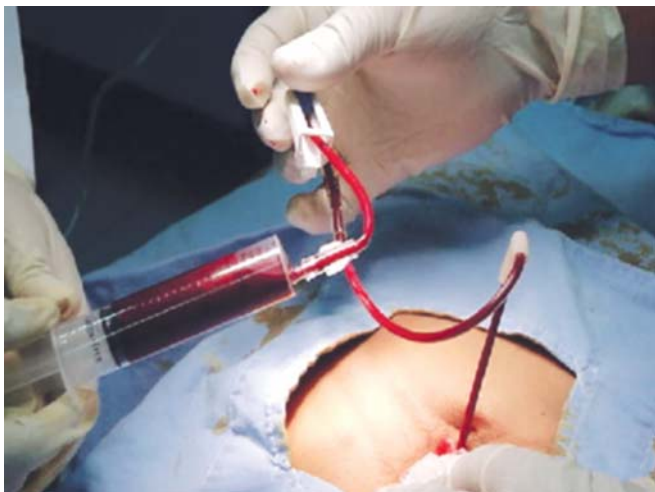
Fig. 2: Technique of inserting DPL catheter



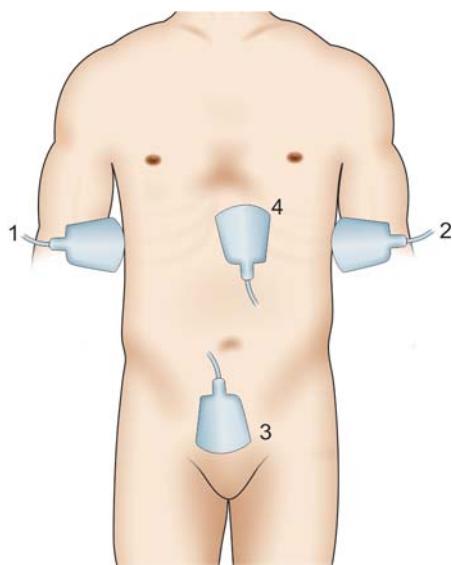
**Fig. 3:** Positive DPL test

DPL and FAST provide a quick access to assess the internal bleeding and are very specific but not sensitive (do not provide the information of the source of bleeding). Usually, the unstable patients fall into this group and require urgent laparotomy.<sup>6</sup>

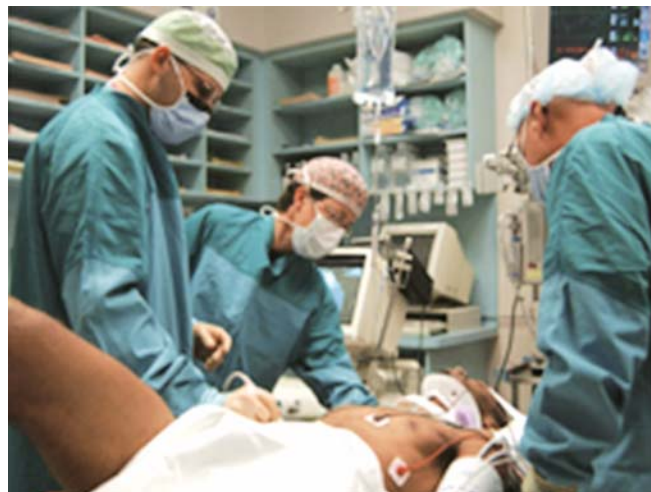On the other hand, CT scan has to be used for stable patient as it is time consuming and needs transfer to the radiology department. It provides a sound knowledge of injury and the source of bleeding, and is very specific in delineating solid organ injuries.

Of the abovementioned diagnostic tools, each has its own drawback, i.e. DPL and FAST (Figs 4 to 7) are not informative in regards to parenchymal injuries. DPL, FAST and CT scan—all can miss hollow viscus and diaphragmatic injuries.

In some cases of stable blunt abdominal trauma, when the diagnosis is of uncertainty and most of the cases of penetrating injuries, the role of laparoscopy should be



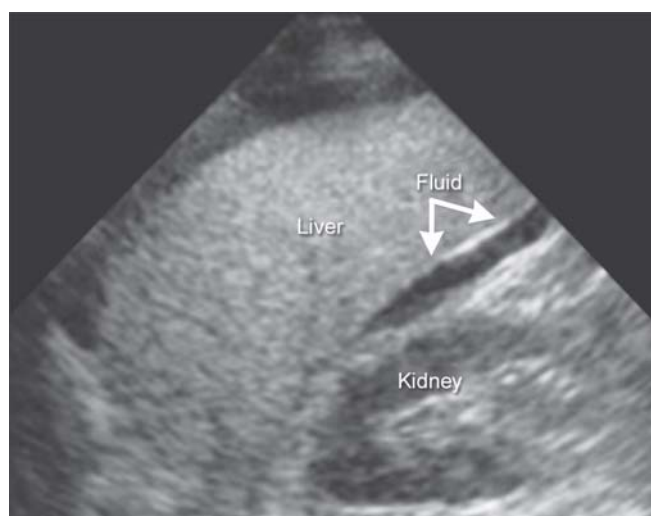**Fig. 4:** Technique of FAST



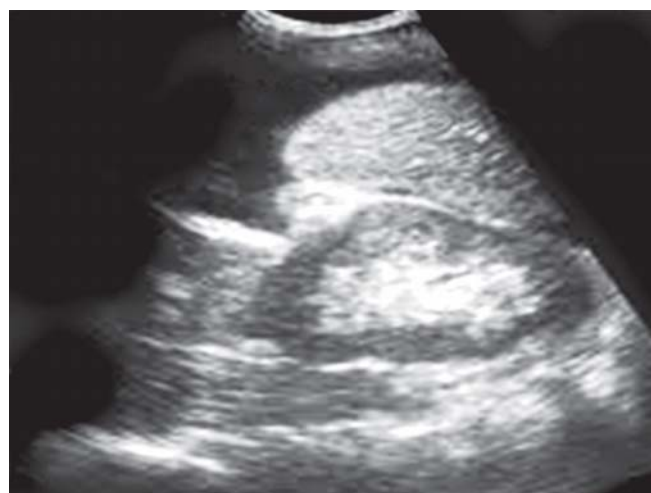**Fig. 5:** Focused abdominal sonography for trauma (FAST)

considered strongly as among the best tool in diagnosis and sometimes treatment as well.

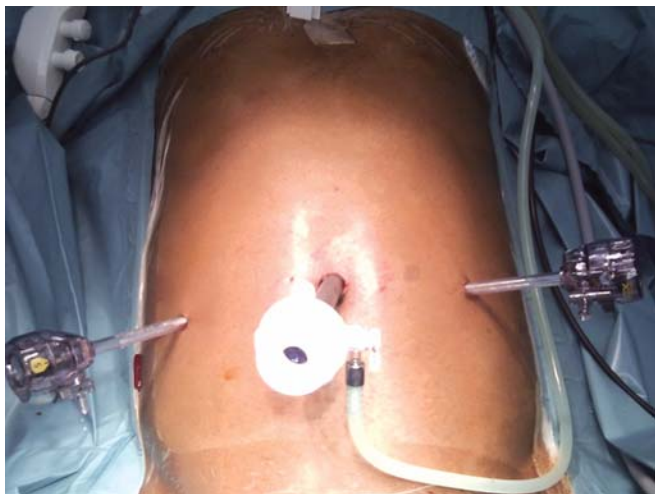The standard three ports are used (one optical and two operating ports) (Fig. 8); a systematic clock wise diagnostic



**Fig. 6:** Fluid in the Morison pouch



**Fig. 7:** Fluid in the splenorenal pouch



**Fig. 8:** Three-port technique

exploration should be undertaken starting from right hypochondrial region, assessing all solid organs, lower esophagus, stomach, duodenum and rest of small bowel by running it from ileocecal valve to duodenojejunal junction, colon and rectum, mesentery as well as diaphragm as mostly missed by the noninvasive radiological tools.

Violating the peritoneum in the penetrating wound injury is an indication for laparoscopic exploration, and sometime local wound exploration is not informative due to the tangential track of the injury, provided the peritonitis is excluded because that declares a delayed presentation which needs aggressive surgical intervention and toileting.

A retrospective cohort study made for about 86 patients who sustained abdominal stab wound and were divided into two groups, resulted in reducing nontherapeutic laparotomy and avoiding its complications in most of the hemodynamically stable cases.<sup>2</sup>

In some other studies, an extensive review is made on the effect of laparoscopy as a diagnostic and therapeutic tool in the management of diaphragmatic ruptures, and considered the best line of management,<sup>4</sup> even a rare case of traumatic intrapericardial diaphragmatic injury and herniation were managed successfully.

Although it is out of debate that video-assisted laparoscopy and thoracoscopy should be conducted for stable patient, some study has shown beneficial even for unstable cases, provided it is utilized properly in experienced hand.

## DISCUSSION

The American College of Surgeon, committee on trauma has standardized the management of patients sustaining trauma whether blunt or penetrating after an accident happened to the orthopedic surgeon Dr Jim Styner who crashed his small plane into the rural area in 1976. After that a new program was developed in 1978 (the year of 1st ATLS course).

The standard method of resuscitating trauma patient is to follow ABCDE protocol (airway, breathing, circulation, disability and exposure). Treating airway has number one priority because if the patient can respond well, it indicates almost near normal ventilation and oxygenation as well as normal level of consciousness (GCS of 15/15). In resuscitating these patients, the 1st hour from the time of accident is uniquely important which is called golden hour, due to the importance of managing the life-threatening injury in that particular time, and within these critical minutes airway management should be the first task of the paramedics or physician. When life-threatening injuries, like tension pneumothorax, massive hemothorax, injury to the thoracic aorta and ruptured bronchopulmonary tree, have happened, the resuscitation has to be as fast as airway, because some of them affects the airway, oxygenation and ventilation at the same time. Bleeding is always considered as a threatening signal towards death, that is why it is the most stressful one to be managed, here is the arena where surgeon has to act quickly and properly as minutes will be counted rather than hours, and when the case is not hemodynamically stable, the option of laparoscopic approach does not exist and should not be attempted because it is time consuming and leads to many cardiorespiratory derangements in an already compromised victim.

Still as part of primary resuscitation, the last but not the least is neurological assessment as neurogenic shock should be kept in mind and not to be confused with the hypovolemic one, and examining (exposing) the patient in a warm environment to avoid hypothermia.

The revolution in surgery nowadays is towards minimal access approach, neither the less, this has also taken over in traumatology for selected cases (stable patients whether sustained blunt or penetrating injuries). Not only that, some trauma centers have made their own approach in handling these cases with the use of video-assisted techniques.

Previously there were literatures not supporting to the use of laparoscopy in trauma due to complications, including missed intestinal injuries, trocar and needle-related enteral and vascular injuries as well as gas embolism, but this has dramatically reduced as the new techniques and triangulations with ergonomics has respected.<sup>1</sup> Some authors have reported gas embolism in cases of inferior vena cava laceration,<sup>8</sup> this was the lead point to the gasless technique. Tension pneumothorax has also been reported in cases of diaphragmatic injuries.<sup>9</sup>

Sometime inspite of using all the high quality investigations and imaging techniques, intra-abdominal injuries remain as a great challenge to be diagnosed, and so that is why still laparotomy is performed as a standard line of treatment. Provided the patient is stable, this is the field where laparoscopy has a great role. Although it is

not used routinely, a significant number of therapeutic procedures were applied like repair of injured diaphragm (Figs 9A and B) using suture, stapler or even mesh, closure of bowel perforation, resection anastomosis of injured intestine, control of parenchymal injuries using adhesives, energy sources, splenectomy and even distal pancreatectomy.<sup>7</sup>

Although in our review, we have shown that laparoscopy can be used for both penetrating and blunt trauma in a hemodynamically stable case, nowadays most of the level 1 trauma centers all over the world have developed their own program in dealing mostly with penetrating injury as it seems more promising to be the standard in the near future than for blunt injuries.

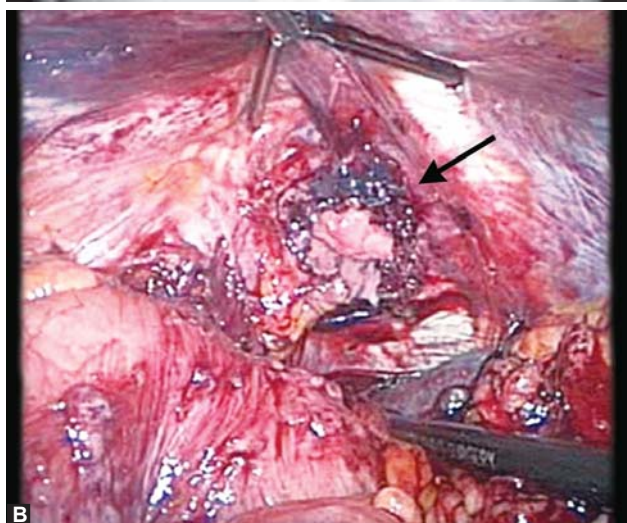
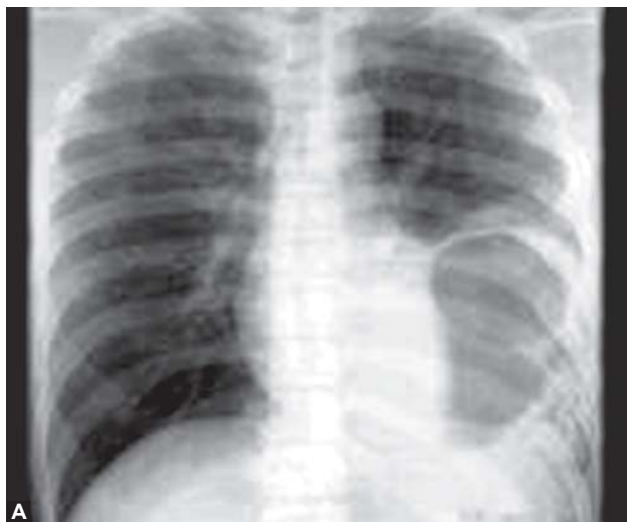
Cardiorespiratory derangement can be expected in laparoscopic surgery as creating pneumoperitoneum using carbon dioxide decreases the venous return by compressing the vena cava and thus pooling blood in the lower part of body, splinting the diaphragm also leads to improper ventilation and oxygenation. So, if this is the case for a patient undergoing an elective surgery (the derangements can be compensated during surgery by anesthetist), why to

double the risk in a compromised unstable patient, this is a question that has been answered by many pioneers of trauma surgery and has been uncovered in so many literatures, that the case should undergo laparotomy rather than video-assisted surgery.<sup>5</sup>

Conducting the laparoscopic surgery for trauma patients is better to be under low pressure pneumoperitoneum as it will be tolerated rather than the routine 14 mm Hg pressure.

In treating injuries, many techniques have been described. For example, in splenic injury (Fig. 10) (stable case), tissue adhesive has been used with good result as well as for hepatic injuries (Fig. 11), even sometime partial splenectomy can be conducted depending on the skill of operating surgeon. Diaphragmatic rupture and tears are treated by using suture, stapler or even sometime a properly sized synthetic mesh. Mesenteric tears are dealt with depending on its size and bowel affection, it ranges from simple closure of the defect to bowel resection and anastomosis.<sup>7</sup>

Diaphragmatic injury is a matter of concern as the signs and symptoms may be delayed regardless of the mechanism



Figs 9A and B: Diaphragmatic injury (arrow)

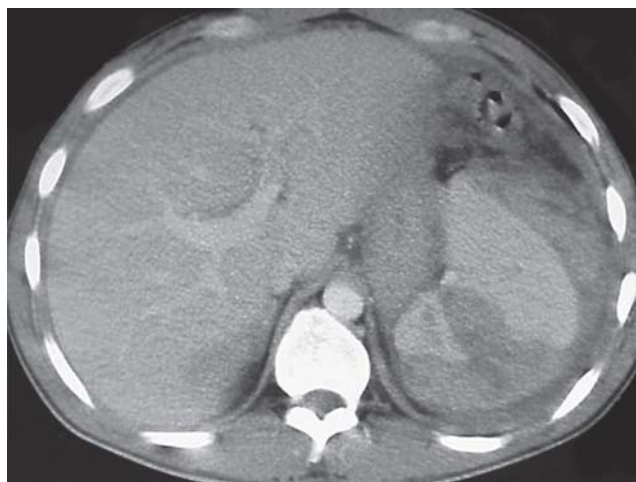

Fig. 10: Splenic injury

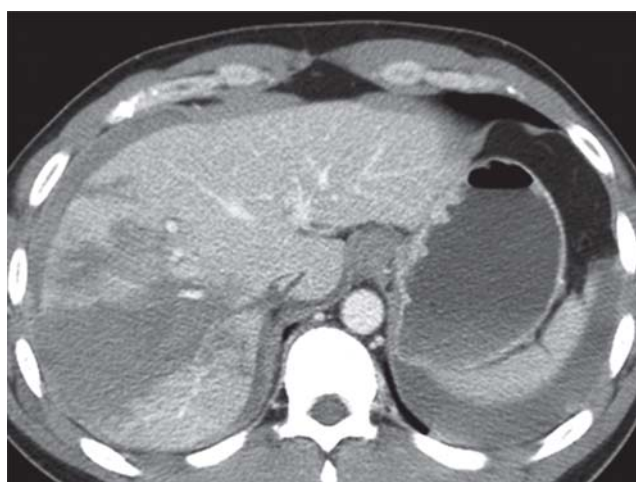

Fig. 11: Hepatic injury

of injury, in that view the key hole approach is the best way for repair.

## CONCLUSIONS

It is safe and technically feasible to use laparoscopy as a diagnostic and therapeutic tool in the management of selected hemodynamically stable cases.<sup>10</sup>

The data has shown that it decreases the rate of negative laparotomy when applied properly in experienced hand, as the surgeon has a great role in utilizing video-assisted technique for trauma cases when there is a good familiarity with the procedure and improvement in the skills, including ergonomics, port positioning and depth perception, is respected.

## REFERENCES

1. Eur J Trauma Emerg Surg 2010;(1).
2. World Journal of Surgery 2010;34(7):1653-62.
3. European Surgery 1999;31(2):59-64.
4. World Journal of Emergency Surgery 2009;4:32.
5. Advances in Surgery 2007;41:51-62.
6. ATLS for Doctors (8th edition).
7. Zantut LF, Ivatury RR, Smith RS, Kawahara NT, Porter JM, Fry WR, Poggetti R, Birolini D. Diagnostic and therapeutic laparoscopy for penetrating abdominal trauma: J Trauma 1997;42:825-31.
8. Smith RS, Fry WR, Morabito DJ, Koehler RH. Therapeutic laparoscopy in trauma. Am J Surg 1995;170:632-37.
9. Fabian TC, Croce MA, Stewart RM. A prospective analysis of diagnostic laparoscopy in trauma. Am Surg 1993;217:557-65.
10. Surg Endosc 2003;17:421-27. DOI: 10.1007/s00464-002-8808-8.

# Single-Port Laparoscopic Placement of Peritoneal Dialysis Catheter

<sup>1</sup>Tag Alsir Alamin Logman, <sup>2</sup>RK Mishra

<sup>1</sup>Specialist General Surgeon, Sudan, Oman

<sup>2</sup>Senior Consultant Laparoscopic Surgeon, Professor in Minimal Access Surgery, Chairman and Director, World Laparoscopic Hospital Pvt Ltd, DLF Cyber City, Gurgaon, Haryana, India

## ABSTRACT

Recent advances in laparoscopic surgery have led to development of various laparoscopic techniques, both for treatment of malfunctioning catheter and insertion of a dialysis catheter. Most of the techniques use two to four ports. Each port entry can cause weakness of the abdominal wall, and hence possibility of leak or hernia. The technique of single port has been introduced for the management of obstructed catheter and insertion of another catheter. In this article, we report and evaluate the results of single port technique in the placement of tenckhoff catheter in chronic renal failure patients (in both adult patients and children).

**Aim:** To know the efficacy and safety of laparoscopic single port insertion of peritoneal dialysis catheter (tenckhoff) and its value in catheter efficiency time, postoperative complications, hospital stay, operation time.

**Materials and methods:** A review of literature by searching in Google, Springer library facility available at the world laparoscopy hospital.

**Characteristics of variables:** Male : Female ratio, mean age, catheter survival rate, hospitalization period, early and late postoperative complications, rate of hernia and leak, catheter migration, exit site infection.

**Keywords:** Laparoscopy, Tenckhoff, PD catheter.

## DETAILS OF THE PROCEDURE

The procedure is done under general anesthesia; patient was positioned in supine and 5 mm port was inserted for telescope at the left lateral margin of the rectus muscle in the upper quadrant at the midclavicular line. Pneumoperitoneum was created through same port. An intra-abdominal pressure was kept below 12 mm Hg during the procedure.

Diagnostic laparoscopy was done; a 5 mm incision was made just to the left of the umbilicus by 2 cm, and a coiled catheter was inserted towards the pelvis in a 45° angle to the abdominal wall.

The catheter position was checked, and patency insured by flushing, and good inflow and outflow obtained.

The catheter was then heparinized and used for dialysis after 2 weeks (Figs 1 and 2).

Mean operation time was 25 minutes.

## DISCUSSION AND RESULTS

Laparoscopic Tenckhoff catheter insertion was introduced in 1980. It has advantage over the open and percutaneous methods. It has lower incidence of flow obstruction, less chance of visceral injury and better patient compliance. The single-port method was developed for the management of

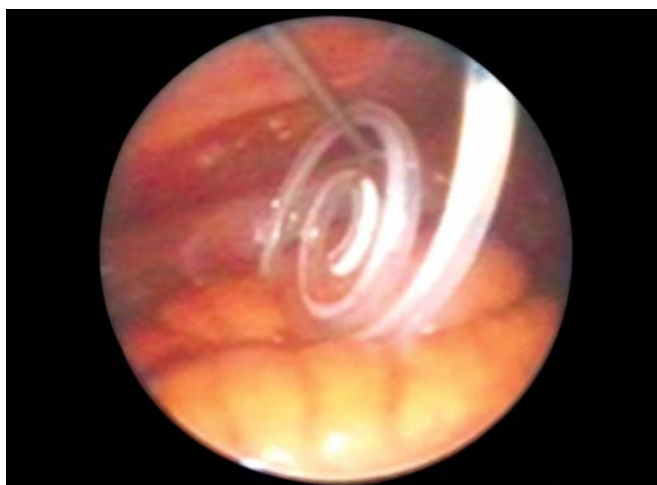


Fig. 1: Coiled catheter used in laparoscopic method

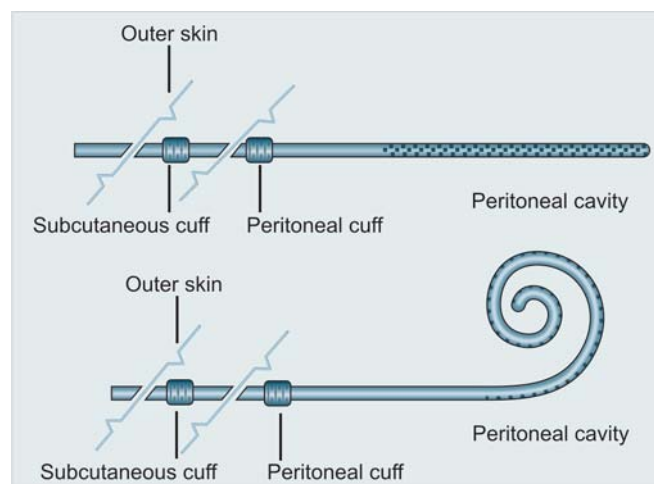


Fig. 2: Two types of PD catheters: Straight and Coiled

malfunctioning catheters and insertion of the catheter in a complicated abdominal cavity.

## CONCLUSION

Compared to open and multiple-port techniques, single-port laparoscopic tenckhoff catheter insertion is safe, with very high catheter survival rate, good patient compliance, less early and late postoperative complications, less chances of leak and hernia, less hospitalization time and less exit site infection rate.

## BIBLIOGRAPHY

1. Allon M, Soucie JM, Macon EJ. Complications with permanent peritoneal dialysis catheters: Experience with 154 percutaneously placed catheters. *Nephron* 1988;48:8-11.
2. Apostolidis NS, Tzardis PJ, Manouras AJ, Kostenidou MD, Katirtzoglou AN. The incidence of postoperative hernia as related to the site of insertion of permanent peritoneal catheter. *Am Surg* 1988;54:318-19.
3. Finan PJ, Guillou PJ. Experience with surgical implantation of catheters for continuous ambulatory peritoneal dialysis. *Ann R Coll Surg Engl* 1985;67:190.
4. Fleisher AG, Kimmelstiel FM, Lattes CG, Miller RE. Surgical complications of peritoneal dialysis catheters. *Am J Surg* 1985;149:726-29.
5. McIntosh G, Hurst PA, Young AE. The 'omental hitch' for the prevention of obstruction to peritoneal dialysis catheters. *Br J Surg* 1985;72:880.
6. Milliken I, Fitzpatrick M, Subramaniam R. Single-port laparoscopic insertion of peritoneal dialysis catheters in children. *Journal of Pediatric Urology* 2006;2:308-11.
7. Odor A, Alessio-Robles LP, Leuchter J, Mendoza A, Bordes J, Wadgymar A, et al. Experience with 150 consecutive peritoneal catheters in patients on CAPD. *Perit Dial Bull* 1985;5:226-29.
8. Poole GH, Tervit P. Laparoscopic tenckhoff catheter insertion: A prospective study of a new technique. *Aust NZJ Surg* 2000;70:371-73.
9. Spence PA, Mathews RE, Khanna R, Oreopoulos DG. Improved results with a paramedian technique for the insertion of peritoneal dialysis catheters. *Surg Gynecol Obstet* 1985;161:585-87.
10. Stone MM, Fonkalsrud EW, Salusky IB, Takiff H, Hall T, Fine RN. Surgical management of peritoneal dialysis catheters in children: Five-year experience with 1,800 patient-month follow-up. *J Pediatr Surg* 1986;21:1177.
11. Varela JE, Elli EF, Vanuno D, Horgan S. Mini-laparoscopic placement of a peritoneal dialysis catheter. *Surg Endosc* 2003;17:2025-27.
12. Zaontz MR, Cohn RA, Moel DI, Majkowski N, Firlit CF. Continuous ambulatory peritoneal dialysis: The pediatric experience. *J Urol* 1987;138:353-56.

# Laparoscopic Resection for Rectal Cancer: A Review and Update on Perioperative and Long-term Oncologic Outcome

Shehab CW Phung

Consultant Surgeon, Sarawak General Hospital, Kuching, Malaysia

## ABSTRACT

**Backgrounds:** With the advancement of science and technology in the field of minimal access surgery and refinement of techniques in laparoscopic resection of rectal cancer, it has been widely accepted that the procedure is technically feasible. The safety and oncologic efficacy of laparoscopic colonic cancer resection have been demonstrated. However, the availability of review and data are scarce in evaluating the perioperative safety and long-term oncologic outcome between laparoscopic surgery in the setting of rectal cancer and open approach.

**Aim:** The aim of this review is to provide an update on most recent review regarding perioperative safety and oncologic feasibility of laparoscopic resection for rectal cancer.

**Methods:** A review of up-to-date literature and the more recent retrospective and prospective data on laparoscopic resection for rectal cancer were undertaken for utilizing Pubmed/Google/Springer Link, specifically focussing on the long-term and perioperative outcomes.

**Keywords:** Rectal cancer, Laparoscopic rectal resection, Anterior resection.

## INTRODUCTION

In the current age of minimally invasive surgery, laparoscopic surgery (LPS) for colon cancer has been established as oncologically equivalent to conventional open surgery. The advantages of laparoscopic surgery have translated into smaller incisions and shorter recovery. However, regarding rectal cancer surgery, laparoscopic resection encounters far more challenges mainly due to steep learning curve and technical challenges including difficulties for pelvic exposure, rectal dissection, sphincter preservation and more importantly a lack of long-term data from large scale randomized controlled trial (RCT) series.

## CONVERSION RATE

In general, rectal cancer surgery is associated with high morbidity and mortality rates as compared to colon cancer surgery. The addition of total mesorectal excision (TME) reduces the local recurrence rate, but complete removal of mesorectum down to the pelvic floor devascularizes the rectal stump and increases anastomotic leak predisposing to higher mortality and morbidity. However, the safety of laparoscopic rectal cancer surgery has been extensively reported in the literature. In a recent Cochrane review of 4,424 patients from 48 studies comparing laparoscopic vs open TME for rectal cancer, Breukink reported no significant differences in morbidity and mortality rates with several short-term advantages in favor of laparoscopic resection, such as less blood loss, quicker return to normal diet, less pain as measured by narcotic use and reduced length of hospital stay.<sup>1</sup>

Among larger series, the morbidity and mortality rates of laparoscopic resection for rectal cancer ranged from 6.1 to 40% and 0 to 3% respectively.<sup>2-12</sup> All reports comparing laparoscopic vs open rectal cancer resection, including laparoscopic resection and APR, found no difference in morbidity and mortality.

The feasibility of any laparoscopic procedure is reflected by the associated conversion rate. It is a very important marker for laparoscopic success. The reported conversion rate of laparoscopic resection for rectal cancer generally range from 6 to 15.5%.<sup>13-17</sup> Excellent results could be achieved from series performed by single surgeons or surgical teams.<sup>8,14,15,17,18</sup> Leroy and Tsang et al reported conversion of only 3 and 1.9% respectively, in their series for laparoscopic rectal resection.<sup>4,7</sup> Open conversion during laparoscopic rectal resection has been reported to be associated with poor perioperative and oncological outcome. Strohlein et al<sup>9</sup> related an increase in metachronous metastasis and local recurrence in the converted group when compared with successful laparoscopic resection and open surgery group in rectal cancer surgery (metachronous metastasis: 26.3 vs 17.8 vs 14.9% respectively; local recurrence: 16 vs 6.9 vs 9.5% respectively). The multicenter CLASICC trial reported one of the highest conversion rates (34%) among the published reports and demonstrated poor perioperative outcome. When compared with the open group and successful laparoscopic resection, patients with conversion for colorectal resection in the CLASICC trial had higher operative mortality (5 vs 1 vs 9% respectively)

and also a higher complication rate.<sup>2</sup> Pugliese et al reported a 10% conversion in a series of 209 patients with laparoscopic rectal resection and observed significantly higher anastomotic leak rate in the converted group ( $p = 0.008$ ).<sup>19</sup> Both the CLASICC trial and the non-randomized comparative series from Strohlein et al reported tumor infiltration/fixation and obesity as the most common reason of conversion.<sup>2,9</sup> Fixation of tumor indicates more advanced disease and has been suggested as a reason of poor oncologic outcomes in previous studies.<sup>9,20</sup>

## PORT-SITE METASTASIS

The actual overall incidence of port-site metastasis is a rare event and about 0.1% from reviews and meta-analysis on this subject.<sup>16,21,22</sup> This figure is comparable to that of wound recurrence following open surgery.<sup>23,24</sup> According to these findings, port-site metastasis is not an inherent drawback of LPS for rectal cancer.

## LYMPH NODES HARVESTED

A proper oncologic curative resection of rectal cancer requires the adequate resection of regional lymph nodes. Retrieved lymph nodes are associated with improved survival and increased accuracy in staging. From most of the previous comparative studies, the mean number of lymph nodes retrieved ranges from 10 to 13.3 and that there was no significant difference compared with the open procedure.<sup>3,5,9,10,13</sup> In fact, there is an RCT trial which reported a difference in favor of laparoscopic TME.<sup>25</sup>

## LOCAL RECURRENCE

Local recurrence is a key indicator of oncological adequacy in rectal cancer surgery which varies dramatically among surgeons, the surgical technique being a major determinant.

In open surgery, the standard for local recurrence has been set by Heald et al<sup>26</sup> who reported a 4% local recurrence rate following low anterior resection of the rectum and TME with 10 years follow-up. The majority of the studies found similar local recurrence rates ranging from 3.9 to 5.9% for laparoscopic rectal resection.<sup>14,27,28</sup>

## LONG-TERM OUTCOME

Long-term survival data following laparoscopic resection of the rectum are scanty in the literature. The majority of long-term outcome data refer to a single surgeon experience series or comparative studies and only five RCT studies focusing on this subject are currently available with different length of median follow-up period with figures ranging from 33.1 to 87.2 months.<sup>14,18,25,29,30</sup> Data from these series reported no difference in terms of local recurrence, overall and disease-free survival among groups.

In contrast, Laurent et al<sup>28</sup> reported a better survival rate in laparoscopic stage III tumors with no difference in term of local recurrence and cancer-free survival between laparoscopic and open surgery with similar quality of surgery in a monocentric comparative study with over 400 patients with mid-and low-rectal cancer. A better survival rate in patients with stage III tumor was also reported by Lacy et al<sup>31</sup> in an RCT trial in patients with colon cancer and by Morino et al<sup>5</sup> in a prospective comparative study which focused on patients with extraperitoneal rectal cancer treated with laparoscopic or open surgery. More recently, Law et al<sup>32</sup> reported in a comparative monocenter series with a median follow-up of 34 months in patients with stage II and III rectal cancer, a 5-year actuarial survival of 71% in the laparoscopic group compared to a 59% survival rate in the open group, also identifying laparoscopy as one of the independent significant factors associated with better survival at the multivariate analysis.

## CONCLUSION

Based on the available data in literature, the mini-invasive approach to rectal cancer surgery is safe and feasible and does not seem to confer any disadvantage in term of local recurrence. With the recently concluded 5-year analysis of MRC CLASICC trial, laparoscopic resection of rectal cancer proves to be oncologically safe and does not compromise the long-term oncological results. The use of laparoscopic rectal surgery should be exploited to fully maximize favorable short-term outcomes and the long-term oncological results.

## REFERENCES

1. Breukink S, Pierie J, Wiggers T. Laparoscopic versus open total mesorectal excision for rectal cancer. *Cochrane Database Syst Rev* 2006;CD005200.
2. Guillou PJ, Quirke P, Thorpe H, et al. Short-term endpoints of conventional versus laparoscopic-assisted surgery in patients with colorectal cancer (MRC CLASICC trial): Multicentre, randomised controlled trial. *Lancet* 2005;365:1718-26.
3. Law WL, Lee YM, Choi HK, et al. Laparoscopic and open anterior resection for upper and mid rectal cancer: An evaluation of outcomes. *Dis Colon Rectum* 2006;49:1108-15.
4. Leroy J, Jamali F, Forbes L, et al. Laparoscopic total mesorectal excision (TME) for rectal cancer surgery: Long-term outcomes. *Surg Endosc* 2004;18:281-89.
5. Morino M, Allaix ME, Giraudo G, et al. Laparoscopic versus open surgery for extraperitoneal rectal cancer: A prospective comparative study. *Surg Endosc* 2005;19:1460-67.
6. Staudacher C, Di PS, Tamburini A, et al. Total mesorectal excision (TME) with laparoscopic approach: 226 consecutive cases. *Surg Oncol* 2007;16(Suppl 1):S113-16.
7. Tsang WW, Chung CC, Kwok SY, et al. Laparoscopic sphincter preserving total mesorectal excision with colonic J-pouch reconstruction: Five-year results. *Ann Surg*. 2006;243: 353-58.
8. Pugliese R, Di LS, Sansonna F, et al. Results of laparoscopic anterior resection for rectal adenocarcinoma: Retrospective analysis of 157 cases. *Am J Surg* 2008;195:233-38.

9. Strohlein MA, Grutzner KU, Jauch KW, et al. Comparison of laparoscopic vs open access surgery in patients with rectal cancer: A prospective analysis. *Dis Colon Rectum* 2008;51:385-91.
10. Bretagnol F, Lelong B, Laurent C, et al. The oncological safety of laparoscopic total mesorectal excision with sphincter preservation for rectal carcinoma. *Surg Endosc* 2005;19:892-96.
11. Kim SH, Park IJ, Joh YG, et al. Laparoscopic resection of rectal cancer: A comparison of surgical and oncologic outcomes between extraperitoneal and intraperitoneal disease locations. *Dis Colon Rectum* 2008;51:844-51.
12. Ng KH, Ng DC, Cheung HY, et al. Laparoscopic resection for rectal cancers: Lessons learned from 579 cases. *Ann Surg* 2009;249:82-86.
13. Baik SH, Gincherman M, Mutch MG, Birnbaum EH, Fleshman JW. Laparoscopic vs open resection for patients with rectal cancer: Comparison of perioperative outcomes and long-term survival. *Dis Colon Rectum* Jan 2011;54(1):6-14.
14. Ng SS, Leung KL, Lee JF, et al. Laparoscopic-assisted versus open abdominoperineal resection for low rectal cancer: A prospective randomized trial. *Ann Surg Oncol* 2008;15(9):2418-25.
15. Liang JT, Lai HS, Lee PH. Laparoscopic pelvic autonomic nerve preserving surgery for patients with lower rectal cancer after chemoradiation therapy. *Ann Surg Oncol* 2007;14:1285-87.
16. Poon JT, Law WL. Laparoscopic resection for rectal cancer: A review. *Ann Surg Oncol* 2009;16:3038-47.
17. Laurent C, Leblanc F, Gineste C, et al. Laparoscopic approach in surgical treatment of rectal cancer. *Br J Surg* 2007;94:1555-61.
18. Braga M, Frasson M, Vignali A, et al. Laparoscopic resection in rectal cancer patients: Outcome and cost-benefit analysis. *Dis Colon Rectum* 2007;50:464-71.
19. Pugliese R, Di LS, Sansonna F, et al. Laparoscopic resection for rectal adenocarcinoma. *Eur J Surg Oncol* 2009;35:497-503.
20. Chan AC, Poon JT, Fan JK, Lo SH, Law WL. Impact of conversion on the long-term outcome in laparoscopic resection of colorectal cancer. *Surg Endosc* 2008;22:2625-30.
21. Row D, Weiser MR. An update on laparoscopic resection for rectal cancer. *Cancer Control* 2010;17:16-24.
22. Aziz O, Constantinides V, Tekkis PP, Athanasiou T, Purkayastha S, Paraskeva P, Darzi AW, Heriot AG. Laparoscopic versus open surgery for rectal cancer: A meta-analysis. *Ann Surg Oncol* 2006;13:413-24.
23. Hughes ES, McDermott FT, Polglase AL, Johnson WR. Tumor recurrence in the abdominal wall scar tissue after large-bowel cancer surgery. *Dis Colon Rectum* 1983;26:571-72.
24. Reilly WT, Nelson H, Schroeder G, Wieand HS, Bolton J, O'Connell MJ. Wound recurrence following conventional treatment of colorectal cancer. A rare but perhaps underestimated problem. *Dis Colon Rectum* 1996;39:200-07.
25. Lujan J, Valero G, Hernandez Q, Sanchez A, Frutos MD, Parrilla P. Randomized clinical trial comparing laparoscopic and open surgery in patients with rectal cancer. *Br J Surg* 2009;96:982-89.
26. Heald RJ, Moran BJ, Ryall RD, Sexton R, MacFarlane JK. Rectal cancer: The Basingstoke experience of total mesorectal excision 1978-1997. *Arch Surg* 1998;133:894-99.
27. Milsom JW, de Oliveira O Jr, Trencheva KI, Pandey S, Lee SW, Sonoda T. Long-term outcomes of patients undergoing curative laparoscopic surgery for mid and low rectal cancer. *Dis Colon Rectum* 2009;52:1215-22.
28. Laurent C, Leblanc F, Wütrich P, Scheffler M, Rullier E. Laparoscopic versus open surgery for rectal cancer: Long-term oncologic results. *Ann Surg* 2009;250:54-61.
29. Zhou ZG, Hu M, Li Y, Lei WZ, Yu YY, Cheng Z, Li L, Shu Y, Wang TC. Laparoscopic versus open total mesorectal excision with anal sphincter preservation for low rectal cancer. *Surg Endosc* 2004;18:1211-15.
30. Jayne DG, Guillo PJ, Thorpe H, Quirke P, Copeland J, Smith AM, Heath RM, Brown JM. Randomized trial of laparoscopic assisted resection of colorectal carcinoma: 3-year results of the UK MRC CLASICC Trial Group. *J Clin Oncol* 2007;25:3061-68.
31. Lacy AM, Delgado S, Castells A, Prins HA, Arroyo V, Ibarzabal A, Pique JM. The long-term results of a randomized clinical trial of laparoscopy-assisted versus open surgery for colon cancer. *Ann Surg* 2008;248:1-7.
32. Law WL, Poon JT, Fan JK, Lo SH. Comparison of outcome of open and laparoscopic resection for stage II and stage III rectal cancer. *Ann Surg Oncol* 2009;16:1488-93.

# Laparoscopic Cholecystectomy: Fundus First or Fundus Last—Which and Why?

Motassim Barham

Member, Jordanian Association of Surgeons, Fellow, The Global Open University in Laparoscopic Surgery, Member, World Association of Laparoscopic Surgery, General and Laparoscopic Surgeon, Amman, Jordan

## ABSTRACT

Biliary tract injury represents the most serious and potentially life-threatening cholecystectomy complication. It is important to identify the structure of Calot's triangle during isolation of cystic duct to decrease this injury. Cystic duct isolation is the first dangerous technique in laparoscopic cholecystectomy. Retrograde (fundus first) dissection is frequently used in open cholecystectomy and although feasible in laparoscopic cholecystectomy, it has not been widely practiced as the antegrade conventional one. This article is presented to show that retrograde method appears to be a safe procedure and does not compromise the conventional one. It should be tried if obscure anatomy should occur without proceeding to irreparable hemorrhage or biliary injury. If these do occur, conversion is always a viable choice and should not be deemed a failure. However, retrograde dissection remains to have its error trap that is mostly leading to vasculobiliary injuries as well as the drawback of retained GB stones tendency.

**Abbreviations:** OC: Open cholecystectomy, LC: Laparoscopic cholecystectomy, RLC: Retrograde laparoscopic cholecystectomy, CLC: Conventional laparoscopic cholecystectomy, GB: Gallbladder, CBD: Common bile duct, CHD: Common hepatic duct, IOC: Intraoperative cholangiography, ERCP: Endoscopic retrograde cholangiopancreatography.

**Keywords:** Fundus-first, Fundus-down, Retrograde, Antegrade, Conventional, Laparoscopic cholecystectomy.

## INTRODUCTION

Iatrogenic biliary injuries have increased in incidence in the first decade with the introduction of LC. The incidence of major biliary injury is 0.25 to 0.74% and of minor injury is 0.28 to 1.7%.<sup>1</sup> Although a number of factors have been identified as high risk and a number of technical steps have been emphasized to avoid these injuries, the incidence of CBD injury has reached at least double the rate observed with OC. Cholecystectomy is the most frequently performed abdominal operation and the most serious complication associated with this procedure is accidental injury to CBD (0.3-0.4%).<sup>2</sup> Preventable technical errors have traditionally been thought to occur in one or more of the three situations:

- When the operator attempts to clip or ligate a bleeding cystic artery and CHD,
- When too much traction has been exerted on GB, so that CBD has tented up into an elbow which was either tied off with ligature or clipped,
- When anatomic anomalies were not recognized and the wrong structure is divided.

The use of the safest surgical technique (not the fastest) available, such as the critical view technique of Strasberg et al with the circumferential dissection of GB at the infundibulum to mimic RLC technique of the open era and not clipping or cutting any structure before unequivocal identification of the structure are mandatory components of the safe LC.<sup>3</sup>

The cause of the injury is not always clearly identifiable. In more than half of the cases, the injury occurs during

maneuvers to isolate the cystic duct or to free GB from CBD. These maneuvers may be more difficult and consequently more dangerous when there is significant inflammation as may be seen in acute cholecystitis or in case of obesity, cirrhosis with portal hypertension, previous surgery with peritoneal adhesions or anatomic variations of the hepatic pedicle. This article is presented to investigate the place of RLC showing the advantages and disadvantages and comparing it with CLC via many different parameters, especially biliary tract injury.

## AIMS AND OBJECTIVES

The aim of this study is to compare the effectiveness and safety among many other parameters assessed of RLC (up-down) vs CLC (down-up). The following parameters were evaluated:

- Patient selection methods
- Operative techniques
- Operative time
- Incidence of biliary injury
- Complications
- Rate of conversion
- Hospital stay and cost effectiveness
- Learning curve.

## MATERIALS AND METHODS

A literature search was performed by using Google and Online Springer Library facilities available at World

Laparoscopy Hospital (WLH). Selected papers were screened for further references. Criteria for selection of literature were methods of analysis (statistical or nonstatistical) and the institution where the study was done (specialized one for laparoscopic surgery). Priority was taken to select the newest comparative studies from well-known scientific highly specialized journals. Number of cases were not considered as a criteria since the procedure itself is not universally undertaken as CLC.

A prospective record of all LCs carried out by an experienced laparoscopic surgeon following his appointment in Bristol in 2004, was examined. RLC was resorted to when difficulties were encountered with exposure and/or dissection of Calot's triangle. A conclusion recommended that this technique does have a place and should be in the armamentarium of the laparoscopic surgeon.<sup>4</sup>

### PATIENT SELECTION METHODS

In the background of the comparative results of the study which was carried out at Nerima General Hospital, Tokyo, Japan,<sup>5</sup> RLC showed satisfactory results in terms of both safety and reliability in patients with severe inflammatory disease.

A prospective record of all LCs carried out in Bristol, in 2004, was examined.<sup>4</sup> RLC was resorted to when difficulties were encountered with exposure and/or dissection of Calot's triangle. RLC was attempted successfully in 11 out of 1,041 patients. The age ranged from 28 to 80 years (mean 61) and there were seven males. Indications were: fibrous, contracted GB (7), Mirizzi syndrome (2) and severe kyphosis (2). Histopathology showed chronic cholecystitis (7), xanthogranulomatous cholecystitis (3) and acute necrotizing cholecystitis (1).

### OPERATIVE TECHNIQUES

RLC procedure is as follows: First, the cystic duct and artery are exposed at the junction of the ampulla. The cystic duct is clipped, and the artery is divided. Removal of the GB is then started from the fundus to cystic duct downwards. After the GB has been dissected from the liver bed, the cystic duct is double-clipped and divided (Fig. 1).<sup>6</sup>

In conventional OC, the fundus-down approach is a more common procedure than the approach in the reverse direction. The easy and safe contrivance for LC with taping of the cystic duct temporarily with Teflon tape followed by resection of the GB with the fundus-down approach was performed. The tape was used for pulling down the cystic duct, and Calot's triangle was easily visible. The cystic duct was cut off only after the confirmation of no CBD injury.<sup>7</sup>

### OPERATIVE TIME

A study in which LC was carried out in 173 patients, RLC was performed in 81; the mean operating time was

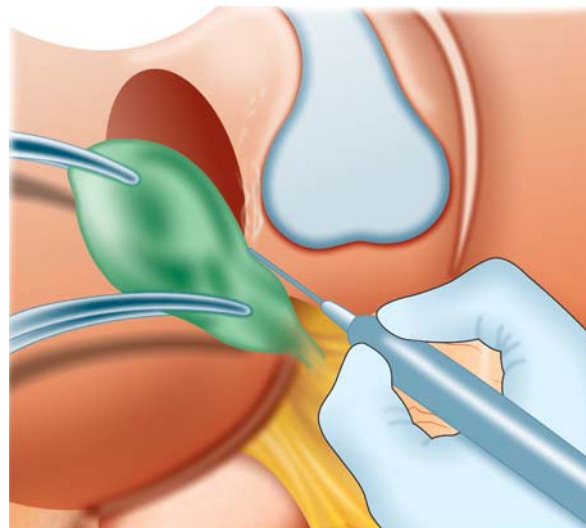


Fig. 1: RLC technique commencing from the fundus downwards (Ref. [www.themgcarshop.com/.../cholecystectomy.jpg](http://www.themgcarshop.com/.../cholecystectomy.jpg))

23 minutes shorter in RLC than in the usual LC because IOC was used much less often.<sup>6</sup>

Regarding the study contributed by Shing-Moo Huang and Kuang-Ming Hsiao,<sup>8</sup> the operation time was similar in the RLC and CLC groups.

In the study of Tuvieri M et al<sup>9</sup> the median operating time for the RLC was 65 minutes (range 40-170).

### INCIDENCE OF BILIARY INJURY

RLC approach provides better visualization of the GB, cystic duct and CBD with less chance of CBD injury, due to clear identification of the ductal system, without the need for IOC.<sup>6</sup>

The easy and safe contrivance for LC with taping of the cystic duct followed by resection of the GB with the fundus-down approach, performed for 500 patients in which the cystic duct was cut-off only after the confirmation of no CBD injury was reported.<sup>7</sup> In the conclusion, the authors memorial comment was: "Thanks to this tape procedure, there was no CBD injury in our 500 cases. We recommend this tape ligature of the cystic duct with the RLC approach to decrease the incidence of CBD injury".

Some surgeons use RLC techniques routinely when performing LC and claim to have lower incidence of CBD injury than that of conventional techniques. The reason was that it adopted an operative strategy similar to OC proceeding from the fundus towards the cystic duct and cystic artery. RLC seemed to lower the CBD injury rate from 6.5 to 0%.<sup>8</sup>

A case study was reported whereas an anomaly of the extrahepatic biliary system is found in which the CHD was found to enter the GB whereas the cystic duct drained the whole biliary system into the duodenum.<sup>10</sup> Rarity of this configuration led to transection of the CHD during LC in most cases. In this case study, dissection of the GB starting from the fundus will allow timely discovery of such an

anomaly. Maintenance of continuity between the CHD and cystic common biliary duct by preserving part of the GB permits easy repair on a T-tube.

About 250 biliary injuries in a study,<sup>11</sup> many biliary misidentification injuries occur due to error traps method that work well in most circumstances but which are apt to certain conditions. The most common cause of misidentification results from the 'infundibular technique' error trap. This problem is usually associated with severe inflammation which hides the cystic duct and obliterates Calot's triangle making the CHD appear to be part of GB wall. Another error trap—RLC has been associated with injuries in which the vascular component has been even more serious than the biliary one. These injuries result in hepatic infarction requiring liver resection, possibly including transplantation. As opposed to CLC error trap, the fundus-down error trap usually occurs at OC after conversion. Knowledge of these error traps and their avoidance can help to reduce the incidence of biliary injuries (Fig. 2).

The cystic duct may be hidden in some patients having LC, especially in the presence of inflammation. This may lead to the deceptive appearance of a false infundibulum that misleads the surgeon into identifying the CBD as the cystic duct. Biliary injury is more likely when cystic duct identification is made by relying solely on the appearance of the junction of the cystic duct with the infundibulum, and this technique should be abandoned.<sup>12</sup>

## COMPLICATIONS

A study in which LC was carried out in 173 patients, RLC was performed in 81; the result of the study reported that RLCs were performed without severe complications, either immediate or late.<sup>2</sup>

Around 129 consecutive LCs were carried out and cases of RLC and CLC in a severe inflammatory and

noninflammatory groups were comparatively evaluated. The incidences of major postoperative complications were 0% in RLC cases and 17% in CLC cases in the severe inflammatory group.<sup>5</sup>

In another study,<sup>8</sup> the complication rate was lower in RLC group patients (3% vs 22.6%). Complications included CBD injuries, urinary tract infection and wound infection in CLC group patients, but only wound infection in RLC group patients.

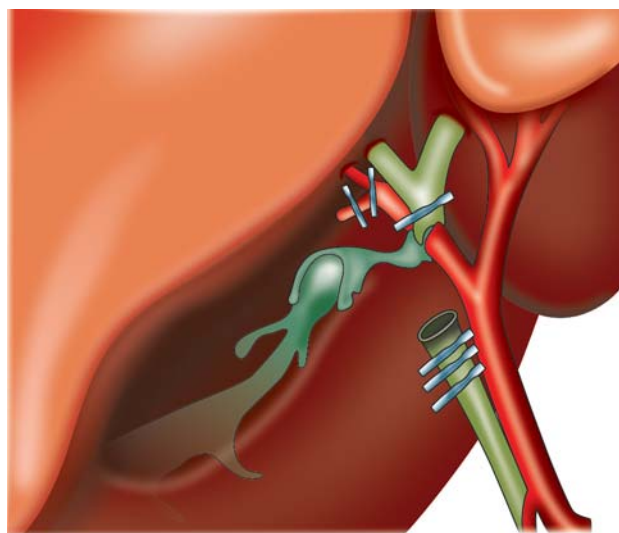
In conclusion of a study done by Tuveri M et al, RLC remains a safe option when dealing with patients with difficult anatomy at the Calot's triangle but its adoption needs a good surgical judgment.

Referring to another study,<sup>13</sup> RLC technique provides an alternative to CLC technique in patients at high risk for conversion or CBD injury. It reports the complication of a retained CBD stone after utilizing this technique. IOC was not performed due to the concern for causing CBD injury in a patient with significant periductal inflammation and no risk factors for CBD stones. Following discharge, the patient developed jaundice 3 days later and returned for evaluation. He required ERCP for removal of a CBD stone. It should now be recognized that there is a risk of displacing a gallstone into the CBD in utilizing RLC technique. This report highlights the importance of IOC when using this technique, even in patients considered to be at low risk for having CBD stones. If IOC is considered hazardous, then intraoperative ultrasound should be the modality of choice.

## RATE OF CONVERSION

Nerima General Hospital, Tokyo, Japan, study has a very clear answer in this field.<sup>5</sup> The rates of conversion to laparotomy were 0% in RLC cases and 33% in CLC cases in the severe inflammatory group.

Contracted GB is known to result from long-standing chronic cholecystitis, in which rigid fibrosis of areolar tissue makes cystic duct and cystic artery structures relatively more fragile and vulnerable to injury during Calot's triangle dissections. It might be the fibrotic rigidity nature of pericholecystic areolar tissue in patients with contracted GB that contributes to the high incidence of obscure anatomy in triangle of Calot, intraoperative hemorrhage and CBD injury encountered during CLC. From reports in a study,<sup>8</sup> contracted GB is the leading cause of conversion from LC to OC due to obscure anatomy or increased risk for intraoperative hemorrhage from GB bed. The conversion rate was markedly lower in the RLC group patients. The reasons for conversions, included CBD injuries, intraoperative hemorrhage and obscured anatomy. So, this is the cause for decreasing the rate of conversion in RLC group from 18.75 to 2.08%.<sup>14</sup>



**Fig. 2:** Most common error traps which occur during performance of CLC and RLC. (Ref. catalog.nucleusinc.com/imagescooked/1783W.jpg)

## HOSPITAL STAY AND COST EFFECTIVENESS

Mean of 2.2 days was the postoperative stay with no delayed sequela in a prospective study.<sup>4</sup> Regarding another study, RLC had shorter postoperative hospital stays by an average of 2 days when compared with CLC.<sup>8</sup>

## LEARNING CURVE

RLC can reduce the time of surgery and is an easier technique to perform. Therefore, it can be proposed as the standard procedure and not only be used for difficult LCs.<sup>15</sup>

## DISCUSSION

A great deal continues to be written about CBD injuries in LC, which serves to underscore the seriousness of the complication and the perception that it can and should be avoided. The current rate of major CBD injury in LC has stabilized at 0.1 to 0.6%, and series with no major CBD injuries have been reported; while many believe that the rate of major CBD injury in OC is lower than in LC, controversy remains. A host of factors has been associated with CBD injury, including surgeon experience, patient age, male sex and acute cholecystitis, though the effect that acute cholecystitis has on injury rates remains controversial. CBD injuries, which occur with LC, frequently involve complete disruption and excision of ducts and may be associated with hepatic vascular injuries. Since, major CBD injuries with LC are most frequently due to duct misidentification, techniques for prevention and/or recognition focus primarily on careful anatomic definition to ensure the 'critical view' prior to dividing any structures. The Society of American Gastrointestinal and Endoscopic Surgeons (SAGES) first offered guidelines for the clinical application of LC as a safe and effective treatment for most patients with symptomatic gallstones in May 1990. These guidelines have periodically been updated, and the last guidelines, in November 2002, expanded to include all laparoscopic biliary tract surgeries, keeping in mind the safety and effectiveness of the procedures. The CLC technique for dissection of GB from the liver bed as described in the guidelines is to start from the GB infundibulum and work superiorly using electrocautery to remove GB from the bed. The technique of RLC has also been advocated, particularly in cases with significant inflammation. The standard technique works well and, with no compelling data to use the alternative technique, the choice is left to the surgeon.<sup>16</sup>

LC from fundus downward is desirable when exposure of the cystic duct is difficult and hazardous. First, the cystic duct and artery are exposed and clipped, and the artery is divided. Then removal of the GB is started from fundus downward. After GB is dissected from the liver bed, the cystic duct is double clipped and divided. This approach

affords better visualization of the cystic duct and CBD with less chance of CBD injury. Many studies were reported without immediate or late complications.<sup>17</sup> The facility to retract the liver and carry out RLC extends techniques developed for OC into the laparoscopic arena. It offers the surgeon the safety and versatility during LC that it confers during OC.<sup>18</sup>

## CONCLUSIONS AND RECOMMENDATIONS

RLC appears to be a safe procedure and does not compromise the CLC method. After reviewing all data, however, I would like to recommend the following algorithm regarding laparoscopic management of GB diseases. Firstly, the surgeon should try CLC, as the technique is most familiar and comfortable to most surgeons. Secondly, if obscure anatomy should occur without proceeding to irreparable hemorrhage or CBD injury, the surgeon should resort to RLC on site. Usually, this will solve the problem. Thirdly, if hemorrhage or CBD injury do occur, conversion to OC is always a viable choice and should not be deemed a failure. However, RLC as CLC, remains to have its error trap that is mostly leading to vasculobiliary injuries as well as the drawback of retained GB stones tendency which mandates routine IOC.

## REFERENCES

1. Nuzzo G, et al. The risk of biliary ductal injury during LC. *J Chir (Paris)* Nov 2004;141(6):343-53.
2. Sváb J, et al. Prevention, diagnosis and treatment of iatrogenic lesions of biliary tract during LC. *Rozhl Chir* Apr 2005;84(4):176-81.
3. Richard M Vazquez. Common sense and CBD injury: CBD injury revisited *Surg Endosc* 2008;22:1743-45.
4. Kelly MD. Laparoscopic retrograde (fundus first) cholecystectomy. PMID: 20003333 (PubMed-indexed for MEDLINE) PMCID: PMC 2801662 Free PMC Article.
5. Uyama I, et al. Laparoscopic retrograde cholecystectomy (from fundus downward) facilitated by lifting the liver bed up to the diaphragm for inflammatory GB. *Surg Laparosc Endosc* Dec 1995;5(6):431-36.
6. Kato K, et al. A new technique for LC-RLC: An analysis of 81 cases. *Endoscopy* May 1996;28(4):356-59.
7. Ichihara T, et al. Tape ligature of cystic duct and fundus-down approach for safety LC: Outcome of 500 patients. *Hepato-gastroenterology* Mar-Apr 2004;51(56):362-64.
8. Shing-Moo Huang, et al. Overcoming the difficulties in laparoscopic management of contracted GB with gallstones: Possible role of fundus-down approach, *Surg Endosc*.
9. Tuveri M, et al. Limits and advantages of fundus-first LC: Lessons learned. *J Laparoendosc Adv Surg Tech A* Feb 2008;18(1):69-75.
10. Moshe Hashmonai, et al. An anomaly of the extrahepatic biliary System. *Arch Surg* 1995;130(6):673-75.
11. Steven M Strasberg. Error traps and vasculo-biliary injury in laparoscopic and OC, *Hepatobiliary Pancreat Surg* 2008;15:284-92.

12. Strasberg SM, et al. The “hidden cystic duct” syndrome and the infundibular technique of LC: The danger of the false infundibulum. *J Am Coll Surg* Dec 2000;191(6): 661-67.
13. Dolan JP, et al. Retained CBD stone as a consequence of a fundus-first LC. *J Laparoendosc Adv Surg Tech A* Jun 2005;15(3):318-21.
14. Gupta A, Agarwal PN, Kant R, Malik V. Evaluation of fundus-first LC. *JSLs* Jul-Sep 2004;8(3):255-58.
15. Neri V, et al. Antegrade dissection in LC, *JSLs* Apr-Jun 2007;11(2):225-28.
16. Wayne Overby D, et al. Sages guidelines for the clinical application of laparoscopic biliary tract surgery, *Surg Endosc* 2010;24:2368-86.
17. Kato K, et al. LC from fundus downward. *Surg Laparosc Endosc* Oct 1994;4(5):373-74.
18. Martin IG, et al. Fundus-first LC, *Surg Endosc* Feb 1995;9(2): 203-06.

# Reproductive Outcome following Hysteroscopic Adhesiolysis in Patients with Asherman's Syndrome

Fadare Oluwaseun O

Department of Obstetrics and Gynecology, Diff Hospital, 6 Udi Hills Street, Aso Drive, Abuja, Nigeria

## ABSTRACT

Asherman's syndrome is a clinical condition characterized by a spectrum of disorders ranging from amenorrhea to hypomenorrhea to normal menses. It is frequently associated with infertility or recurrent pregnancy loss. Hysteroscopic adhesiolysis with adjuvant measures is considered the gold standard of treatment. A number of studies have reported on the reproductive outcomes after treatment of Asherman's syndrome with varied results as these are difficult to assess because there is no universally agreed system of classification. Such outcome measures include resumption of normal menses, conception rate and pregnancy outcome. We review the current best evidence about treatment modalities as well as subsequent reproductive outcome for Asherman's syndrome.

**Conclusion:** Large prospective controlled studies are needed to determine the best diagnostic and treatment modalities for intrauterine adhesions.

**Keywords:** Asherman's syndrome (AS), Intrauterine adhesions (IUA), Uterine synechiae (US), Intrauterine synechiae (IUS), Hysteroscopic adhesiolysis, Amenorrhea, Infertility, Reproductive outcome.

## INTRODUCTION

Asherman's syndrome was first described by Heinrich Fritsch in 1894<sup>1</sup> but it was Joseph Asherman who first pointed out the frequency of the pathologic condition and described the symptoms of amenorrhea, infertility and dysmenorrhea following complicated delivery or abortion (Asherman, 1948).<sup>2</sup> The syndrome is also commonly referred to as intrauterine adhesion (IUA), although, attempts have often been made by some authors to differentiate Asherman's syndrome (where amenorrhea from complete obliteration of the uterine cavity is a cardinal symptom) from intrauterine adhesions (where there is varied menstrual flow patterns, ranging from eumenorrhea through hypomenorrhea to amenorrhea, occurring as a result of partial obstruction of uterine cavity),<sup>3,4</sup> this differentiation has not gained widespread popularity. Other common names given to this condition include intrauterine synechiae, uterine atresia, amenorrhea traumatica and endometrial sclerosis.

## OBJECTIVES

1. To assess the various types of hysteroscopic adhesiolysis and adjuvant treatment measures used in management of patients with Asherman's syndrome.
2. To assess the reproductive outcome (resumption of menses, conception rate, time interval to conceive as well as pregnancy outcome) in patients with Asherman's syndrome following hysteroscopic adhesiolysis.

## METHODOLOGY

### Materials

The study was carried out through a literature search using the information technology installations of the World Laparoscopy Hospital, Gurgaon, NCR Delhi. Standard stationary was also provided by the resource centre of the hospital.

**Time:** The study was carried out during a period of one week between 17 December 2010 and 24 December 2010.

### Data Collection

All the publications used in the current study were accessed from the electronic (virtual) library using the following search engines: Google, Cochrane library, SpringerLink, HighWire press, PubMed and other linked references. Publications used were searched for using the following key words: Asherman's syndrome, intrauterine adhesions, uterine synechiae, hysteroscopic adhesiolysis, amenorrhea, infertility, reproductive outcome.

## PREVALENCE

The true incidence of Asherman's syndrome is unknown as the clinical spectrum ranges from amenorrhea to menstrual disturbance to infertility. It is, however, known to be a relatively uncommon condition. The American Society for Reproductive Medicine (ASRM) Practice Committee educational bulletin published in 2006 estimates a frequency of 7% of secondary amenorrhea,<sup>5</sup> while it was found in 6.3% of subfertile population in Nigeria.<sup>6</sup> Schenker

and Margalioth<sup>7</sup> reviewed 90 articles, reporting on a total of 2981 cases of Asherman's syndrome in various countries; they found that the incidence was especially high in Israel (25.8%), Greece (15.3%) and South America (14.9%). The prevalence of adhesions varied geographically, and the discrepancies could be explained by several factors:

1. The degree of awareness of the clinicians.
2. The number of therapeutic and illegal abortions in different parts of the world.
3. the kind of instrument used for puerperal and postabortal evacuation.<sup>8</sup>
4. The incidence of genital tuberculosis and puerperal infection in different countries.
5. The criteria used for diagnosis of intrauterine adhesions.

## CLASSIFICATION

The need for objective evaluation of the extent of the adhesions, determining the most appropriate therapeutic regimen and predict the results of treatment, has made proper classification of the disease necessary.

Over time, a variety of classifications of the syndrome have been based on different diagnostic tools. According to their findings on hysterosalpingography (HSG), Toaff and Ballas<sup>9</sup> classified intrauterine adhesions into four groups, based on a semiquantitative evaluation. With the advent of hysteroscopy, various investigators have created a series of classifications<sup>10-12</sup> based on the extent of adhesions and the visualization of the ostia. However, none of these classifications took into account the various clinical presentations, especially with regard to the menstrual history. In 1988, the American Fertility Society developed an objective scoring system for classification of intrauterine adhesions that correlated the menstrual history with hysteroscopic and hysterosalpingographic findings (Table 1).<sup>13</sup> Conversely, the European Society of Hysteroscopy (ESH) and European Society of Gynecological Endoscopy (ESGE) adopted the classification developed at the Hysteroscopy Training Center in the Netherlands by Wamsteker (Table 2).<sup>14</sup> Both of these classification schemes appear to be more thorough, but they

**Table 1:** The American Fertility Society classification of intrauterine adhesions, 1988

Extent of cavity involved	< 1/3	1/3-2/3	> 2/3
	1	2	4
Type of adhesions	Filmy	Filmy and Dense	Dense
	1	2	4
Menstrual pattern	Normal	Hypomenorrhea	Amenorrhea
	0	2	4
Prognostic classification		HSG <sup>a</sup> score	Hysteroscopy score
Stage I (Mild)	1-4		
Stage II (Moderate)	5-8		
Stage III (Severe)	9-12		

Source: The American Fertility Society classifications of adnexal adhesions, distal tubal occlusion, tubal occlusion secondary to tubal ligation, tubal pregnancies, mullerian anomalies and intrauterine adhesions. Fertil Steril 1988;49:944-55: All adhesions should be considered dense.

**Table 2:** European Society of Gynecological Endoscopy (ESGE) classification of IUAs (1995 version)

Grade	
I	Extent of intrauterine adhesions <sup>a</sup> Thin or filmy adhesions Easily ruptured by hysteroscope sheath alone Cornual areas normal
II	Singular dense adhesion Connecting separate areas of the uterine cavity Visualization of both tubal ostia possible Cannot be ruptured by hysteroscope sheath alone
Ila	Occluding adhesions only in the region of the internal cervical os <sup>b</sup> Upper uterine cavity normal
III	Multiple dense adhesions Connecting separate areas of the uterine cavity Unilateral obliteration of ostial areas of the tubes
IV	Extensive dense adhesions with (partial) occlusion of the uterine cavity Both tubal ostial areas (partially) occluded
Va	Extensive endometrial scarring and fibrosis in combination with grade I or II adhesions With amenorrhea or pronounced hypomenorrhea
Vb	Extensive endometrial scarring and fibrosis in combination with grade III or IV adhesions <sup>b</sup> With amenorrhea

Source: Wamsteker 1997, Hysteroscopy Training Center, Spaarne Hospital, Haarlem, Netherlands.

a: From findings at hysteroscopy and hystero-graphy; b: Only to be classified during hysteroscopic treatment

are rather complex and difficult to use. More recently, an improved classification system has been developed that takes into account clinical presentations, hysteroscopic findings and past reproductive performance.<sup>15</sup> This scoring system is attractive because of its potential to predict reproductive outcome. None of these classification systems, however, have been validated by clinical studies, and no one has used them uniformly when reporting reproductive outcome after treatment of intrauterine adhesions. Thus, comparison among the different reports that include outcomes is difficult.

## ETIOLOGY

The etiology of Asherman's syndrome is not clear as the pathophysiology of the regeneration of the endometrial layers is not well understood. However, its causes can largely be grouped into:

1. Mechanical and iatrogenic complications with excessive local destruction beyond the basal layer of the endometrium into the 'compact zone' covering the myometrium. Examples include curettage for miscarriage, evacuation of retained products for incomplete miscarriages, manual removal of placenta, hysteroscopic resection of polyps or multiple submucous uterine fibroids, abdominal myomectomy with opening of the uterine cavity,<sup>16</sup> uterine artery embolization<sup>17</sup> and uterine septum resection.<sup>18</sup>
2. Pathophysiological disturbance, such as endometritis, complete miscarriage, septic abortion as well as uterine tuberculosis. Genital tuberculosis, which appears to be an important and common cause of Asherman's syndrome in India,<sup>19,20</sup> carries a rather poor prognosis with treatment.<sup>21</sup> Other causes include schistosomiasis,<sup>22</sup> Müllerian malformations, atrophy due to a long period of lactation<sup>23</sup> or menopause.<sup>24</sup>
3. Idiopathic cause when no apparent reason is found. The findings of Asherman's syndrome vary considerably from complete obliteration to minimal adhesions. There can also be filmy, fluffy adhesions or dense adhesions that are difficult to cut with hysteroscopic scissors. The extent of findings at hysteroscopy includes adhesion of the cavity ranging from filmy to severe, total atresia and cervicoisthmic adhesions. Adhesions in the cavity are the most common, whereas total atresia and cervicoisthmic adhesions are rare.<sup>20</sup> A subgroup of women with Asherman's syndrome due to uterine outlet obstruction from intrauterine or cervical adhesions was demonstrated to have substantially thinner albeit normal endometrium with very uncommon finding of hematometra.<sup>25</sup> The histologic appearance is variable and can be endometrial, myometrial or connective tissue. Most frequent are fibromuscular bands, sometimes lined with endometrium.<sup>26</sup> Endometrium obtained by

curettage at the time of treatment of adhesions was secretory in 80%, proliferative in 12%, atrophic in 5% and hyperplastic in 3%.<sup>20</sup> It appears that dense fibrous adhesions without glands carry the worst prognosis for patients in terms of both menses and fertility, as lack of evidence at pathophysiological level makes the choice of an effective treatment more difficult.

## DIAGNOSIS

Women with IUA seeking help from the gynecologists may present different clinical manifestations from menstrual disorder, dysmenorrhea to subfertility and pregnancy complications. In Schenker and Margalioth's study,<sup>7</sup> it was further reported that, among 165 pregnancies in women with untreated Asherman's syndrome, the rate of spontaneous miscarriage was 40%, preterm delivery was 23%, term delivery was 30%, placenta accreta was 13% and ectopic pregnancy was 12%. The pregnancy complication rates in this group of patients appeared to be high, although there was no proper control group.

The presence of IUA can be suspected, taking into account relevant information from a thorough personal patient history aimed to identify previous gynecological infections, pelvic inflammatory disease, iatrogenic correlated complications, obstetrical complications and history of pelvic tuberculosis. Other causes of amenorrhea and menstrual disturbances should be ruled out. Pregnancy is the most frequent cause of amenorrhea in this age group and should be assessed prior to any other work-up. Secondary amenorrhea of course is associated with many causes including polycystic ovarian syndrome, hypothalamic amenorrhea, ovarian failure and hyperprolactinemia. Asherman's syndrome should be considered in any patient with a recent history of trauma to the uterine cavity. Laboratory evaluation should consist of serum pregnancy test, complete blood count, and depending on the history and physical examination, follicle-stimulating hormone, thyroid stimulating hormone (TSH) and prolactin. In almost all cases of IUAs, the physical examination will be normal.

Hysteroscopy represents the gold standard for the diagnosis of IUA, since it offers a direct view of IUA. Comparatively, sonohysterography and hysterosalpingography have a sensitivity of 75% with positive predictive values of about 43 and 50%, respectively.<sup>27</sup> A recent study comparing hysterosalpingography with hysteroscopy found a sensitivity and specificity of 81.2 and 80.4% respectively, for hysterosalpingography.<sup>28</sup> Hysterosalpingography is limited by its high false-positive rate, which stems from its inability to distinguish between varying etiologies of filling defects; hysterosalpingography, therefore represents a good screening test for IUA with the added benefit of its ability to assess tubal patency.<sup>29</sup> Like hysterosalpingography, sonohysterography is also limited by its high false-positive

rate and is best utilized as a screening test for IUA.<sup>27,30</sup> Three-dimensional sonohysterography represents a newer diagnostic modality that can detect IUA and also estimates endometrial cavity volume, which is decreased in the setting of Asherman's syndrome.<sup>31,32</sup> Although, three-dimensional sonohysterography is quite sensitive and specific in the detection of intrauterine abnormalities, hysteroscopy is still 33% more sensitive in diagnosing IUA.<sup>32</sup> Transvaginal ultrasonography (TVS) can demonstrate hyperechogenic areas correlating with dense adhesions. TVS has high specificity but widely varying sensitivity. TVS that is performed on women of high risk for IUA formation can have very good accuracy and is very useful as screening test prior to hysteroscopy.<sup>33,34</sup> Preoperative endometrial thickness as determined by TVS appears to have prognostic value in cases of severe Asherman's syndrome.<sup>35</sup> Recent TVS studies demonstrated very thin endometrium and absence of hematometra in most women with uterine outlet occlusion by IUA.<sup>36</sup> Recently, it has been stated that saline infusion sonography (SIS) had a higher level of correlation with hysteroscopic findings than TVS.<sup>37,38</sup> SIS and HSG may have similar sensitivity with high false-positive rate.<sup>38,39</sup> Magnetic resonance imaging (MRI)<sup>40</sup> also represents a newer diagnostic modality for IUA, which is under evaluation as its limited application. The main advantage of MRI is its ability to image the uterine cavity above the adhesions and assess the endometrial remnants in the upper part of the uterine cavity, which may influence the decision and outcome of treatment, especially in those with uterine cavity or cervical canal obstruction that cannot be visualized by hysteroscopy. However, the MRI-signal characteristics of intrauterine adhesions have not been examined in detail; it is anticipated that adhesions would produce low signal intensity on T2 images.<sup>40</sup> Further prospective results to address these are awaited. The extent and location of IUA are best defined with hysteroscopy, and they can simultaneously be treated. In addition to diagnosis and treatment, hysteroscopy is required for the classification of IUA.

## TREATMENT OF ASHERMAN'S SYNDROME

Treatment of Asherman's syndrome aims at restoring the size and shape of the uterine cavity, preventing recurrence of the adhesion, promoting the repair and regeneration of the destroyed endometrium and restoring normal reproductive functions.

Thus, treatment modalities in this condition are described in the following sections:

### Expectant Management

In a study by Schenka and Margalioth,<sup>7</sup> 23 amenorrheic women were noted from the literature, who had not undergone any surgical intervention, of whom 18 regained regular menses after 1 to 7 years. For fertility outcome,

292 women in whom treatment was withheld, were collated, among whom 45.5% conceived spontaneously. The unpredictable outcome of this mode of treatment has made it very unpopular amongst patients.

### Blind Dilation and Curettage

Before the advent of hysteroscopy, Asherman's syndrome was treated by dilation and curettage of the uterus. It is not surprising that this method resulted in a high incidence of uterine perforation and had a low success rate. This method is now considered obsolete.

### Hysterotomy

Transfundal separation of the walls of endometrial cavity by hysterotomy has been described. In an analysis of 31 cases of hysterotomies compiled from a total of 12 reports,<sup>7</sup> 52% conceived and 25.8% had term deliveries. The procedure is, however, seldom performed nowadays except in very severe cases where the uterine cavity is completely obliterated. Reddy and Rock<sup>41</sup> had also reported their experience with this technique in three patients who had previous unsuccessful hysteroscopic resection of intrauterine adhesions. All three patients resumed normal menstruation after surgical treatment, with re-establishment of the uterine cavity and regeneration of the endometrium. However, this method of treatment should only be considered in the most extreme of situations, and patients should have been counseled with regard to the implications of a laparotomy, the potential risk of bleeding with hysterectomy and the risk of scar rupture during subsequent pregnancies.

### Hysteroscopic Adhesiolysis

Hysteroscopic surgery is now the treatment of choice for Asherman's syndrome because of its minimally invasive nature and it can be performed under direct vision. Adhesiolysis usually begins inferiorly and can be advanced cephalad until the uterine architecture has been normalized.<sup>20</sup> Sometimes, the mere touch of the endoscope can be sufficient to separate filmy columns of adhesions. In most cases, adhesiolysis may be performed with the help of the hysteroscopic scissors or other cutting modalities, such as laser or diathermy. In general, filmy and central adhesions should be divided first as these are more easily distinguished; marginal and dense adhesions are more difficult to identify, and division of these adhesions carries an increased risk of uterine perforation.

Hysteroscopic adhesiolysis using scissors or biopsy forceps<sup>42</sup> has the advantage that it permits dissection and avoids complications related to energy sources, and it possibly minimizes the destruction of endometrium. Surgery that uses energy sources either with the electrode or laser

vaporization system could provide effective and precise cutting as well as good hemostasis, but there is a theoretical possibility of further endometrial damage. Electrosurgery systems, such as a monopolar cutting needle, Versapoint bipolar have been used in treatment of intrauterine adhesions. Thermal damage of endometrium may be limited by using an electrode needle rather than a cutting loop because of the reduced exposure to the current. Several studies have reported successful outcomes of adhesiolysis by using electrosurgery, which suggests that with proper application significant damage is unlikely.<sup>43</sup>

Hysteroscopic surgery using laser vaporization, including Nd-YAG laser and KTP laser, have been reported by Newton et al<sup>44</sup> and Chapman and Chapman.<sup>45</sup> The depth of necrosis in the latter modality has been described as minimal, at about 1 to 2 mm.

In Cochrane database review of pain relief for outpatient hysteroscopy,<sup>46</sup> meta-analysis demonstrates a significant reduction in the mean pain score with the use of local anesthetic in comparison to placebo or no treatment during and within 30 minutes after hysteroscopy. However, the clinical significance of the results is limited as the reduction in mean pain scores is small. Subgroup analysis has demonstrated a further reduction in mean pain scores during and within 30 minutes after hysteroscopy in postmenopausal women.

### Methods of Guidance

Hysteroscopic division of intrauterine adhesions may be technically difficult, especially if the adhesions are dense. It carries a significant risk of perforation of uterus, especially during the dilatation of the cervical channel and introduction of the hysteroscope. The introduction of the dilator and hysteroscope must be guided carefully by one of the methods described here to avoid perforation because perforation at this early stage would preclude satisfactory completion of the hysteroscopy. The efficiency and safety of hysteroscopic surgery for Asherman's syndrome may be improved if the procedure is guided by one of the following methods:

**Laparoscopy:** Laparoscopy is a common method used to monitor hysteroscopic adhesiolysis. Some investigators have performed hysteroscopic surgery under concomitant laparoscopic control to prevent perforation of the uterus.<sup>43</sup> This is of particular importance if the adhesions are dense. Lateral perforation of the uterus may cause significant bleeding, compared with central perforations. When the uterine wall becomes unduly thin, it will permit transmission of light across the uterine wall, and there will be a bulge over the remaining serosal layer, which signifies that further hysteroscopic surgery must immediately stop. However, with laparoscopic guidance, it is often too late to prevent the perforation. Nevertheless,

it has the advantage of detecting the perforation immediately, preventing any further trauma to pelvic organs. Laparoscopy also provides an opportunity to inspect the pelvis, to diagnose and treat any concurrent pathology, such as endometriosis or adhesions.

**Fluoroscopic control:** This technique provides an intraoperative fluoroscopic view of pockets of endometrium behind an otherwise blind-ending endocervical canal in women with severe Asherman's syndrome.<sup>47</sup>

**Gynecoradiologic uterine resection (GUR):** Karande et al<sup>48</sup> reported the use of a special catheter inserted into the uterine cavity through the cervix with a balloon attached to its tip. Radiopaque dye was injected through a side channel of the catheter to delineate the uterine cavity with its adhesions, and hysteroscopic scissors were introduced through a central channel of the catheter to divide the adhesions. The study, however, had a small sample size and needs further evaluation. The main disadvantage of this procedure relates to radiation exposure.

**Transabdominal ultrasound guidance:** Transabdominal ultrasound guidance has been increasingly used to replace laparoscopic guidance during hysteroscopic division of intrauterine adhesions, especially in women with severe intrauterine adhesions. When there are severe adhesions in the uterine cavity, it may be very difficult to identify the cavity without ultrasound. Our opinion is that transabdominal ultrasonography provides efficient monitoring of the hysteroscopic procedure and guiding the scope towards the uterine cavity even when the adhesions may have completely or almost completely obliterated the uterine cavity. It can significantly decrease the risk of perforation of uterus, especially during the procedure of dilatation of cervical channel. Moreover, it is a nontraumatic, readily available technique. Several newer innovative surgical procedures have been described for women with severe intrauterine adhesions albeit need large studies to evaluate them better. They include:

1. Transcervical adhesiolysis after use of laminaria tent.<sup>49</sup>
2. Conversion of blind hysteroscopic procedure to a septum division.<sup>50</sup>
3. Myometrial scoring technique.<sup>51</sup>
4. Pressure lavage under guidance;<sup>52</sup> a novel technique which may be good for women with mild intrauterine adhesions.

### Complications During Hysteroscopic Adhesiolysis Procedures

Complications during the adhesiolysis procedure include uterine perforation, hemorrhage and pelvic infection. Uterine perforation occurred in about 2% of all cases reported. However, the rate was up to 9% in those with severe adhesions. The incidence of perforation can be reduced by ultrasound guidance.<sup>53</sup> Hemorrhage is less commonly

reported; however, it is unclear whether hemorrhage is a less common occurrence or whether it is under-reported by various studies.

### *Prevention of Recurrence of Adhesion*

Studies have shown a high rate of reformation of intrauterine adhesions (3.1 to 23.5%), especially severe adhesions (20 to 62.5%). Thus, prevention of reformation of adhesions after surgery is essential to successful treatment. Various methods have been used to achieve this aim.

*Intrauterine contraceptive devices:* The insertion of an intrauterine device (IUD) has been advocated by many studies as an effective, widely used method to prevent adhesion reformation.<sup>54</sup> Postoperative use of an IUD keeps the raw, dissected surfaces separated during the initial healing phase and may reduce the chances that they will readhere to one another. In a literature review, March<sup>55</sup> discussed the use of IUDs and concluded that T-shaped IUDs may have too small surface area to prevent adhesion reformation, and that IUDs containing copper may induce an excessive inflammatory reaction. Therefore, their use is not advised in patients who have had intrauterine adhesions. The loop IUD is considered the best choice for the prevention of reformation of intrauterine adhesions,<sup>55</sup> although it is no longer available in many countries, including Nigeria. Presently, there have been no randomized controlled trials to confirm the usefulness of IUDs in preventing adhesion reformation after hysteroscopic lysis of intrauterine adhesions. The introduction of an IUD may also carry a small risk of perforation of the uterus.

*Foley catheter:* Several studies have reported on the use of a Foley catheter introduced into the uterine cavity with an inflated balloon for several days after lysis of adhesions to prevent recurrence. The use of balloon to prevent adhesion formation after adhesiolysis maintains the freshly separated uterine cavity by separating the opposing uterine walls. In 2003, Orhue et al<sup>6</sup> demonstrated that the Foley catheter was a safer, more effective method for preventing reformation of intrauterine adhesions after adhesiolysis. Furthermore, in a prospective controlled study, Amer et al<sup>56</sup> assessed the efficacy of an intrauterine balloon in preventing intrauterine adhesions after operative hysteroscopy. The investigators concluded that its application after operative hysteroscopy is of great value in preventing intrauterine adhesions. Amer and Abd-El-Maeboud<sup>57</sup> had tried amnion grafts after hysteroscopic lysis of intrauterine adhesions. In a pilot study, involving 25 patients with moderate or severe intrauterine adhesions, hysteroscopic adhesiolysis was followed by intrauterine application of a fresh amnion graft over an inflated Foley catheter balloon for 2 weeks. Second-look hysteroscopy revealed adhesion reformation in 48% of the patients who

had initial severe adhesions, but all had minimal adhesions. Drawbacks of this technique include the risk of ascending vaginal infection from the catheter's stem passing through the cervix into the vagina. The overinflated balloon may also increase pressure on the uterine walls, which may result in decreased blood flow to uterine walls with potential effects on endometrial regeneration. In addition, this method can produce significant discomfort for the patient. Randomized comparative studies are needed to validate this method's benefits, including the reproductive outcomes.

*Hyaluronic acid (HA):* Recently, hyaluronic acid, a natural component of the extracellular matrix, the vitreous humor and synovial fluid of the joint, has been proposed as a barrier agent to prevent adhesion development after abdominal and pelvic surgery.<sup>58</sup> The antiadhesive effects depend on the preparation's molecular weight as well as its concentration.<sup>59</sup> Investigators<sup>60</sup> have studied intrauterine application of modified hyaluronic acid (HA), including Seprafilm (Genzyme Corporation, Cambridge, MA) and auto-crosslinked HA (ACP) gel (Hyalobarriergel; Baxter, Pisa, Italy), to reduce the intrauterine adhesions after adhesiolysis. Seprafilm, a bioresorbable membrane formulated from chemically modified HA (sodium hyaluronate) and carboxymethyl cellulose, has been shown to significantly reduce intrauterine adhesions. Seprafilm turns into a hydrophilic gel approximately 24 hours after placement and provides a protective coating around traumatized tissues for upto 7 days during re-epithelization. Tsapanos et al<sup>60</sup> reported on a randomized, controlled trial to evaluate the safety and efficacy of Seprafilm in preventing and reducing postoperative endometrial synechiae formation after suction evacuation or curettage for incomplete, missed and recurrent abortion. In the Seprafilm-treated group, 10% developed intrauterine adhesions; whereas in the control group, 50% developed intrauterine adhesions.

*Hormone treatment:* Many gynecologists do use estrogen therapy after hysteroscopic lysis of intrauterine adhesions but its use has not been universally accepted as there has been no objective evidence based on randomized, controlled trials to confirm the efficacy of estrogen treatment on the reduction of reformation of intrauterine adhesions.

## **OUTCOMES OF TREATMENT**

Surgical success can be judged by the restoration of normal anatomy in the uterine cavity. The rate of successful anatomic restoration in a first procedure has been reported to range from 57.8 to 97.5%.<sup>61</sup> However, even when the uterine cavity has been restored anatomically, the extent of endometrial fibrosis will determine the reproductive outcome. Hence, the restoration of both uterine anatomy and the function of the endometrium are equally important.

Adhesion reformation has been a major limiting step to the success of the operation. The reformation of intrauterine adhesions appears to be directly related to the severity of the adhesions. It has been reported that the recurrence rate for intrauterine adhesions ranges from 3.1 to 23.5% among all cases of intrauterine adhesions and from 20 to 62.5% in those with severe adhesions. Repeat surgery for those who have adhesion reformation may be worthwhile as there have been case reports of conception and delivery after repeated surgical adhesiolysis.<sup>50</sup>

Another outcome measure of the procedure is restoration of normal menses. The return of menstruation has been reported to range from 52.4 to 88.2%. From five available studies; we can conclude that, of 625 women who underwent surgical treatment of Asherman's syndrome, 84.5% regained normal menstruation.

Finally, in women who present with infertility or recurrent pregnancy loss, the outcome may be measured in terms of pregnancy rate and live birth rate. Pace et al<sup>61</sup> reported that in women with Asherman's syndrome, pregnancy rate varied from 28.7% before surgery to 53.6% after hysteroscopic treatment. In a study of women with two or more previous unsuccessful pregnancies,<sup>62</sup> the operative success as measured by live birth rate improved from 18.3% preoperatively to 68.6% postoperatively. In the literature, the pregnancy rate after hysteroscopic lysis of intrauterine adhesions in women who wanted to have a child has been about 74%, which is much higher than found in untreated women (46%). The pregnancy rate after treatment in women with infertility is about 45.6%; the successful pregnancy rate after treatment in severe cases is reported to be consistently lower at 33%. For women with previous pregnancy wastage, both the pregnancy rate and the live birth rate after treatment are reasonably high—89.6 and 77.0% respectively.

Women who conceive after treatment of Asherman's syndrome still have a high risk of pregnancy complications, including spontaneous abortion, premature delivery, abnormal placentation, intrauterine growth restriction (IUGR) and uterine rupture during pregnancy or delivery.

Everett<sup>63</sup> reported that, in the general population, in 550 women who conceived, bleeding occurred before the 20th week in 117 patients (117 out of 550; 21%), and 67 pregnancies (67 out of 550; 12%) ended in miscarriage. The spontaneous miscarriage rate after treatment of intrauterine adhesions was around 20% (94 out of 477). It is unclear whether this represents an increase in the risk of early miscarriage after treatment of Asherman's syndrome, as the likelihood of miscarriage in the general population (about 15 to 20%) is rather close to this figure. Continued collection of data is required to determine if the miscarriage rate after treatment of Asherman's syndrome is increased. This increased rate could be related to the

presence of fibrosed endometrium, which impairs successful implantation. Thus, pregnancies in women with a history of Asherman's syndrome should be considered to be high risk. Careful monitoring during the antenatal period, especially the third trimester, should be undertaken. Also, the importance of preventing Asherman's syndrome cannot be overemphasized. Such preventive measures include the need to avoid postpartum or postabortal curettage; the need for gentle curettage, if surgical evacuation is needed; and preference for medical management of miscarriages.

## CONCLUSION

Asherman's syndrome is a worldwide disease and hysteroscopy remains the method of choice in the investigation and treatment of the condition. The management of moderate to severe disease remains a challenge, while the prognosis of severe disease remains poor. In those who succeed in achieving pregnancy after treatment of the condition, careful surveillance of the pregnancy is essential because a number of obstetrics complications may occur. Large prospective controlled studies are needed to determine the best diagnostic and treatment modalities for intrauterine adhesions.

## REFERENCES

1. Fritsch H. Ein Fall von volligem Schwund der Gebarmutterhohle nach Auskratzung. *Zentralbl Gynaekol* 1894;18:1337-42.
2. Asherman JG. Amenorrhoea Traumatica (Atretica). *J Obstet Gynaecol Br Emp* 1948;55:23-30.
3. Asherman JG. Traumatic intrauterine adhesions. *BJOG* 1950;57:892-96.
4. Taylor PJ, Cummings DC, Hill PJ. Significance of intrauterine adhesions detected hysteroscopically in eumenorrhoeic infertile women and the role of antecedent curettage in their formation. *Am J Obstet Gynecol* 1981;139:239-42.
5. Practice Committee of the American Society for Reproductive Medicine. Current evaluation of amenorrhea. *Fertil Steril* 2006;86:S148-55.
6. AAE Orhue, ME Aziken, JO Igbehof. A comparison of two adjunctive treatments for intrauterine adhesions following lysis. *International Journal of Gynecology and Obstetrics* 2003;82:49-56.
7. Schenker JG, Margalioth EJ. Intrauterine adhesions: An updated appraisal. *Fertil Steril* 1982;37:593-610.
8. Chapman K, Chapman R. Asherman's syndrome: A review of the literature, and a husband and wife's 20-year world-wide experience. *J R Soc Med* 1990;83:576-80.
9. Toaff R, Ballas S. Traumatic hypomenorrhea-amenorrhea (Asherman's syndrome). *Fertil Steril* 1978;30:379-87.
10. March CM, Israel R, March AD. Hysteroscopic management of intrauterine adhesions. *Am J Obstet Gynecol* 1978;130:653-57.
11. Valle RF, Sciarra JJ. Intrauterine adhesions: Hysteroscopic diagnosis, classification, treatment, and reproductive outcome. *Am J Obstet Gynecol* 1988;158:1459-70.
12. Donnez J, Nisolle M. Hysteroscopic lysis of intrauterine adhesions (Asherman's syndrome). In: Donnez J (Ed). *Atlas of laser operative laparoscopy and hysteroscopy*. New York: Press Parthenon 1994:305-22.

13. The American Fertility Society classifications of adnexal adhesions, distal tubal occlusion, tubal occlusion secondary to tubal ligation, tubal pregnancies, Mullerian anomalies and intrauterine adhesions. *Fertil Steril* 1988;49:944-55.
14. Wamsteker K, De Block S. Diagnostic hysteroscopy: Technique and documentation. In: Sutton C, Diamond M (Eds). *Endoscopic surgery for gynecologists*. London: WB Saunders 1998;511-24.
15. Nasr AL, Al-Inany HG, Thabet SM, Aboulghar M. A clinicohysteroscopic scoring system of intrauterine adhesions. *Gynecol Obstet Invest* 2000;50:178-81.
16. Pistofidis GA, Dimitropoulos K, Mastrominas M. Comparison of operative and fertility outcome between groups of women with intrauterine adhesions after adhesiolysis. *J Am Assoc Gynecol Laparosc* 1996;3(suppl 4):S40.
17. Davies C, Gibson M, Holt EM, Torrie EP. Amenorrhoea secondary to endometrial ablation and Asherman's syndrome following uterine artery embolization. *Clin Radiol* 2002;57(4):317-18.
18. Taylor PJ, Cummings DC, Hill PJ. Significance of intrauterine adhesions detected hysteroscopically in eumenorrhoeic infertile women and the role of antecedent curettage in their formation. *Am J Obstet Gynecol* 1981;139:239-42.
19. Gupta N, Sharma JB, Mittal S, Singh N, Misra R, Kukreja M. Genital tuberculosis in Indian infertility patients. *Int J Gynecol Obstet* 2007;97(2):135-38.
20. Al-Inany H. Intrauterine adhesions: An update. *Acta Obstet Gynecol Scand* 2001;80(11):986-93.
21. Bukulmez O, Yarali H, Gurgan T. Total corporal synechiae due to tuberculosis carry a very poor prognosis following hysteroscopic synechialysis. *Hum Reprod* 1999;14:1960-61.
22. Krolkowski A, Janowski K, Larsen JV. Asherman syndrome caused by schistosomiasis. *Obstet Gynecol* 1995;85:898-99.
23. Westendorp ICD, Ankum WWM, Nol BWJ, Vonk J. Prevalence of Asherman's syndrome after secondary removal of placental remnants or a repeat curettage for incomplete abortion. *Hum Reprod* 1998;13(12):3337-50.
24. Panayotidis C, Ranjit R. An unusual case of Asherman's syndrome in a virgin menopausal woman. *Gynecol Surg* 2004;1(1):37-39.
25. Sin Ting Lo, Philippa Ramsay, Roger Pierson, Frank Manconi, Malcolm G Munro, Ian S Fraser. Endometrial thickness measured by ultrasound scan in women with uterine outlet obstruction due to intrauterine or upper cervical adhesions. *Human Reproduction* 2008;23(2):306-09.
26. Dmowski WP, Greenblatt RB. Asherman's syndrome and risk of placenta accreta. *Obstet Gynecol* 1969;34:288-99.
27. Soares SR, Barbosa dos Reis MM, Camargos AF. Diagnostic accuracy of sonohysterography, transvaginal sonography, and hysterosalpingography in patients with uterine cavity diseases. *Fertil Steril* 2000;72:406-11.
28. Roma Dalfo A, Ubeda B, Ubeda A, et al. Diagnostic value of hysterosalpingography in the detection of intrauterine abnormalities: A comparison with hysteroscopy. *Am J Roentgenol* 2004;183:1405-09.
29. Munro MG. Gynecologic endoscopy. In: Berek J, Adashi E, Hillard P (Eds). *Novak's gynecology*. New York: Lippincott Williams and Williams 1996;677-725.
30. Salle B, Gaucherand P, de Saint Hilaire P, et al. Transvaginal sonohysterographic evaluation of intrauterine adhesions. *J Clin Ultrasound* 1999;27:131-34.
31. Weinraub Z, Maymon R, Shulman A, et al. Three-dimensional saline contrast hysterosonography and surface rendering of uterine cavity abnormalities. *Ultrasound Obstet Gynecol* 1996;8:277-82.
32. Makris N, Kalmantis K, Skartados N, et al. Three-dimensional hysterosonography versus hysteroscopy for the detection of intracavitary uterine abnormalities. *Int J Gynecol Obstet* 2007;97:6-9.
33. Fedele L, Bianchi S, Dorta M, Vignali M. Intrauterine adhesions: Detection with transvaginal ultrasound. *Genitourinary Radiology* 1996;199:757-59.
34. Sohail S. Uterine sonomorphology of Asherman syndrome on transvaginal ultrasound. *Pak J Med Sci* 2005;21(4):451-54.
35. Schlaff WD, Hurst BS. Preoperative sonographic measurement of endometrial pattern predicts outcome of surgical repair in patients with severe Asherman's syndrome. *Fertil Steril* 1995;63:410-13.
36. Lo S, Ramsay P, Pierson R, Manconi F, Munro M, Fraser I. Endometrial thickness measured by ultrasound scan in women with uterine outlet obstruction due to intrauterine or upper cervical adhesions. *Hum Reprod* 2008;23(2):306-09.
37. Guimaraes Filho HA, Mattar R, Araujo Junior E, Pires CR, Moron AF. Diagnosis of uterine synechiae in patients with recurrent miscarriages: Contribution of transvaginal hysterosonography. *Rev Assoc Med Bras* 2006;52(5):308-11.
38. Salle B, Gaucherand P, de Saint Hilaire P, Rudigoz RC. Transvaginal sonohysterographic evaluation of intrauterine adhesions. *J Clin Ultrasound* 1999;27(3):131-34.
39. Soares SR, Barbosa dos Reis MM, Camargos AF. Diagnostic accuracy of sonohysterography, transvaginal sonography, and hysterosalpingography in patients with uterine cavity diseases. *Fertil Steril* 2000;73(2):406-11.
40. Bacelar AC, Wilcock D, Powell M, et al. The value of MRI in the assessment of traumatic intrauterine adhesions (Asherman's syndrome). *Clin Radiol* 1995;50:80-83.
41. Reddy S, Rock JA. Surgical management of complete obliteration of the endometrial cavity. *Fertil Steril* 1997;67:172-74.
42. Fedele L, Vercellini P, Viezzoli T, Ricciardiello O, Zamberletti D. Intrauterine adhesions: Current diagnostic and therapeutic trends. *Acta Eur Fertil* 1986;17:31-37.
43. Cararach M, Penella J, Ubeda A, Labastida R. Hysteroscopic incision of the septate uterus: Scissors versus resectoscope. *Hum Reprod* 1994;9:87-89.
44. Newton JR, MacKenzie WE, Emens MJ, Jordan JA. Division of uterine adhesions (Asherman's syndrome) with the Nd-YAG laser. *Br J Obstet Gynaecol* 1989;96:102-04.
45. Chapman R, Chapman K. The value of two stage laser treatment for severe Asherman's syndrome. *Br J Obstet Gynaecol* 1996;103:1256-58.
46. Ahmad G, O'Flynn H, Attarbashi S, Duffy JMN, Watson A. Pain relief for outpatient hysteroscopy. *Cochrane Database of Systematic Reviews* 2010, Issue 11. Art. No.: CD007710. DOI: 10.1002/14651858.CD007710.pub2.
47. Broome JD, Vancaillie TG. Fluoroscopically guided hysteroscopic division of adhesions in severe Asherman's syndrome. *Obstet Gynecol* 1999;93:1041-43.
48. Karande V, Levran S, Hoxsey R, Rinehart J, Gleicher N. Lysis of intrauterine adhesions using gynecoradiologic techniques. *Fertil Steril* 1997;68:658-62.
49. Chen FP, Soong YK, Hui YL. Successful treatment of severe uterine synechiae with transcervical resectoscopy combined with laminaria tent. *Hum Reprod* 1997;12:943-47.
50. McComb PF, Wagner BL. Simplified therapy for Asherman's syndrome. *Fertil Steril* 1997;68:1047-50.
51. Protopapas A, Shushan A, Magos A. Myometrial scoring: A new technique for the management of severe Asherman's syndrome. *Fertil Steril* 1998;69:860-64.
52. Coccia ME, Becattini C, Bracco GL, Pampaloni F, Bargelli G, Scarselli G. Pressure lavage under ultrasound guidance: A new

- approach for outpatient treatment of intrauterine adhesions. *Fertil Steril* 2001;75:601-06.
53. Coccia ME, Becattini C, Bracco GL, Bargelli G, Scarselli G. Intraoperative ultrasound guidance for operative hysteroscopy: A prospective study. *J Reprod Med* 2000;45:413-18.
  54. Polishuk WZ, Weinstein D. The Soichet intrauterine device in the treatment of intrauterine adhesions. *Acta Eur Fertil* 1976;7: 215-18.
  55. March CM. Intrauterine adhesions. *Obstet Gynecol Clin North Am* 1995;22:491-505.
  56. Amer MI, El Nadim A, Hassanein K. The role of intrauterine balloon after operative hysteroscopy in the prevention of intrauterine adhesion: A prospective controlled study. *MEFS J* 2005;10:125-29.
  57. Amer MI, Abd-El-Maeboud KH. Amnion graft following hysteroscopic lysis of intrauterine adhesions. *J Obstet Gynaecol Res* 2006;32:559-66.
  58. Burns JW, Skinner K, Colt J, Sheidlin A, Bronson R, Yaacobi Y, Goldberg EP. Prevention of tissue injury and postsurgical adhesions by precoating tissues with hyaluronic acid solutions. *J Surg Res* 1995;59:644-52.
  59. De Iaco PA, Stefanetti M, Pressato D, Piana S, Dona M, Pavesio A, Bovicelli L. A novel hyaluronan-based gel in laparoscopic adhesion prevention: Preclinical evaluation in an animal model. *Fertil Steril* 1998;69:318-23.
  60. Tsapanos VS, Stathopoulou LP, Papathanassopoulou VS, Tzingounis VA. The role of Seprafilm bioresorbable membrane in the prevention and therapy of endometrial synechiae. *J Biomed Mater Res* 2002;63:10-14.
  61. Pace S, Stentella P, Catania R, Palazzetti PL, Frega A. Endoscopic treatment of intrauterine adhesions. *Clin Exp Obstet Gynecol* 2003;30:26-28.
  62. Katz Z, Ben-Arie A, Lurie S, Manor M, Insler V. Reproductive outcome following hysteroscopic adhesiolysis in Asherman's syndrome. *Int J Fertil Menopausal Stud* 1996;41:462-65.
  63. Everett C. Incidence and outcome of bleeding before the 20th week of pregnancy: Prospective study from general practice. *BMJ* 1997;315:32-34.

# Cholecystoduodenal Fistula is not the Contraindication for Laparoscopic Surgery

Sanjeev Kumar Sareen

Director and Surgical Specialist, Sareen Hospital, Amritsar, Punjab, India

## ABSTRACT

Cholecystoduodenal fistula is the complication of gallstone and it is difficult to diagnose this condition preoperatively, which is the reason for conversion of laparoscopic to open cholecystectomy. Earlier laparoscopic cholecystectomy was considered unsuitable for such difficult bilioenteric procedures. The laparoscope is fast becoming an important tool for the general surgeon, it make us capable of handling the unforeseen events. This review article is to demonstrate the cholecystoduodenal fistula is not the contraindication for the laparoscopy, now it can be performed without higher rate of risk with the innovation of better modalities available.<sup>5</sup> The goal of study is to introduce the proper awareness in laparoscopic surgeons regarding the feasibility and safety of the procedure.

**Keywords:** Cholecystoduodenal fistula (CCDF), Cholelithiasis, Gallstone ileus, Safe laparoscopic repair.

## INTRODUCTION

Acute cholecystitis, acute pancreatitis, spontaneous gallbladder perforation, pericholecystic abscess, cholecystoduodenal fistula, gallstone ileus and intestinal obstruction are the complications of the gallstone disease.<sup>21</sup> Despite advanced perioperative care, morbidity and mortality are still high in such cases because of (i) geriatric age group, with (ii) multiple co-morbid conditions, (iii) prolonged undiagnosed cholecystoduodenal fistula and (iv) gallstone ileus, (v) fluid and electrolyte imbalance and (vi) late stage hospitalization.<sup>4</sup> Untreated cholecystoduodenal fistula will lead to passage of the gallstones in the second part duodenum and will require enterotomy as emergency along with major biliary surgery to overcome the complications caused by bowel occlusion. One stage laparoscopic surgery can be performed in such abdominal emergency conditions which include removal of impacted stones, repair of fistula and cholecystectomy. One stage surgery is good option; it can be done to avoid the future recurrence,<sup>1</sup> later biliary complications and reoperations in elderly old patients who usually have coexisting medical diseases, to prevent the morbidity and mortality.<sup>3,4,17</sup> CCDF will affect the duodenal bulb and cause peptic duodenal perforation leading to upper gastrointestinal (GI) bleeding.<sup>6</sup>

## AIMS AND OBJECTIVES

The cholecystoduodenal fistula is the rare complication of the cholelithiasis. The aim of the review study is to evaluate the safety and risk of complications when laparoscopic approach is applied in the cases of cholecystoduodenal fistula.

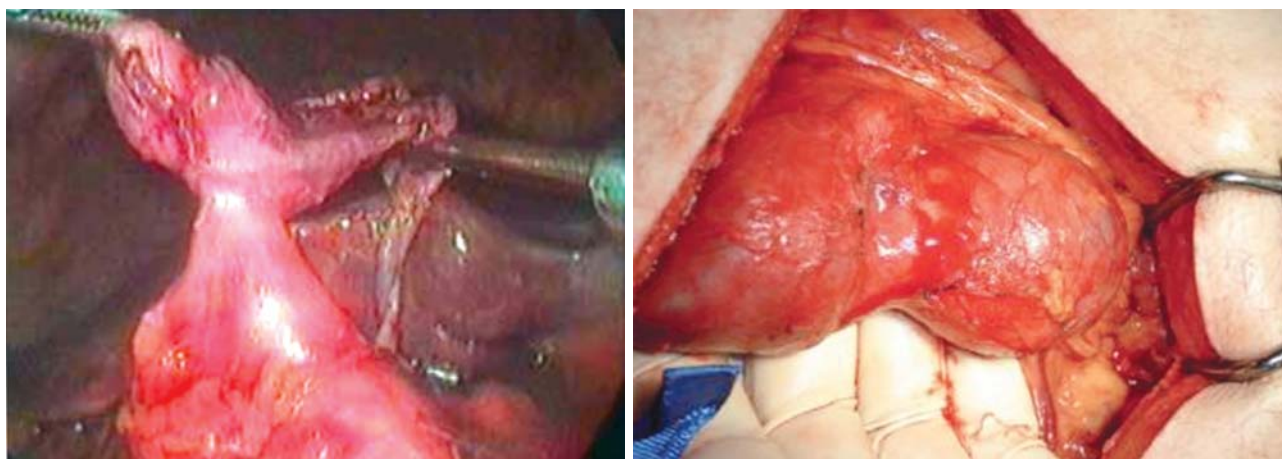
## MATERIALS AND METHODS

We analyzed review of many multicenter studies about laparoscopic cholecystoduodenal repair and laparoscopic cholecystectomy. A literature search is performed using different search engines, such as Google, Yahoo, SpringerLink, HighWire press, surgical endoscopy. Total 21 references from various international and national journals are selected for this review article. The authors of the various journal publications at different times collected the data commonly on basis of patient's age, sex, preoperative diagnoses, operative methods, morbidity and management for their studies. The criteria for selection were to reduce the risk of postoperative complications.

## CHOLECYSTODUODENAL FISTULA

The communication between the gallbladder and duodenum secondary to severe cholecystitis and cholelithiasis may lead to perforation and abscess formation (Fig. 1). The gallstones can erode into the second part of duodenum and bigger stones will cause gallstones ileus. Gallstone ileus is not the common cause of intestinal obstruction and was first described by Bartholin in 1654.

Cholecystoenteric fistulas are a rare complication of gallstone disease and affect 3 to 5% of patients with cholelithiasis. Most fistulas are diagnosed intraoperatively and often requires conversion to open surgery.<sup>12</sup> The study was conducted to evaluate the incidence of different types of internal biliary fistula (1.9%), incidence of upto 4.8%, which demonstrate that most common type was choledochoduodenal fistula (62%), followed by cholecystoduodenal fistula (19%), cholecystocholedochal (11%), cholecystocolonic fistula (8%). In most of the

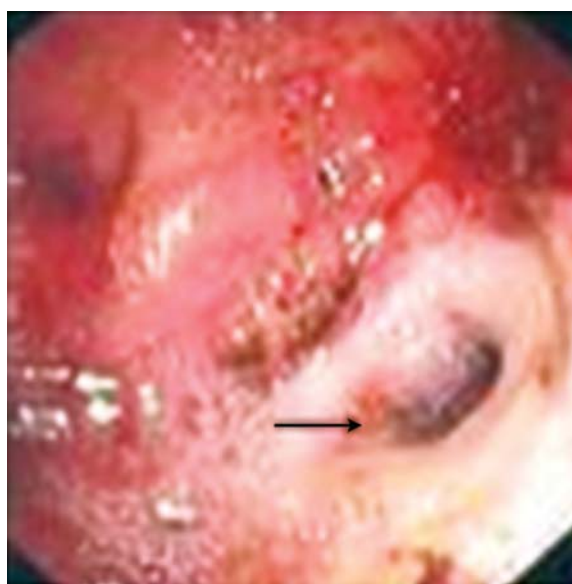

**Fig.1:** The fistulous connection of gallbladder with the duodenum in cholecystoduodenal fistula<sup>14</sup>

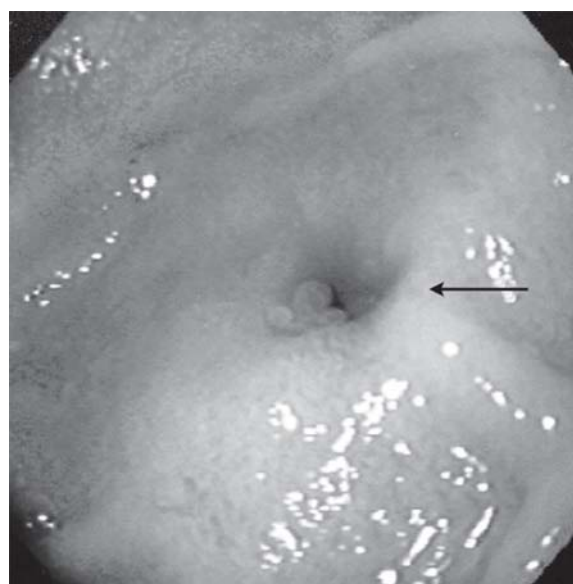
patients, the cause of these fistulas are biliary stone, in few cases by malignant tumors. All of the bile samples taken were bacteria-positive and the majority of the calculi were brown pigment stones. These fistulas were repaired using endoscopic stapling device without complications with laparoscopy.<sup>10</sup> Peptic duodenal perforation ulceration is the common cause for the upper GI bleeding, which will affect the duodenal bulb caused by CCDF and lead to spillage of gallstone into the second part of duodenum.<sup>6</sup>

Bouveret's syndrome is a rare condition consisting in a duodenal obstruction due to the passage of gallstones from the gallbladder to the duodenum through a cholecystoduodenal or cholecystogastric fistula. The fistula is a large, patulous opening, creating a continuation of the gallbladder and the duodenal bulb. The preoperative diagnosis of Bouveret's syndrome is very difficult. The diagnosis was made on endoscopy, which allows visualization of the stone and the fistula also (Fig. 2). Fragmentation and removal

of the stone endoscopically is also a therapeutic option (Fig. 3).<sup>8</sup> The first laparoscopic cholecystectomy was performed by Mouret in 1987, and the scope of biliary surgery for the laparoscopic surgeon has increased now. There were several accepted contraindications for the laparoscopic surgery in the early stages; some of these were acute cholecystitis, morbid obesity, adherent gallbladder, jaundiced patients, ductal calculi and biliary tract anomalies. In the past, a lot of series of cases of the laparoscopic cholecystectomies incidental encounter of the cholecystoduodenal fistulae were seen. With increasing expertise and improved instrumentation, cholecystoduodenal fistula can be dealt with laparoscopic approach.<sup>7</sup> Biliary metallic stents related complications of migration, bile duct rupture; pressure necrosis by impacted calculi and food particles in cases of ampulla of Vater carcinoma reported and lead to CCDF.<sup>16</sup> Laparoscopic cholecystectomy is one of the commonest procedures being performed by the



**Fig.2:** The fistulous opening of within the duodenum



**Fig.3:** Endoscopic examination reveals the orifice of cholecystoduodenal fistula (arrow), bile excretion into second part of the duodenum<sup>11</sup>

surgeons all over the world. High incidence of cholelithiasis combined with the lack of health care facilities and the lack of awareness on the part of the patient contributes to very common presentation of the patient in the advanced stage of the disease.

## INVESTIGATIONS

Barium study may reveal duodenal obstruction and repletion defects and site of cholecystoduodenal fistula, and good quality, high-resolution USG or CT may be helpful in revealing pneumobilia/aerobilia and lithiasis. As per Cooper et al (1987) and Kasano et al (1997) CT can demonstrate the gallbladder and the duodenum not to be separate and distinct structures (thickly adherent-mass formation), and contracted gallbladder with lot of adhesions (1998) (Fig. 4). Endoscopy has been the main diagnostic procedure in case of Bouverets syndrome in which gallstones can be seen in the duodenum.<sup>8</sup> MRI/MRCP, ERCP, cholangiography can be helpful in making the diagnosis (Fig. 5).

## ANESTHETIC CONSIDERATION

All the patients were given general anesthesia with endotracheal intubation, multipara close monitoring, IV line and proper fluid and electrolyte conduct the safe and secure laparoscopic procedures.

## OPERATIVE PROCEDURE

Usually all the patients for laparoscopy approach to the hospital with the anticipation of second day discharge. With the patient in supine position, general anesthesia induction with endotracheal tube was done. Sterile preparation and drapping of whole abdomen done. All the previous surgical scars should be considered in view of intra-abdominal adhesions which may lead to inadvertent injury to the viscera, such as gut. Two 10 mm and two 5 mm ports are made as routine cases for the laparoscopic cholecystectomy, one 10 mm umbilical and one 10 mm epigastric port and one 5 mm port in right subcostal and another 5 mm in the right anterior axillary line 7.5 cm apart on each side. Access to the peritoneal cavity to create the pneumoperitoneum may be difficult in the previously operated cases. In these cases, creating pneumoperitoneum by open technique (Hassan's technique) or use of veress needle through the Palmer's point (2 cm below the left costal margin in the midclavicular line) can be the useful alternatives to the umbilical port. The dissection should be done keeping in mind the anatomy of the hepatobiliary system and proceed step by step till the separation of gallbladder from duodenum, dissection of CCDF, removal of gallbladder and closure of fistula.

One should stay close to the liver margin, either medially or laterally to approach thickly adherent gallbladder and CCDF. Lifting the Hartmann's pouch early in the dissection

allows easier definition of the gallbladder/cystic duct junction and circumferential dissection around the cystic duct and cholecystoduodenal fistula (Fig. 6).

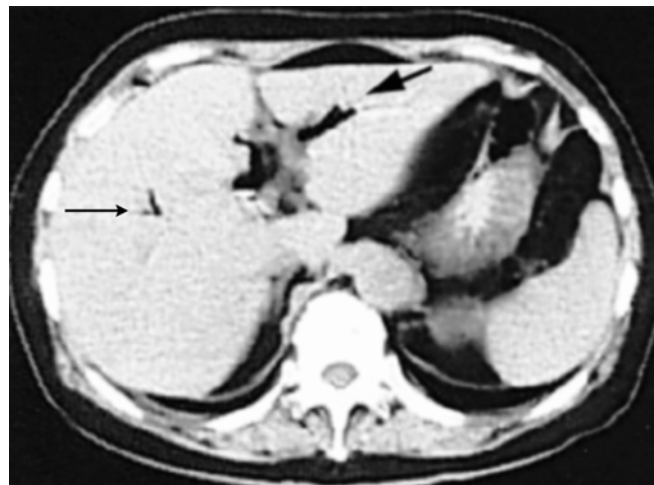


Fig.4: Computerized tomography shows pneumobilia (arrow)<sup>11</sup>

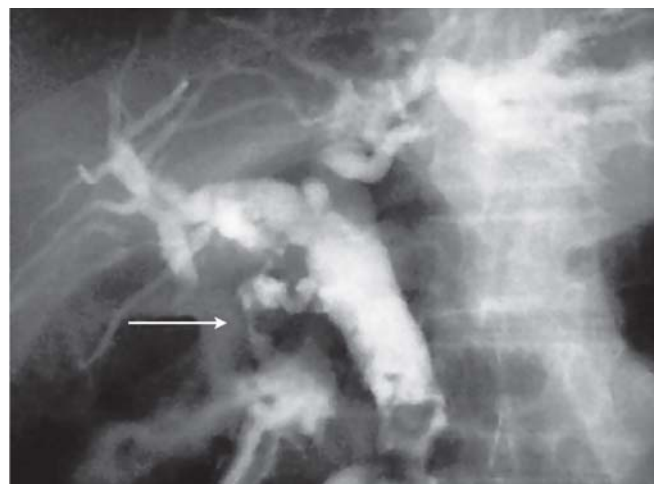


Fig.5: Endoscopic retrograde cholangiography reveals a dilated common bile duct including a multiple bile duct stone with cholecystoduodenal fistula (arrow)<sup>11</sup>

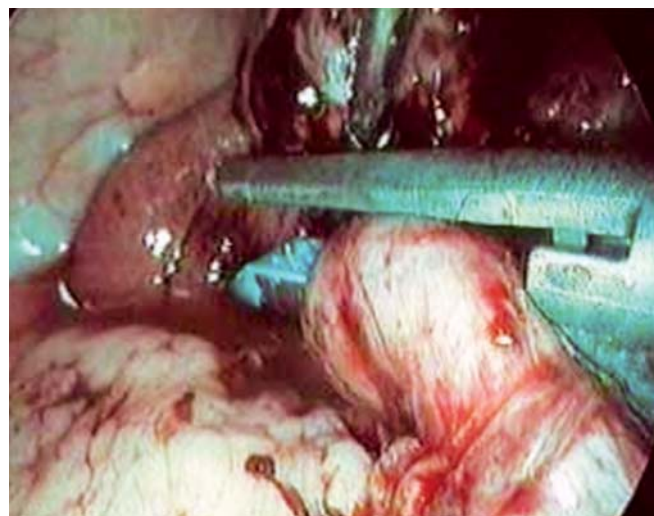


Fig.6: The cholecystoduodenal fistula was mobilized and divided using endoscopic linear stapling device<sup>14</sup>

Define gallbladder/cystic duct junction—surgical dissection of cystic duct and cystic artery should begin adjacent to or near the point of origin of cystic duct or near point of entry of the vessel. Identification of cystic lymph node as a landmark to define cystic duct and cystic artery. Calot's triangle—Dissection in Calot's triangle should be performed after identifying gallbladder/cystic duct junction. The tip of the curved dissector should be facing anterolaterally towards the gallbladder to avoid the injury to the liver or the CBD while dissecting the Calot's triangle.<sup>20</sup>

Proper localization of common bile duct should be done during surgery by retracting the duodenum downwards, retracting the right lobe of liver with proper traction to the Hartmann's pouch keeping in mind the plane of Rouviere's sulcus.

Maintain the plane of dissection in the cholecystic plate while removing the gallbladder from the liver. Dissection deeper in this plane may cause injury to the liver and cause troublesome bleeding while dissection superficial to this plane may cause perforation of the gallbladder and spillage of bile. Cholecystoduodenal fistula can be completely mobilized with a combination of blunt and sharp dissection and divided using the endoliner stapling device for the fistula closure. These fistulae were repaired laparoscopically using an endo-GIA 35 endoscopic stapling device. The endostapler can be used in few cases to transect the fistula and in other cases, the defect in the bowel can be repaired with intracorporeal sutures. In the other way, after division of the cystic duct and artery, the gallbladder was dissected from the liver bed, leaving just the fistulous connection to the duodenum. Then division of the fistula was completed using the same stapling device. The placement of additional trocar, frequent irrigation and suction, use of suction canula for dissection, use of gauze piece in case of minor bleed and adequate traction on the infundibulum of gallbladder to display structures in the Calot's triangle are useful aids to dissection. Every effort should be made to avoid the spillage of bile into the peritoneal cavity as this will increase the incidence of postoperative infection, abscess formation and also make the incidental stage 1 carcinoma into stage 4. The better outcome has been reported with the use of harmonic scalpel and fundus first technique in the recent studies.

### **INTRAOPERATIVE COMPLICATIONS, RISK FACTORS AND PRECAUTIONS TO AVOID THESE COMPLICATIONS**

All surgeons will encounter difficult cholecystectomies in their lifetime. Many cumbersome situations can be prevented or made easier by the cautious surgeon who has a carefully thought-out plan for each potential problem. One should proceed very slowly to counter the challenges that may be faced in beginning with diagnosis and continuing through

the operative procedure including the decision to operate, the best intervention, abdominal entry, dealing with common ductstones, proper careful dissection over the cholecystoduodenal fistula area for the separation from duodenum, intraoperative cholangiography, exposure of the biliary anatomy, avoidance of bleeding or common duct injury, spilled stones and postoperative bile collection. One should emphasize on prevention and management of inadvertent injuries.<sup>9</sup> The difficulty of laparoscopic cholecystectomy or the risk of conversion to open cholecystectomy can be predicted by assessing some preoperative variables.<sup>19</sup> The authors evaluated the efficacy of the risk score for conversion from laparoscopic to open cholecystectomy (RSCLO), which was recently developed by Kama et al (Am J Surg 2001;181:520). Safe dissection is the key to complete laparoscopic cholecystectomy successfully. Minimal use of electrocautery in Calot's triangle should be advocated. Adherence to the basic protocol of surgery and progressing step by step while following the landmarks of hepatobiliary anatomy. If the injury is detected intraoperatively and the necessary facilities with expert surgical team are available, then repair should be done in the same operation or put stent by ERCP in postoperative period.

### **Risk Factors**

The review by Strasburg et al in 1995 of approximately 124000 laparoscopic cholecystectomy reported in literature found the incidence of major bile duct injuries to 0.5%. In 1995, Strasberg and Soper modified the Bismuth classification of bile duct injury. Bile duct injury is the most catastrophic event that can happen to a patient undergoing surgery leaving the patient with high morbidity. In 1991, surgeons of French society of endoscopic and operative radiology reported 101 postoperative complications by laparoscopic surgery (morbidity 3.2%) 42 biliary and 59 nonbiliary, 18 bile duct injuries and six deaths (0.2%) reported out of 2955 laparoscopic cholecystectomies.<sup>18</sup> The duodenal injuries, gastric injuries, colonic injuries, vascular injuries are very common. One should be very careful in such cases with complicated gallstone disease to avoid any disastrous complication which can result in biliary cripples.

### **Complications of the Disease**

Peptic duodenal perforation ulceration is the common cause for the upper gastrointestinal bleeding, which will affect the duodenal bulb. Bouveret's syndrome is a rare entity consisting in a duodenal obstruction due to the passage of gallstones from the gallbladder (gallstone ileus) to the duodenum through a cholecystoduodenal or cholecystogastric fistula. Associated cases of Mirizzi syndrome with cholecystoduodenal fistula will lead to biliary leakage and biliary peritonitis and septicemia.

## Contraindication for Laparoscopic Procedure

The Mirizzi syndrome refers to common hepatic duct obstruction caused by an extrinsic compression from an impacted stone in the cystic duct. It is often not recognized preoperatively, which can lead to significant morbidity and biliary injury, biliary leakage and biliary peritonitis due to distorted anatomy in laparoscopic surgery.

## RESULTS

In 1991, Miguel Velez et al (surgical endoscopy) reported a case of successful laparoscopic repair of cholecystoduodenal fistula incidentally noticed in cholecystectomy.<sup>2</sup>

In 1999, Yashimota et al performed the laparoscopic surgery of cholecystoduodenal fistula and cholelithiasis. With the use of a flexible HD video scope, flexible retractor and endoscopic transecting stapler, laparoscopic treatment of cholecystoenteric fistulae was performed.<sup>15</sup>

In 2000, Scott et al treated two middle aged women having acute exacerbations of chronic gallbladder disease with laparoscopic surgery. A cholecystoduodenal fistula diagnosed intraoperatively in each case. These fistulae were repaired laparoscopically using an endoscopic stapling device without complication. Each patient did well postoperatively and was discharged on the second postoperative day in good condition.<sup>10</sup>

In 2001, Moreno et al conducted study on laparoscopic biliary pathology from 1992 to 1999 (191 emergency and 877 elective surgeries). A total of 302 cases (28%) were of complicated biliary pathology; out of these they reported 14 cholecystoduodenal fistulae, three cholecystocolonic fistulae and two cholecystogastric fistulae. Only in five patients with cholecystoduodenal fistula, the operation was successfully completed by laparoscopy. Conversion to open surgery was because of bleeding (5 cases), difficulty for colon suture (2 cases) and inflammation of the gallbladder with the duodenum (7 cases). An endo-GIA 35 was used to transect the fistula. All patients were discharged after 4 or 5 days without wound infection, and they have been evaluated at 3 and 12 months without problems.<sup>5</sup>

In 2006, Chikamori et al (Japan) reported a case of cholecystocholedocholithiasis with cholecystoduodenal fistula diagnosed preoperatively and treated with a combined approach endoscopic sphincterectomy for the multiple CBD stones and laparoscopic cholecystectomy and cholecystofistulectomy with the help of endoscopic linear stapling devices for the fistula closure. They concluded that laparoscopic cholecystofistulectomy by skilled laparoscopic surgeons can be adopted as a first-choice treatment for cholecystoduodenal fistula.<sup>11</sup>

In 2003, El Dhuwaib et al conducted study on gallstone ileus and small bowel obstruction in elderly women. The enterolithotomy and cholecystectomy have been performed

laparoscopically with closure of the cholecystoduodenal fistula. In the risky patient, staged laparoscopic management of gallstone ileus and the associated cholecystoduodenal fistula is feasible and seems to be safe. In high risk cases, imaging of the biliary tree is must to detect silent choledocholithiasis, which also can be managed along with and safely by the laparoscopic and endoscopic approach.<sup>14</sup>

In a series of 300 laparoscopic cholecystectomies, the authors encountered five cholecystoduodenal fistulae. It was possible to manage four fistulae laparoscopically. Two patients underwent a laparotomy, one for a failed laparoscopic repair of cholecystoduodenal fistula and the other for several common bile duct (CBD) stones, which could not be removed laparoscopically via the cystic duct. Most cases of cholecystoduodenal fistula could be dealt with increasing expertise and improved instrumentation.<sup>7</sup>

In 2007, Maciej et al conducted a study in which 56-year-old woman with past history of 20 years colic pain in right hypochondriac region diagnosed as case of cholelithiasis. Laparoscopic cholecystectomy was initiated, but following the diagnosis of cholecystoduodenal fistulas, it was converted to an open cholecystectomy, postoperative recovery was without complication. Cholangiography performed one week after surgery showed residual choledocholithiasis.<sup>13</sup>

In 2006, Chowbey et al study was conducted to assess the use of different suturing modes. The operation could be completed laparoscopically in 59 patients. An endostapler was used in 47 patients to transect the fistula and in 12 patients the defect in the bowel was repaired with intracorporeal sutures. The mean postoperative hospital stay was 5.2 days. All the patients are asymptomatic at a mean follow-up of 2.4 years.<sup>12</sup>

In 2010, Azra lactic et al reported five cases of CCDF diagnosed intraoperatively, managed successfully by laparoscopic approach. During the 3-year period, from 2007 to 2009, 1500 patients underwent laproscopic cholecystectomy for gallstone disease, only five of them (3.3%), who presented with routine symptoms of symptomatic cholelithiasis, intraoperatively CCDF were found. Laparoscopic surgery was performed using the standard three trocars technique. All patients were females, 67 years old on average. In three cases, CCDF was completely mobilized with a combination of blunt and sharp dissection and divided using the endolinear stapling device. In the other two cases after division of the cystic duct and artery, the gallbladder was dissected from the liver bed, leaving just the fistulous connection to the duodenum. Then division of the fistula was completed using the same stapling device. All five patients had uneventful postoperative course. The hospital stay of five patients ranged from 5 to 10 days (median 6 days).<sup>4</sup>

## DISCUSSION

After introduction of laparoscopy cholecystectomy in late decade of 1980, the field of general surgery was revolutionized. Many articles about successful laparoscopic repair of CCDF have been written. It was found that laparoscopy has many benefits to patients' life—less pain, less blood loss during operation decrease hospital stay, morbidity, earlier return to normal activities and cosmesis. After review, many articles about cholecystoduodenal fistula and risk factor of injuries and their proper management and long-term better effect on quality of life. It is a good option for treatment of symptomatic gallstone disease, complicated gall bladder diseases and cholecystoduodenal fistula. With more experience and improved techniques, most of these cases could be performed laparoscopically, with all of the advantages of minimally invasive surgery.<sup>4</sup> The Cholecystoenteric/Cholecystoduodenal fistula is a difficult problem usually diagnosed intraoperatively. A high degree of suspicion at operation is mandatory. A stapled cholecystofistulectomy may be the procedure of choice, since it avoids contamination of the peritoneal cavity. Complete laparoscopic management of cholecystoenteric/cholecystoduodenal fistula is possible in well-equipped centers.<sup>12</sup>

## CONCLUSION AND RECOMMENDATION

Laparoscopic surgery has become the standard care for the cases of benign gallbladder diseases. Cholecystoduodenal fistula can no longer be considered a contraindication for laparoscopic treatment, and it does not increase morbidity risk. The cholecystoduodenal fistula does not preclude a laparoscopic approach. With more and more endeavors being made in the field of laparoscopy, more and more complicated cases which were relatively contraindicated a few years ago are now being tackled laparoscopically. We feel that laparoscopic repair is a safe and effective approach in the hands of surgeons with significant laparoscopic experience.

## REFERENCES

1. Sfairi A, Patel JC, Chir J. Gallstone ileus: Plea for simultaneous treatment of obstruction and gallstone disease. *July 1997*;134(2):59-64.
2. Meguel Velez, Joseph Mule, et al. Laparoscopic repair of cholecystoduodenal fistula. *Surg Endosc* 1991;5:221-23.
3. Soto DJ, Evan SJ, Kavic MS. Laparoscopic management of gallstone ileus. Department of Surgery, St Elizabeth Hospital Medical Center, Youngstown, Ohio, *JSL* 5(3):279-85.
4. Azra Latic, Ferid Lati, Mirela Delibegovic, Josip Samardzic, Darko Kraljik, Samir Delibegovic. Successful laparoscopic treatment of cholecystoduodenal fistula. *Med Arh* 2010;64(6): 379-80.
5. Moreno Ruiz FJ, del Rey Moreno A, Suescun García RM, Martínez Ferriz JA, Hidalgo Garrido JM, Espadas Padial B, et al. Treatment of cholecystoduodenal fistula in the era of laparoscopy *Rev Esp. Enferm Dig* Nov 2001;93(11):715-20.
6. Al\_Rashedy ME, Issa P Ballester, et al. Impending cholecystoduodenal fistula as a cause for an usually sited bleeding duodenal ulcer. *The Internet Journal of Surgery* 2005;7(1).
7. Sharma A, Sullivan M, English R. Laparoscopic repair of cholecystoduodenal fistulae. *Surg Laparosc Endos* Dec 1994;(6):433-35.
8. Cooper (1987), Kasano (1997), Romano (1997), Farman (1998) et al. Diagnosis of biliary fistula and gallstone ileus.
9. Laws HL. The difficult cholecystectomy: Problems during dissection and extraction. *Semin Laparosc Surg* June 1998;5(2): 81-91.
10. Scott D Crouch, Mark Kuhnke. *Journal of Laparoscopic and Advanced Surgical Techniques* August 2000;10(4):223-26.
11. Chikamori F, Okumiya K, et al. Laparoscopic cholecystofistulectomy for preoperatively diagnosed cholecystoduodenal fistula. *J Gastroenterol* 2001;36(2):125-28.
12. Pradeep K Chowbey, Samik K Bandyopadhyay, Anil Sharma, Rajesh Khullar, Vandana Soni, Manish Baijal. *Journal of Laparoendoscopic and Advanced Surgical Techniques* Oct. 2006;16(5):467-72.
13. Maciej Stachowiak. Coexistence of two cholecystoduodenal fistulas with common bile duct stones in a patient without jaundice. *Polish Nov.* 2007;79(11).
14. El Dhuwaib Y, bAmmori BJ. Staged and complete laparoscopic management of cholelithiasis in a patient with gallstone ileus and bile duct calculi. *Surg Endosc* June 2003;17(6):988-89.
15. Oka M, Yoshimoto Y, Ueno T, Yoshimura K, Maeda Y, A Tangoku. *Surgical laparoscopy, endoscopy and percutaneous techniques* 01/07/1999; 9(3):213-6. ISSN: 1530-4515.
16. Tae Hoon Lee, et al. Spontaneous choledoduodenal fistula after metallic stent placement in the patient of ampulla of vater carcinoma, cheonan hospital, korea. *Gut and Liver* Dec 2009;3(4): 360-63.
17. Rosin D, Portnoy O, Stanewsky A, Bar Zakai B, Yanko-Arazi R, Kuriansky Y, Shabtai M, Avalon A. The laparoscopic treatment of gallstone ileus. Department of General Surgery and Transplantation, F. Sheba Medical Center, Tel Hashomer Harefuah Mar 2003;142(3):176-78, 239.
18. Collet D, Edy M, et al. Conversion and complications of laproscopic cholecystectomy. *Surg endosc* 1993;7:334-38.
19. Singh K, Ohri A. Difficult laparoscopic cholecystectomy: A large series from north India. *Ind J Surg* 2006;68(4):205-08.
20. Singh K, Ohri A. Anatomic landmarks: Their usefulness in safe laparoscopic cholecystectomy. *Surg Endosc* Nov. 2006;20(11): 1754-8. Epub 2006 Sep. 23.
21. Chong VH, Lim KS, Mathew VV. Spontaneous gallbladder perforation, pericholecystic abscess and cholecystoduodenal fistula as the first manifestations of gallstone disease. *Hepatobiliary Pancreat Dis Int* Apr 2009;8(2):212-14.

# Different Types of Single Incision Laparoscopy Surgery (SILS) Ports

Chigurupathi Venkata Pavan Kumar

Assistant Professor, Mamata Medical College and Hospital, Khammam, Andhra Pradesh, India

## ABSTRACT

**Introduction:** Single incision laparoscopic surgery (SILS) has become an advancement in minimal access surgery because it offers benefits like less postoperative pain, less invasive and has best cosmetic results. Even though the amount of time taken for SILS surgery is more, this can be brought down by experience and more advances on the type of instruments used. We are going to review different types of SILS ports available in the world today.

**Material and methods:** Articles of relevant studies are searched from the internet using Google, PubMed, Yahoo, HighWire press, SpringerLink, etc. available at world laparoscopic hospital.

**Aims:** The main aim of this review is to evaluate different types of SILS ports and their effectiveness in safe laparoscopic surgeries. To know if they offer any less postoperative pain and best cosmetic results than the multiple trocar surgeries, and to know the best SILS port.

**Conclusion:** Whatever might be the choice of single incision laparoscopic surgery or procedure, the best choice of port depends on many factors like choice of the surgeon, skill of the surgeon, availability of ports, operative time of the procedure and cost effectiveness. To know this, we need more controlled randomized studies on different types of SILS ports in single procedure. We cannot pinpoint which might be the best port for SILS at this point of time.

**Keywords:** Single incision laparoscopic surgery (SILS), LESS, Minimal access surgery, Single port access (SPA), SILS ports, NOTES.

## INTRODUCTION

History of single incision laparoscopic surgery dates back to 1992, where Pelosi performed single puncture laparoscopic appendectomy. In 1997 Navarra et al performed laparoscopic cholecystectomies with two trans-umbilical trocars. Some of the disorders like gallbladder stones, the gold standard treatment of choice is laparoscopic cholecystectomy. But now there are so many advances and refinements in technology and instrumentation that cholecystectomy is being done by SILS and NOTES in some of the centers all over the world. These advances help in making the surgery less invasive and cosmetically the outcome is good and superior to other procedures. In this article, we are going to review the different literature available regarding different types of SILS ports available in the market and to know if they offer any advantage over one another.

## SURGICAL TECHNIQUE

Whatever might be the procedure being done, the basic principle is same that multiple instruments or multiple trocars are placed in a single port of entry. The positions for single port access may be different depending on many factors like choice of surgeon, type of surgery and age of the patient.

The different locations commonly used are:

1. A 6 cm long omega-shaped incision made around the upper half of umbilicus.
  2. Transumbilical insertion is commonly used and ideal to prevent any visible scar.
  3. Some surgeons placed incision in the pubic hairline medially.
  4. Incisions are also given above and below the umbilicus to give excellent cosmetic results.
- But the choice of incisions mainly depends on the surgeons' preference.
- A lot of surgeons are using 30° laparoscopy light source but several teams also use small diameter laparoscopy with angular tip and incorporated light source.<sup>1-3</sup>
- Next is the choice of instrument. Some surgeons have been using regular laparoscopic instruments but because of the advent of new technology, now surgeons are using more and more of curved or angular or flexible laparoscopic instruments. In some cases for multichannel ports, a Roticulator grasper (Covidien) was used.
- Next is the choice of single incision laparoscopy surgery ports. There are many different ports, available but we are dealing with only few selected ports which are commonly used. The choice of port completely depends on the surgeons' choice and preference, availability of port and cost factor.
- Once the choice of port is made, they are placed in the abdomen for single port access surgery. The dissection and procedure for that particular surgery is performed in the same fashion as standard laparoscopic procedure. On

completion of the procedure, the trocar site facial plane is closed. If the facial incision was enlarged for specimen delivery then they are closed in standard manner. Then the skin is closed with subcuticular suture.

## DISCUSSION

Single incision laparoscopy is being performed by many surgeons throughout the world. Many articles and studies are being done because SILS is laying a bridge to more advanced surgery like NOTES (natural orifice transluminal endoscopic surgery). The different procedures performed by single incision ports are cholecystectomy, colonic procedures like colectomy, appendectomy, splenectomy, adrenalectomy, omental resection, liver biopsy and procedures on small bowel. Saber et al reported a SILS series in bariatric surgery specifically by transumbilical sleeve gastrectomies.<sup>4</sup>

All over the world there is so much interest in performing single incision surgeries for best cosmetic outcome that many of the groups have pioneered and mastered this technology.<sup>5-18</sup>

There are so many nomenclatures for SILS (Table 1).<sup>27</sup>

Now coming to the different types of ports, there are so many surgical teams performing different types of surgeries with different ports (Figs 1A to D). We are going to discuss briefly on some of the commonly used ports.

## SILS PORT (BY COVIDIEN)

SILS port is one of the most commonly and widely used port all over the world (Fig. 2). It has a blue, flexible soft-foam port with three access channels for three instruments. There is 5 mm cannula and 5 to 12 mm cannula. The SILS port can adapt depending on the size of instrument while still maintaining pneumoperitoneum.

## GELPORT (BY APPLIED MEDICAL)

GelPort laparoscopic system has gel seal cap with the enhanced retractor and protection of Alexis wound retractor.


The Alexis wound retractor has 360° of atraumatic, circumferential retraction and protection (Fig. 3). This port is being used by many surgeons. In many of the studies GelPort system has being used.<sup>19-20</sup> One surgical team also proposed use of GelPort to increase the freedom of motion.<sup>21</sup>

## TRIPORT AND QUADPORT (BY ADVANCED SURGICAL CONCEPTS)

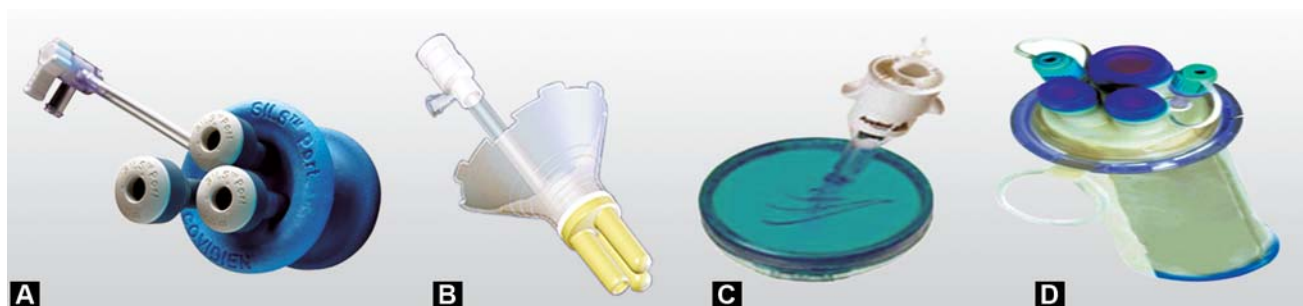
It has a multi-instrument access port for single incision laparoscopic surgery (Fig. 4). ASC has also developed quadport, here the incision required is 2.5 to 6.5 cm in

**Table 1:** Synonym of SILS

- Single incision laparoscopic surgery
- TUES (Transumbilical endoscopic surgery)
- SILS™
- LESS™ (Laparoendoscopic single-site surgery)
- SPA™ (Single portal access)
- E-NOTES (Embryologic natural orifice transluminal endoscopic Surgery)
- SAS (Single access surgery)
- S3 (Single site surgery)
- Single port surgery
- CL1P (Cirugia laproscopy pica de 1 puerto, one-port laparoscopic surgery)
- NOTUS (Natural orifice transumbilical surgery)
- SAVES (Single access video endoscopic surgery).



**Fig. 2:** SILS Port



**Figs 1A to D:** Commonly used ports all over the world are: (A) SILS Port (Covidien, Norwalk, Connecticut, USA), (B) ASC Triport (Advanced Surgical Concepts, Wicklow, Ireland), (C) GelPort (Applied Medical, Rancho Santa Margarita, California, USA), (D) Uni-X (Pnavel Systems, Morganville, New Jersey, USA)

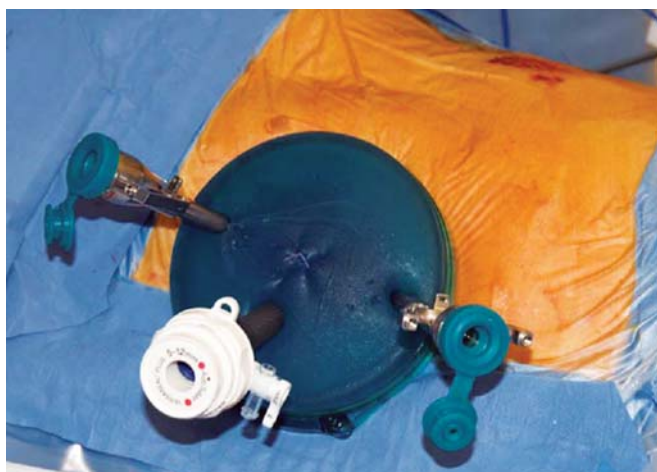

Fig. 3: Alternative to SILS Port

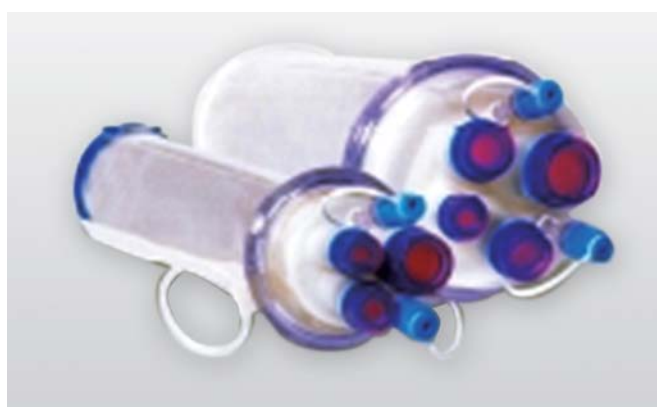

Fig. 4: Triport and Quadraport

length that allows upto four instruments to be used simultaneously.

### ANCHORPORT (R) (BY SURGIQUEST)

Surgique has developed a port called AnchorPort (R), which is used in single incision laparoscopy procedure. It has an integrated elastometric, stretchable cannula system that goes into elongated adjustments according to the patients' abdomen wall thickness (Fig. 5). It also has a distal tip where it anchors the cannula to the abdominal wall and prevents it from coming out.

Whatever might be the choice of ports, the most important thing is safety of the patient. Any surgery performed by single incision laparoscopy can be done by the conventional laparoscopic instruments or sometime you require special specifically designed laparoscopic instruments. The choice of the ports depends on the surgical team, cost factor, and the availability of these ports. Most of the studies indicate the main advantages of single incision laparoscopy surgery ports, which include less postoperative pain, less chance of infection, and less chances of port site hernias. Multiport laparoscopy surgery has a published data on port site hernias with an estimate of 0.14%.<sup>22</sup> But all

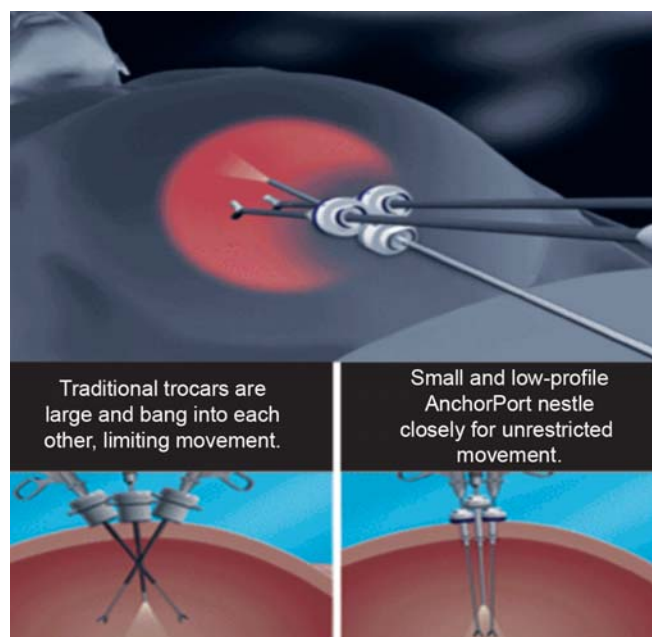


Fig. 5: AnchorPort

these advantages have to be evaluated by further studies. At SAGES conference in 2009, almost 500 cases of single incision laparoscopic cholecystectomy were reported.<sup>23-25</sup> The main factor for safety of single incision laparoscopy surgery depends on the surgeon himself. There is a steep learning curve required for the safety of the procedure. One of the surgical teams has advised a "stepwise down" approach.<sup>26</sup> One article has given a good list of problems and solutions seen during single incision laparoscopic surgery (Table 2).<sup>27</sup>

Table 2: Problems in SILS

#### Problems

- Clashing of instruments
- Lack of ideal operative ports
- Interference and deflection of laparoscope's light source by operating instruments
- Interference of wires or tubing that connect perpendicularly to instruments (i.e. cautery)
- Difficulty with retraction of organs or structures
- Change of surgeon's mindset
- Lack of time and patience to learn
- Loss of proprioception due to crossed instrument.

#### Solutions

- Use of curved, reticulating, or flexible instruments
- Use of very low-profile trocars
- Staggering heights and heads of trocars
- Use of novel multichannel ports
- Use of a laparoscope with a light source on the back of the camera
- Use of a flexible-tip endoscope
- Use of an extra-long 5 mm angled laparoscope (50 cm)
- Use of a 908 adaptor for the light source (for sharp change in its direction parallel to the laparoscope)
- Use of instruments that connect at their distal ends, any necessary wires or tubing (i.e. cautery)
- Use of extra-long bariatric size instruments
- Use of retracting sutures
- Continuous medical education.

Contd.

Contd.

**Potential solutions**

- Design of innovative retracting platforms
- Implementation of magnetically anchored instruments deployed through a single incision
- Implementation of robotic platforms
- Design of sigmoid-shaped instruments
- Additional basic surgical principles
- Sound surgical judgment
- Maintenance of equivalent operative exposure
- Low threshold for the use of additional ports at the initial incision site or
- Prompt conversion to conventional laparoscopy or to open surgery.

The table shows commonly encountered problems in SPA surgery (see Table 2).

Different types of instruments for laparoscopic surgery have to be developed like retractors, dissection and laparoscopic cameras to make the surgeon more efficient. As we lead into the next phase of minimal access surgery, we need to develop procedures, instruments and ports easily available and affordable so that they can be used for large volume of patients.

**CONCLUSION**

After review of all the articles and many studies we still cannot come to the conclusion about the best port available in single incision laparoscopy. The different single incision laparoscopy ports have different features from one another. Each one has its own unique features. So, the choice of single incision laparoscopy port depends on surgeon, availability and cost factor. To ascertain which port is better, we need to do further studies and research. Whatever might be the choice of the port, the surgical procedure and patients should not be comprised.

**REFERENCES**

1. FH Remzi, HT Kirat, JH Kaouk, DP Geisler. Singleport laparoscopy in colorectal surgery. *Colorectal Disease*. 2008;10(8):823-26.
2. P Bucher, F Pugin, P Morel. Single port access laparoscopic right hemicolectomy, *International Journal of Colorectal Disease* 2008;23(10):1013-16.
3. J Leroy, RA Cahill, M Asakuma, B Dallemagne, J Marescaux. Single-access laparoscopic sigmoidectomy as definitive surgical management of prior diverticulitis in a human patient. *Archives of Surgery* 2009;144(2):173-79.
4. Saber AA, Elgamal MH, Itawi EA, et al. Single-incision laparoscopic sleeve gastrectomy (SILS): A novel technique. *Obes. Surg* 2008;18:1338-42.
5. Rivas H, Varela E, Scott D. Single incision laparoscopic cholecystectomy in an animal model. *Society of Gastro Endoscopic Surgeons, Annual Congress, Emerging Technologies, Philadelphia, PA 2008*.
6. Rivas H, Varela E, Scott D. Single-incision laparoscopic surgery for placement of adjustable gastric banding in an animal model. *Society of Gastrointestinal Endoscopic Surgeons, Annual Congress, Emerging Technologies, Philadelphia, PA 2008*.
7. Raman JD, Bensalah K, Bagrodia A, Stern JM, Cadeddu JA. Laboratory and clinical development of single keyhole umbilical nephrectomy. *Urology* 2007;70:1039-42.
8. Rivas H, Varela E, Scott D. As smooth as SILC: Single incision laparoscopic cholecystectomy. *Society of Gastro-intestinal Endoscopic Surgeons, Annual Congress, Emerging Technologies, Philadelphia, PA 2008*.
9. Rivas H, Rivas R, Vargas R, Rivas H. Single umbilical incision totally laparoscopic hysterectomy. *Society of Gastrointestinal Endoscopic Surgeons, Annual Congress, Emerging Technologies, Philadelphia, PA 2008*.
10. Castellucci SA, Curcillo PG, Ginsberg PC, Saba SC, Jaffe JS, Harmon JD. Single-port access adrenalectomy. *J Endourol* 2008;22:1573-76.
11. Cuesta MA, Berends F, Veenhof AA. The invisible cholecystectomy: A transumbilical laparoscopic operation without a scar. *Surg Endosc* 2008;22:1211-13.
12. Afthinos JN, Forrester GJ, Binenbaum SJ, Harvey EJ, Kim GJ, Teixeira JA. Single-incision laparoscopic cholecystectomy using flexible endoscopy: Saline infiltration gallbladder fossa dissection technique. *Surg. Endosc*. Epub ahead of print 19 March 2009.
13. Tacchino R, Greco F, Matera D. Single incision laparoscopic cholecystectomy: Surgery without a visible scar. *Surg Endosc* 2009;23:896-99.
14. Tracy CR, Raman JD, Cadeddu JA, Rane A. Laparoendoscopic single site surgery in urology: Where have we been and where are we heading? *Nat Clin Pract Urol* 2008;5:561-68.
15. Hodgett SE, Hernandez JM, Morton CA, Ross SB, Albrink M, Rosemurgy AS (2009). Laparoendoscopic single site (LESS) cholecystectomy. *J Gastrointest Surg*. 13:188-192 Epub 22 November 2008.
16. Zhu JF. Scarless endoscopic surgery: NOTES or TUES. *Surg Endosc* 2007;21:1898-99.
17. Elazary R, Khalaileh A, Zamir G, Har-Lev M, Almog G, Rivkind AI, Mintz Y. Single-trocar cholecystectomy using a flexible endoscope and articulating laparoscopic instruments: A bridge to NOTES or the final form? *SurgEndosc* 23:969-72 Epub 1 January 2009
18. Abe N, Takeuchi H, Ueki H, Yanagida O, Masaki T, Mori T, Sugiyama M, Atomi Y. Single-port endoscopic cholecystectomy: A bridge between laparoscopic and translumenal endoscopic surgery *J hepatobiliary pancreatic* 2009.
19. Mark A Rettenmaier, Lisa N Abaid, Michelle R Erwinb, Cameron R John, John P Micha, John V Brown III, Bram H. A Retrospective Review of the Gel Port System in Single-Port Access Pelvic Surgery. *Goldstein, Ph.Dab* Received 10 June 2009; accepted 30 July 2009.
20. Jung Hun Leea, Joong Sub Choia, Seung Wook Jeona, Chang EopSona, Se Jin Leea, Yong SeungLeeb. Single-port laparoscopic myomectomy using transumbilical Gel Port access; accepted 4 July 2010. Available online 3 August 2010. *J European journal of obstetrics and gynecology and reproductive biology*.
21. AM Merchant, E Lin. Single incision laparoscopic right hemicolectomy for a colon mass, *Diseases of the Colon and Rectum* 2009;52(5):1021-24.
22. R Singh, A Omiccioli, S Hegge, C McKinley. Does the extraction-site location in laparoscopic colorectal surgery have an impact on incisional hernia rates? *Surgical Endoscopy* 2008;22(12):2596-600.
23. Wu AS, Podolsky ER, Curcillo PG, Bessler M, Cohen L, Copper C, Dunham R, Fendley S, Graybeal C, Gumbs A, Iannelli A, Katkhouda N, Kelley W, Mason R, Neff M, Norton

- M. Single port access (SPA) cholecystectomies: Multi-institutional report of the first 100 cases. SAGES, scientific session and panel, single incision/single port laparoscopy, Phoenix, AZ; April 24, 2009.
24. Rivas H, Varela E, Scott D. Single incision laparoscopic cholecystectomy, initial evaluation of a large series of patients. SAGES, scientific session and panel, single incision/single port laparoscopy, Phoenix, AZ; April 24, 2009.
  25. Edwards CA, Bradshaw A, Ahearne P, Mauterer D, Soosaar P, Johnson R, Humble T, Dematos P. Single incision laparoscopic cholecystectomy is safe and feasible. SAGES, scientific session and panel, single incision/single port laparoscopy, Phoenix, AZ; April 24, 2009.
  26. Erica R, Podolsky Paul G. Curcillo II single port access (SPA)-a 24-month experience J gastrointestinal surgery 2010;14:759-67 accepted 26 october 2009.
  27. Homero rivas, Esteban varela Daniel scott. Single-incision laparoscopic cholecystectomy: Initial evaluation of a large series of patients. J surg. Endosc. 2010;24:1403-12 accepted 9 october 2009.

# Minimally Invasive Esophagectomy (MIE): Techniques and Outcomes

Sajesh Gopinath

Assistant Professor, Jubilee Medical College, Thrissur, Kerala, India

## ABSTRACT

**Background:** Esophageal cancer is one of the major public health problems worldwide. Different methods of minimally invasive esophagectomy (MIE) have been described, and they represent a safe alternative for the surgical management of esophageal cancer in selected centres with high volume and expertise in them. The procedural goal is to decrease the high overall morbidity of a traditional open esophageal resection.

**Aims:** This article reviews the most recent and largest series evaluation of MIE techniques.

**Methods:** A literature search performed using search engines Google, HighWire press, SpringerLink, and Yahoo. Selected papers are screened for other related reports.

**Results:** Though MIE requires greater expertise and a long learning curve, once technique has been mastered it greatly reduces the postoperative morbidity and mortality to a significant extent. There was not much difference in average operating time compared to open surgery but bleeding was less in MIE. Mean hospital stay was similar to open surgery. There was no significant difference in number and location of lymph nodes harvested.

**Conclusion:** The current review shows that MIE with its decreased blood loss, minimal cardiopulmonary complications and decreased morbidity and oncological adequacy, represents a safe and effective alternative for the treatment of esophageal carcinoma.

**Keywords:** Esophagectomy, Minimally invasive, Laparoscopy, Thoracoscopy, Esophageal neoplasm.

## INTRODUCTION

Esophageal cancer represents a major public health problem worldwide. It is the eighth most common cancer in the world and sixth most frequent cause of death with an estimated 462,102 new cases and 385,877 deaths per year.<sup>1</sup> According to SEER (Surveillance epidemiology and end results) data, 5-year survival has improved modestly over the past 30 years, from 6% in 1975 to 1977 to 17% in 1996 to 2002.<sup>2</sup>

Since Czerny first successfully resected a cancer of the cervical esophagus in 1877, esophagectomy has had a long history of high morbidity and mortality followed by a relatively poor long-term survival. Published perioperative mortality rates are available since 1940s, and the initial reported rate was 72%.<sup>8</sup> By the 1970s, a review of all published data showed a reduction in the rate to 29%.<sup>8</sup> In 1980s, it was 13%, and in 1990, it declined to 9%.<sup>8</sup> Surgery is the gold standard for treating localized esophageal cancer. Poor long-term outcome and predominance of distant failure prompted the evaluation of the role of chemoradiotherapy. No major difference was seen in survival between patients who underwent chemoradiotherapy followed by surgery versus those who had surgery alone.<sup>3,4</sup> Advances in surgical technology, staging and perioperative care could further reduce surgical morbidity and mortality. Of these advances, minimally invasive esophagectomy (MIE) has the greatest potential to improve on conventional esophageal surgery.

Minimally invasive surgery has been done and found to be possible in managing esophageal cancer, although apprehension was expressed about safety, efficacy, oncologic value or other advantages that justify longer operations. This article discusses outcomes in the management of esophageal cancer.

The use of thoracoscopy and/or laparoscopy for esophageal resection was introduced in 1992 by Cuschieri et al hoping that it would further reduce pulmonary morbidity while potentially improving the oncological quality of the resection by enhancing visual control during the mediastinal dissection.<sup>5</sup> Laparoscopic transhiatal esophagectomy was first reported by De Paula et al<sup>6</sup> in 1995 and by Swanstrom and Hansen<sup>7</sup> in 1997. Luketich et al<sup>9,10</sup> described the combined thoracoscopic and laparoscopic approach for esophagectomy.

## AIMS

This article aims at discussing various techniques and outcomes of minimally invasive esophagectomy.

The following parameters were evaluated for laparoscopic and open procedure:

1. Operating technique
2. Operating time
3. Intraoperative complications
4. Risk of anesthesia
5. Rate of conversion to open surgery

6. Postoperative pain and opiate analgesic requirements
7. Postoperative morbidity and mortality
8. Hospital stay
9. Satisfying oncological principle
10. Quality of life analysis.

## MATERIALS AND METHODS

A literature search was performed using search engines Google, HighWire Press, SpringerLink, and library facility available at laparoscopic hospital. Criteria for the selection of papers were upon statistical way of analysis, institute if specialized in laparoscopy, the way of management and operative techniques.

## OPERATING TECHNIQUE

Different surgical techniques are available, and the option depends on tumor location, extent of lymphadenectomy and surgeons' preference. The two most common open techniques are transhiatal and transthoracic (Ivor-Lewis) esophagectomies (THEs and TTEs respectively).<sup>11</sup> THE involves a laparotomy, blunt dissection of the thoracic esophagus, and cervical gastroesophageal anastomosis in the left neck.<sup>12</sup> Limitations include inability to perform a full thoracic lymphadenectomy and lack of visualization of the mid-thoracic esophageal dissection. In contrast, TTE combines a laparotomy with right thoracotomy and intrathoracic anastomosis. This approach allows for wide mediastinal lymphadenectomy with direct visualization. Other modifications of the transthoracic approach include a left thoracoabdominal incision, extended 3-field esophagectomy, and cervical anastomosis.<sup>13</sup>

MIE has been explored in both transthoracic and transhiatal approaches with the goal of overcoming intrinsic limitations. Multiple minimally invasive approaches have been described that combine thoracoscopic or laparoscopic procedures with various operative positions of the patient and anastomotic techniques (Table 1).

MIEs for the management of esophageal cancer were first described by Cuschieri et al<sup>5</sup> in 1992, and later refined

by Collard et al<sup>14</sup> in 1993. These first efforts involved thoracoscopic esophageal mobilization with subsequent laparotomy for gastric mobilization and cervical anastomosis. This approach avoids the morbidity of a thoracotomy, and permits complete and thorough mediastinal dissection. Several groups have reported their experience with excellent results using this technique which currently represents the most popular MIE technique. Refinements in the thoracoscopic technique have been pioneered by Luketich et al<sup>9,10</sup> describing a thoracoscopic esophagectomy. This technique involves video-assisted thoracoscopic esophageal mobilization in complete left lateral decubitus position followed by supine laparoscopic gastric mobilization and preparation of the gastric conduit with a standard cervical anastomosis. This offers the potential benefit of avoiding the need for both thoracotomy and laparotomy, minimizing pain in the postoperative period, and allowing a more rapid recovery.

To facilitate the abdominal procedure, some groups use a laparoscopic-assisted hand-port system, providing more tactile control and potentially decreasing operative time.<sup>15</sup> Furthermore, a hand-assisted system could be used in the thoracoscopic phase of the procedure to facilitate exposure into the right thoracic cavity (hand-assisted laparoscopic and thoracoscopic surgery).<sup>16</sup> Other modifications to this technique include thoracoscopic mobilization of the esophagus and mediastinal lymphadenectomy in the prone position.<sup>17</sup> The main advantages described for prone thoracoscopic mobilization of the esophagus are shorter anesthesia time and better postoperative respiratory function than with the left lateral position.

A minimally invasive THE was initially described by DePaula et al<sup>6</sup> in 1995 and then Swanstrom and Hansen<sup>7</sup> in 1997 as the first totally laparoscopic esophagectomy. The main advantage is direct visualization of lower mediastinum without blind dissection. Using this technique, a laparotomy is avoided. Other modifications to MIE involve the use of mediastinoscopic methods to aid superior mediastinal dissection.<sup>18</sup>

Some limitations of the laparoscopic THE involve the instrumentation, narrow field of the mediastinum, and two-dimensional view of conventional laparoscopic equipment. Robotic systems allow the possibility of overcoming some of these limitations. Some groups have reported their early experience with robotically assisted THE,<sup>20-22</sup> which involves laparoscopic gastric mobilization, mediastinal robotic dissection, and conventional transhiatal dissection from the cervical incision. This technique allows three-dimensional visualization, improved magnification, and greater range of instrument motion and could potentially diminish intraoperative complications during esophageal dissection in the mediastinum.

**Table 1:** Minimally invasive esophagectomy techniques

<ul style="list-style-type: none"> <li>• Thoracoscopic esophagectomy with laparotomy and cervical anastomosis</li> <li>• Thoracoscopic esophagectomy with laparotomy and intrathoracic anastomosis</li> <li>• Thoracoscopic esophagectomy with laparoscopy and cervical anastomosis</li> <li>• Thoracoscopic esophagectomy with laparoscopy and intrathoracic anastomosis</li> <li>• Laparoscopic gastric mobilization with thoracotomy and intrathoracic anastomosis</li> <li>• Laparoscopic THE with cervical anastomosis</li> <li>• Laparoscopic hand-assisted THE with cervical anastomosis</li> <li>• Laparoscopic esophagectomy with prone thoracoscopic esophageal mobilization</li> <li>• Robotically-assisted laparoscopic THE with cervical anastomosis.</li> </ul>
---

## STEPS OF THREE-STAGE ESOPHAGECTOMY

### Stage 1: Thoracoscopic Esophageal Mobilization

General anesthesia with single lung ventilation is used. The patient is placed in the left lateral decubitus position. Four ports are placed in diamond formation (Fig. 1).

Pneumoinflation is performed under a low pressure of 7 mm Hg. A diagnostic thoracoscopy is usually performed to inspect the pleural cavity and the surface of lung for any suspicious metastatic lesion. The right lung is retracted upward and medially to expose the thoracic esophagus.

The procedure is begun by incising the visceral pleura between the esophagus and infra-azygos part of the aorta with either a bipolar forceps or a harmonic ultrasonic scalpel. The medial end of the pleura is held by the left hand lifting the esophagus. Thus, the posterior vagus is exposed. The plane of dissection is lateral to the vagus and not between the vagus and esophagus. The direct aortic branches are clipped and cut. The esophagus then is lifted from the arch of the aorta, which is seen at the level immediately below the azygos vein. The left main bronchus is exposed, and the left hilar nodes are dissected. The esophagus is completely separated posteriorly by a combination of sharp and blunt dissection. The caudal limit of posterior dissection is the hiatus.

The thoracic duct is seen crossing the descending aorta, which is clipped. The anterior pleural cut was made after the esophagus is pulled laterally and the cut is extended cranially and caudally, remaining parallel to the esophagus. The plane of dissection is between the anterior vagus and pericardium. The carinal and right hilar nodes are removed. The dissection is carried caudally between the pericardium and esophagus, stripping the pericardium of all fibro fatty tissues and nodes. The caudal end point is the hiatus and this completes the infra-azygos dissection.

The supra-azygos area is exposed by the assistant pulling down the apex of the lung. The pleura over the

esophagus is lifted and cut. The cut is extended upward to the root of the neck. The vagus nerve is identified, and the vagal fibers going to the bronchus are preserved.

The dissection is started posteriorly between the esophagus and vertebrae. All the fibro fatty tissues together with the nodes are pushed with esophagus. The azygos vein is preserved or when required for better visualization or clearance, the vein can be clipped and cut. When the azygos vein is preserved, the pleura over the vein is cut, and a plane is created posterior to the vein and anterior to the esophagus. Retroazygos dissection is facilitated by retraction of the azygos vein. The esophagus is dissected all around the circumference in the supra-azygos region, and these planes are joined with those in the infra-azygos region, thus completely freeing the esophagus. This is confirmed by pulling the esophagus craniocaudally (shoeshine effect). The left recurrent nerve is identified in the tracheoesophageal groove. The nodes along this nerve are removed.

The esophageal dissection is carried cranially upto the root of the neck. An intercostal drainage tube is inserted through the working 10 mm port. The lung is inflated, and the camera port was removed under vision.

### Stage 2: Laparoscopic Gastric Mobilization

The patient is placed in a modified Lloyd-Davis 15 to 20 degrees head-up position. The surgeon stands between the legs of the patient, with the cameraman and one assistant on left, and with the second assistant and scrub nurse on the right. Five ports are used (Fig. 2).

Stomach mobilization is begun by opening the gastrocolic ligament and entering the lesser sac. The greater omentum is divided. The stomach is lifted from the pancreas by cutting the congenital bands. The fundus and entire stomach is pushed to the right side by the assistant rolling the fundus toward the right, and the gastrosplenic ligament is cut while the short gastric vessels are coagulated and cut. The hepatic flexure and transverse colon reflection are cut, and the colon

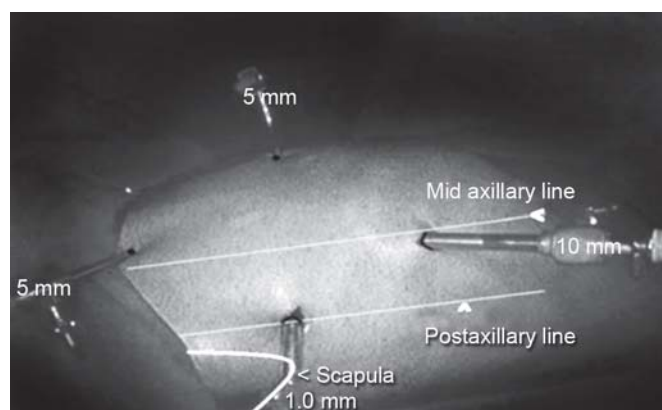


Fig. 1: Port position




Fig. 2: Alternative port position

is retracted caudally. This exposes the second part of duodenum, which is kocherized.

The left lobe of liver is retracted by the left assistant, and the gastrohepatic ligament is cut. The cut is extended upward to the lower end of the hiatus. The right crus of the diaphragm is identified, and the peritoneum over it is cut. This cut is extended up to the hiatus. The dissection is continued posteriorly until the left crus is identified. The esophagus is dissected all around at the level of hiatus.

All the nodes along the celiac trunk together with the common hepatic, splenic, and left gastric artery are removed. The left gastric artery and vein are clipped and cut. The hiatal opening is then widened.

### Stage 3: Cervicotomy and Esophagogastric Anastomosis

The patient is placed in the head-up position with the neck extended and turned toward the right. A left supraclavicular transverse incision is made. The two heads of the sternocleidomastoid are separated, exposing the carotid sheath together with internal jugular vein and common carotid artery. The inferior thyroid vein is ligated, and the vessels are retracted laterally to reach the prevertebral fascia. The esophagus is lifted from its posterior bed, and the dissection is continued posteriorly until the right lateral wall is reached. The esophagus is separated from the trachea and completely encircled.

Mobilization is confirmed by pulling the esophagus into the neck. The esophagus is divided by placing two stay sutures. The distal end is tied, and a nasogastric tube is tied to the distal end. The entire esophagus together with the nasogastric tube is pulled through the hiatus laparoscopically. A small abdominal incision is made at the level of camera port. The stomach and esophagus are delivered using a skin barrier. An extracorporeal stomach tube is prepared and pulled back through the posterior mediastinum into the neck, and an esophagogastric anastomosis is done in two layers. A feeding jejunostomy is established in all cases.

*Transhiatal esophagectomy:* The esophagus is mobilized *en bloc* together with the lymph nodes of lower mediastinum through the hiatus after transection of the diaphragm vein. During the transhiatal dissection, the right and left pleura must be visible, as well as the aorta dorsally, and the vena cava and pulmonary trunk ventrally. The dissection then is continued upto the aortic arch.

*Robotically-assisted laparoscopic esophagectomy:* Robotic technology provides more accuracy, a wider range of motion through articulated robotic wrists, finer tissue manipulation capability, and three-dimensional visualization.<sup>20-22</sup>

### OUTCOME

- Median operative time was 230 minutes (range of medians 180-400 minutes).<sup>9,10,14-42</sup>

- Conversion rate to open procedures was on an average 5.6% (0-36%).<sup>9,10,14-42</sup>
- Median ICU stay was 1.5 days (range 0.5-6).<sup>9,10,14-42</sup>
- Median hospital stay was 11.4 days (5.5-31).<sup>9,10,14-42</sup>
- Median blood loss was 190 ml.<sup>9,10,14-42</sup>
- Postoperative mortality was 2%.<sup>9,10,14-42</sup>
- The over-all complication rate was 41%.<sup>9,10,14-42</sup>
- Pulmonary complication rate was 20%.<sup>9,10,14-42</sup>
- Anastomotic leaks were reported in 8.7% (0-25%).<sup>9,10,14-42</sup>
- Vocal cord paralysis occurred in 1.5%.<sup>9,10,14-42</sup>
- Reoperations were reported in 6%, chylothorax 2%, 0.8% tracheobronchial tears or necrosis.<sup>9,10,14-42</sup>
- Incidences of splenectomies 0.3% and other visceral injuries (pancreas, colon) were low.<sup>9,10,14-42</sup>
- Oncological outcome of MIE: Median lymph nodes retrieval of all series was 14 nodes. Lower yields were reported after transhiatal than after transthoracic MIE.<sup>9,10,14-42</sup>
- Among the survival rate report studies, 1-year survival rate was of a median of 75%. Reported 3-year survival was 41%.<sup>9,10,14-42</sup>

Operative times, blood loss, transfusion requirements, ICU and hospital stays were shorter after MIE but without any difference in fistula rates. Smithers et al reported the largest available series of MIE, comparing 309 thorascopic-assisted esophagectomies with 23 totally MIE (laparoscopic and thorascopic) and 114 open esophagectomies during the same time period.<sup>42</sup> Their thorascopic resections were found to have marginal benefits over open resections, such as reduced blood loss (400 ml vs 600 ml), transfusion rates (27% vs 37%) and one day shorter hospital stay (13 days vs 14 days). The morbidity profile was similar for all three approaches except for a much higher stricture rate of anastomosis after MIE (22% vs 6%). Using a policy of standard mediastinal LND (including periesophageal and subcarinal but not upper mediastinal nodes), Smithers et al<sup>42</sup> retrieved a median of 17 lymph nodes. Others have shown that even more extended lymph node dissections can be performed by MIE and lead to excellent 5-year survival rates above 50%.

Pulmonary complications are the most frequent source of complications and mortality after an esophagectomy. Their reduction seems to be one of the aims of any MIE technique. The main pulmonary complications seen were pneumonia, pleural effusion, atelectasis, pulmonary embolism and assisted ventilation. All were much less in MIE. Other than respiratory complications, the classical complications of esophagectomy, such as anastomotic leaks and vocal cord palsy is more in MIE but not significantly high. Risk of tracheobronchial injuries thus seems to be increased compared to open resections.<sup>9,10,14-42</sup>

In MIE, postoperative ventilation time, blood loss, transfusion rates, length of ICU and hospital stays are less. Learning curve is high in MIE. Results of various studies show that as the number of cases done are increasing, the complications are decreasing.<sup>9,10,14-42</sup> Regarding the survival rate, it has been shown that earlier the stage better the survival. The 5-year survival reported by various studies were for stage I—83%, stage II—42% and stage III—16%.

## CONCLUSION

MIE has been gaining attractiveness since the first report nearly two decades ago. Like open surgery, several techniques exist including totally laparoscopic transhiatal or transthoracic resections as well as combination, or hybrid techniques. Much as with open esophageal surgery, no consensus has been reached regarding the superiority of any particular MIE adaptation. By reducing perioperative morbidity and recovery time, and by maintaining the oncological principles, MIE is a safe alternative for open procedures under experienced hands. Initial outcomes of the minimally invasive approach appear to be at least equivalent, and the promise of potential benefits a tangible possibility.

## REFERENCES

- Kamangar F, Dores GM, Anderson WF. Patterns of cancer incidence, mortality, and prevalence across five continents: Defining priorities to reduce cancer disparities in different geographic regions of the world. *J Clin Oncol* 2006;24:2137-50.
- Jemal A, Siegel R, Ward E, et al. Cancer statistics, 2007. *CA Cancer J Clin* 2007;57:43-66.
- Kelsen DP, Ginsberg R, Pajak TF, et al. Chemotherapy followed by surgery compared with surgery alone for localized esophageal cancer. *N Engl J Med* 1998;339:1979-84.
- Bosset JF, Gignoux M, Triboulet JP, et al. Chemoradiotherapy followed by surgery compared with surgery alone in squamous cell cancer of the esophagus. *N Engl J Med* 1997;337:161-67.
- Cushieri A, Shimi S, Banting S. Endoscopic oesophagectomy through a right thoracoscopic approach. *JR Coll Surg Edinb* 1992;37:7-11.
- De Paula AL, Hashiba K, Ferreira EA, de Paula RA, Grecco E. Laparoscopic transhiatal esophagectomy with esophagogastric anastomosis. *Surg Laparosc Endosc* 1995;5:1-5.
- Swanstrom LL, Hansen P. Laparoscopic total esophagectomy. *Arch Surg* 1997;132:943-47, discussion 947-49.
- Jamieson GG, Mathew G, Ludemann R, Wayman J, Myers JC, Devitt PG. Postoperative mortality following esophagectomy and problems in reporting its rate. *Br J Surg* 2004;91:943-47.
- Luketich JD, Alveloriviera M, Buenaventura PO, Christie NA, McCaughan JS, Litle VR, Schauer PR, Close JM, Fernando HC. Minimal invasive esophagectomy: Outcomes in 222 patients. *Ann Surg* 2003;238:486-95.
- Luketich JD, Landreneau RJ. Minimally invasive resection and mechanical cervical esophagogastric anastomotic techniques in the management of esophageal cancer. *J Gastroint Surg* 2004;8:927-29.
- Wu PC, Posner MC. The role of surgery in the management of oesophageal cancer. *Lancet Oncol* 2003;4:481-88.
- Orringer MB, Marshall B, Iannettoni MD. Eliminating the cervical esophagogastric anastomotic leak with a side-to-side stapled anastomosis. *J Thorac Cardiovasc Surg* 2000;119:277-88.
- Lerut T, Coosemans W, De Leyn P, et al. Reflections on three field lymphadenectomy in carcinoma of the esophagus and gastroesophageal junction. *Hepatogastroenterology* 1999;46:717-25.
- Collard JM, Lengele B, Otte JB, Kestens PJ. En bloc and standard esophagectomies by thoracoscopy. *Ann Thorac Surg* 1993;56:675-79.
- Martin DJ, Bessell JR, Chew A, Watson DI. Thoracoscopic and laparoscopic esophagectomy: Initial experience and outcomes. *Surg Endosc* 2005;19:1597-1601.
- Suzuki Y, Urashima M, Ishibashi Y, et al. Hand-assisted laparoscopic and thoracoscopic surgery (HALTS) in radical esophagectomy with three-field lymphadenectomy for thoracic esophageal cancer. *Eur J Surg Oncol* 2005;31:1166-74.
- Palanivelu C, Prakash A, Senthikumar R, et al. Minimally invasive esophagectomy: Thoracoscopic mobilization of the esophagus and mediastinal lymphadenectomy in prone position—experience of 130 patients. *J Am Coll Surg* 2006;203:7-16.
- Buess G, Kaiser J, Manneke K, et al. Endoscopic microsurgical dissection of the esophagus (EMDE). *Int Surg* 1997;82:109-12.
- Bonavina L, Incarbone R, Bona D, Peracchia A. Esophagectomy via laparoscopy and transmediastinal endodissection. *J Laparoendosc Adv Surg Tech A* 2004;14:13-16.
- Galvani CA, Gorodner MV, Moser F, et al. Robotically assisted laparoscopic transhiatal esophagectomy. *Surg Endosc* 2008;22:188-95.
- Horgan S, Berger RA, Elli EF, Espat NJ. Robotic-assisted minimally invasive transhiatal esophagectomy. *Am Surg* 2003;69:624-26.
- Espat NJ, Jacobsen G, Horgan S, Donahue P. Minimally invasive treatment of esophageal cancer: Laparoscopic staging to robotic esophagectomy. *Cancer J* 2005;11:10-17.
- GB Cadie're, R Torres, G Dapri, E Capelluto, B Hainaux, J Himpens. Thoracoscopic and laparoscopic oesophagectomy improves the quality of extended lymphadenectomy *Surg Endosc* 2006;20:1308-09.
- Kyle A, Perry C, Kristian Enestvedt, Brian S, Diggs AE, Blair A, Jobe, John G Hunter. Perioperative outcomes of laparoscopic transhiatal inversion esophagectomy compare favorably with those of combined thoracoscopic-laparoscopic esophagectomy *Surg Endosc* 2009;23:2147-54.
- R Costi, J Himpens, J Bruyns, GB Cadie're. Totally laparoscopic transhiatal esophago-gastrectomy without thoracic or cervical access. *Surg Endosc* 2004;18:629-32.
- Renam Tinoco, Luciana El-Kadre, Augusto Tinoco, Rodrigo Rios, Daniela Sueth, Felipe Pena. Laparoscopic transhiatal esophagectomy: Outcomes. *Surg Endosc* 2007;21:1284-87.
- Ahmed H, Hamouda Matthew J, Forshaw Kostas Tsigritis Greg E, Jones Aliya S, Noorani Ash Rohatgi Abraham J. Botha Perioperative outcomes after transition from conventional to minimally invasive Ivor-Lewis esophagectomy in a specialized center *Surg Endosc* 2010;24:865-69.
- DI Watson, N Davies, Jamieson GG. Totally endoscopic Ivor Lewis esophagectomy. *Surg Endosc* 1999;13:293-97.
- I Braghetto, A Csendes, G Cardemil, P Burdiles, O Korn, H Valladares. Open transthoracic or transhiatal esophagectomy versus minimally invasive esophagectomy in terms of morbidity, mortality and survival. *Surg Endosc* 2006;20:1681-86.

30. KH Kernstine, DT DeArmond, DM Shamoun, JH Campos. The first series of completely robotic esophagectomies with three-field lymphadenectomy: Initial experience. *Surg Endosc* 2007;21:2285-92.
31. Shailesh P, Puntambekar Geetanjali A, Agarwal Saurabh N, Joshi Neeraj V, Rayate Ravindra M, Sathe Anjali Patil M. Thoracoscopic laparoscopy in the lateral position for esophageal cancer: The experience of a single institution with 112 consecutive patients. *Surg Endosc* 14 January 2010.
32. Grant Sanders, Frederic Borie, Emanuel Husson, Pierre Marie Blanc, Gianluca Di Mauro, Christiano Claus, Bertrand Millat. Minimally invasive transhiatal esophagectomy: Lessons learned. *Surg Endosc* 2007;21:1190-93.
33. A Tangoku, S Yoshino, T Abe, H Hayashi, T Satou, T Ueno, M Oka. Mediastinoscope-assisted transhiatal esophagectomy for esophageal cancer *Surg Endosc* 2004;18:383-89.
34. DJ Martin, JR Bessell, A Chew, DI Watson. Thoracoscopic and laparoscopic esophagectomy *Surg Endosc* 2005;19:1597-601.
35. G Collins, E Johnson, T Kroshus, R Ganz, 2K Batts, J Seng, O Nwaneri, D Dunn. Experience with minimally invasive esophagectomy. *Surg Endosc* 2006;20:298-301.
36. T Bottger, A Terzic, M Muller A. Rodehorst Minimally invasive transhiatal and transthoracic esophagectomy. *Surg Endosc* 2007;21:1695-700.
37. Sebastian F Schoppmann, Gerhard Prager, Felix B Langer, Franz M Riegler, Barbara Kabon, Edith Fleischmann, Johannes Zacherl. Open versus minimally invasive esophagectomy: A single center case controlled study. *Surg Endosc* 2 April 2010.
38. Christy M Dunst, Lee L Swanström. Minimally Invasive Esophagectomy *Gastrointest. Surg* (2010) 14 (Suppl 1): S108-14.
39. Rajeev Parameswaran, Darmarajah Veeramootoo, Rakesh Krishnadas, Martin Cooper, Richard Berrisford, Shahjehan Wajed. Comparative Experience of Open and Minimally Invasive Esophagogastric Resection *World J Surg* 2009;33:1868-75.
40. Urs Zingg, Alexander McQuinn, Dennis DiValentino, Adrian J Esterman, Justin R Bessell, Sarah K Thompson, Glyn G Jamieson, David I. Minimally Invasive versus Open Esophagectomy for Patients with Oesophageal cancer. *Ann Thorac Surg* 2009;87:911-19.
41. Nguyen NT, Follette DM, Wolfe BM, Schneider PD, Roberts P, Goodnight JE. Comparison of minimally invasive esophagectomy with transthoracic and transhiatal esophagectomy. *Arch Surg* 2000;135:920-25.
42. Smithers BM, Gotley DC, Martin I, Thomas JM. Comparison of the outcomes between open and minimally invasive esophagectomy. *Ann Surg* 2007;245:232-40.



For article:

**Joseph A. Role of minimal access techniques in tubal factor infertility. World J Laparoscopic Surg 2011;4(1):59-66.**

### RETRACTION NOTICE

It has been notified to the **Editorial Board, World Journal of Laparoscopic Surgery (WJOLS)**, that considerable script of the aforementioned article has been plagiarized from the article:

**Patil M. Assessing tubal damage. J Hum Reprod Sci 2009;2:2-11.**

The same was confirmed after thorough evaluation and interpretation. In accordance to observe serious view in case of plagiarism, the **Editorial Board, WJOLS** decided to take appropriate action against the act.

Thus, it is herewith decided by the **Editorial Board, WJOLS** to retract the title as addressed from the assigned issue.

# Comparison of Advantages and Disadvantages between SILS and NOTES

Sarat Chandra Jayasingh

Assistant Surgeon, Department of Surgical Gastroenterology, SCB Medical College, Cuttack, Orissa, India

## ABSTRACT

Minimal access surgery is the gold standard for several abdominopelvic procedures in the present era. The prime advantage with minimal access surgery is the minimal surgical trauma in comparison to the conventional surgery. The other advantages of laparoscopy like less operative time, less pain, early recovery and return to work and above all better cosmetics have been well proven. "Change is constant in life," SILS and NOTES are the two newly emerging novel techniques in laparoscopy. SILS is a new advancement in laparoscopy, where the whole surgery is conducted through a single umbilical incision whereas NOTES is totally incisionless. In real sense, the incision in NOTES is not externally visible because of the natural orifices like oral cavity, vagina, urethra and anus that are used as entry sites. SILS have the advantages of better cosmetics, less blood loss, faster recovery, less complications, early return to work, versatility, better patient acceptance and easy tissue retrieval, etc. The critics are high cost, need of high expertise and more chances of port site hernia and infection. Similarly, NOTES has its edges over traditional laparoscopy surgery with the advantages of highest cosmetic value (no visible scar), less pain, requirement of less immunosuppressant and less anesthesia, faster recovery, and no external wound complications (hernia, hematoma and abscess). But it has also its own critics like questionable safety, unproven data about complications, requirement of high expertise, low patient acceptance, requirement of advanced endoscopic instruments, difficulty in closing internal wounds, intraperitoneal infection, gastrointestinal fistula and high cost. Poor acceptance is a major concern for NOTES.

**Aims:** To explore the positive and negative aspects of above two procedures in order to find out the better option.

**Keywords:** SILS—single incision laparoscopic surgery, Natural orifice transluminal endoscopic surgery (NOTES).

## SINGLE INCISION LAPAROSCOPIC SURGERY (SILS)

SILS is an innovative advancement in the field of minimal access surgery in which the surgeon operates exclusively through a single entry point, typically the umbilicus. It was performed in 2005 for acute appendicitis in department of pediatric surgery in Turkey. Since then, it has been appreciated and accepted all over the world and every laparoscopic surgeon today feels incomplete without a proper knowledge and understanding of SILS. There are different names for SILS like SPA—single port access, LESS—laparoendoscopic single site surgery, OPUS—one port umbilical surgery, SPICES—single port incision less conventional equipment using surgery, NOTUS—natural orifice transumbilical surgery, E-NOTES—embryonic natural orifice transumbilical surgery. SILS can be performed by many methods like:

- i. With multiple facial punctures through single skin incision.
- ii. By using additional transabdominal sutures for stabilization of target organ.
- iii. By using novel port access devices.

### Access Ports (Figs 1 and 2)

- a. SILS port from Covedien
- b. GelPort system from applied medical

- c. ASC R-port, Ireland
- d. Unix-X from Pnavel concepts.

### Hand Instruments (Fig. 3)

- a. Standard conventional laparoscopic hand instruments
- b. Articulating hand instruments:
  - i. Cambridge endomaneuvres autonomy laparoangle articulating instruments.
  - ii. Novare surgical manufactures real hand instruments with angle locking.

A wide range of operations are now possible by SILS like appendectomy, cholecystectomy (Figs 4A to C), nephrectomy, hysterectomy, esophagoectomy, adrenalectomy, gastric bypass, fundoplication, hernia repair, splenectomy, colectomy, hepatic resection, cryoablation, tubal ligation, etc.

### Advantages of SILS

- a. Better cosmetics
- b. Less blood loss
- c. Faster recovery
- d. Less complications
- e. Early return to work
- f. Versatility
- g. Better patient acceptance
- h. Easy tissue retrieval.



Fig. 1: Different type of ports for single incision laparoscopic surgery



Fig. 2: Triport

### Disadvantages

- High cost (both trocars and hand instruments)
- Need of high expertise
- More chances of port site hernia and infection
- Longer operative time
- Technically difficult
- Mandatory port closure.

### NOTES

Like SILS, NOTES is also a recent innovative advancement in laparoscopic surgery in which incisionless laparoscopic procedure is possible with an endoscope equipped with hand instruments passed through a natural orifice (oral cavity, urethra, vagina and anus) than through an internal incision in the stomach, vagina (Fig. 5), urinary bladder or colon. Besides the isolated transgastric (Fig. 6), transvaginal,

transcolonic route, a combined transgastric and transvaginal approach for cholecystectomy has been performed in Portugal. NOTES was originally described in animals by Dr Anthoni Killoo from John Hopkin university. It was used for appendectomy in humans in India by Rao and Reddy and for cholecystectomy by Swanstorm in 2007. There are different ways to perform the operation like:

1. A single access multiport device with curved instruments.
2. Flexible operating endoscope with endoscopic tools.
3. Hybrid laparoscopy: Access with flexible endoscopic instruments with simultaneous abdominal access.
4. Combined multiple natural orifice access (transgastric + transvaginal).

The major advantage of NOTES is the highest cosmetic value because there is no externally visible scar after this procedure. There is less requirement of anesthesia and immunosuppressant besides less postoperative pain, faster recovery, early return to work and no abdominal wound complications like seroma, hematoma and abscess. Similarly, NOTES is not free from its own critics. For performing NOTES, highly sophisticated and expensive endoscopic as well as hand instruments (Fig. 7), a team of highly skilled and experienced surgeon and gynecologist are required. Another negative aspect is the unclear data regarding its safety, clinical outcome and postoperative complications.

### REVIEW OF SILS AND NOTES

There exists a number of techniques for performing SILS and NOTES. These can be adopted for different intra-abdominal and pelvic operations like appendectomy,<sup>2,4-6</sup> gastrostomy,<sup>7,8</sup> gastrectomy,<sup>9,10</sup> adrenalectomy,<sup>11</sup> colorectal procedures,<sup>12-15</sup> bariatric procedures<sup>9</sup> and urological

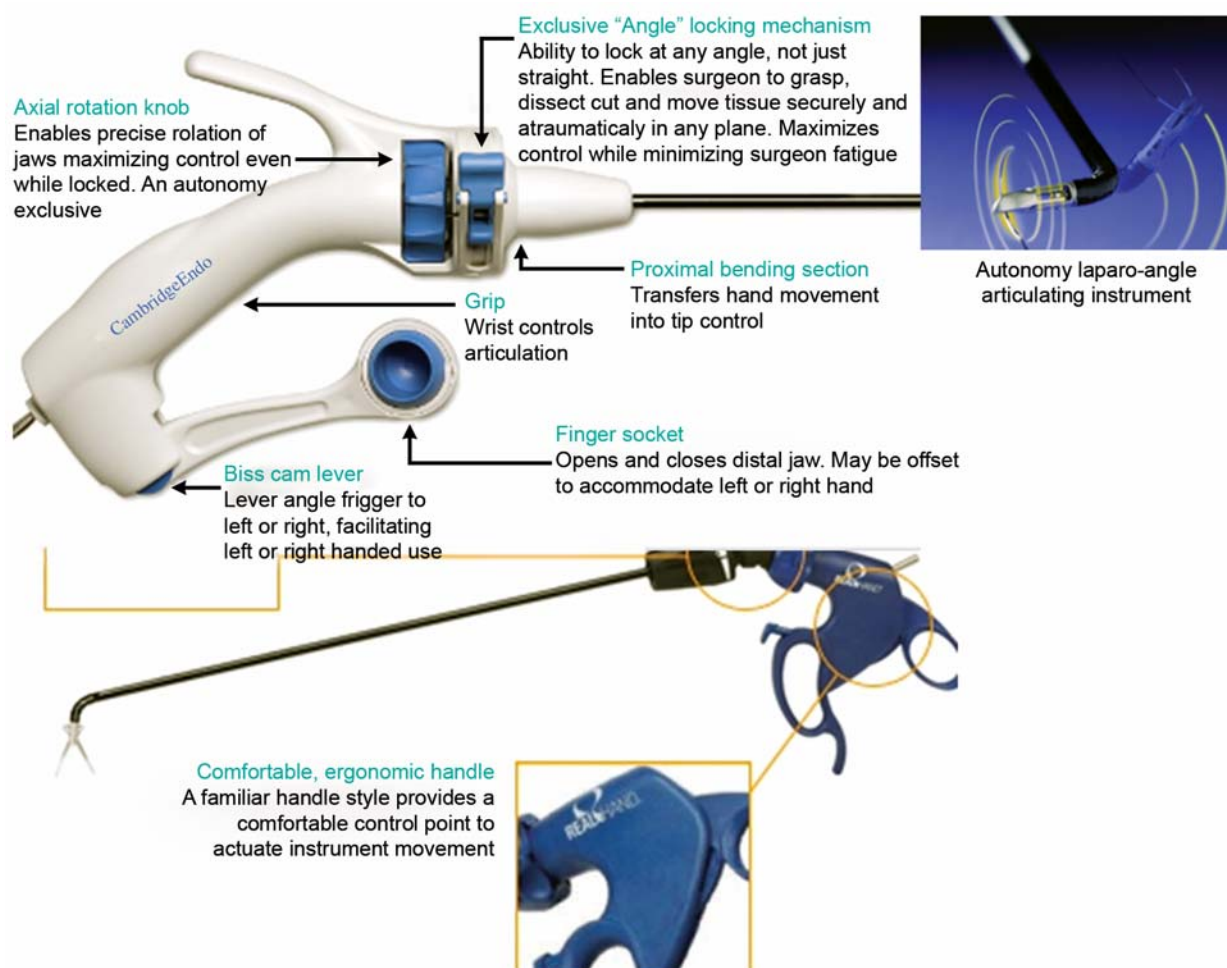
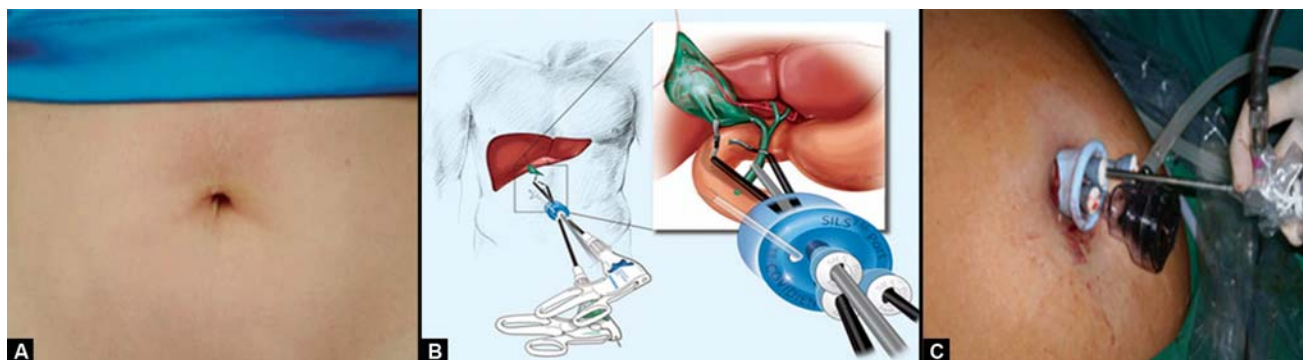


Fig. 3: Real hand instruments with angle locking



Figs 4A to C: SILS cholecystectomy

procedures.<sup>16,17</sup> But cholecystectomy is the most common procedure conducted through SILS and NOTES (Table 1).

### TECHNIQUE OF SILS CHOLECYSTECTOMY

First cholecystectomy by SILS was performed by Navara et al in 1997. He used two 10 mm trocars and three trans-abdominal stay sutures for the procedure.<sup>3</sup> Two years later in 1999, Piskun and Rajpal conducted the same procedure by using two 5 mm trocars and two stay sutures. In the above two procedures, both two umbilical trocars for telescope and hand instruments are used. Cuesta et al used

Kirschner's wire instead of stay sutures for retraction of Calot's triangle.<sup>19</sup> Average time taken for this surgery was 70 minutes.

Rao et al have conducted 20 SILS cholecystectomy using R-port, which consists of double layer plastic cylinder that serves as single port. It is introduced through 15 to 20 mm umbilical incision. The device has three valvular openings, which permit three 5 mm or one 10 mm and one 5 mm working instruments with angulated shafts. Surgery was performed successfully in 85% of cases with an average time of 30 minutes. TriPort is a similar device that has been

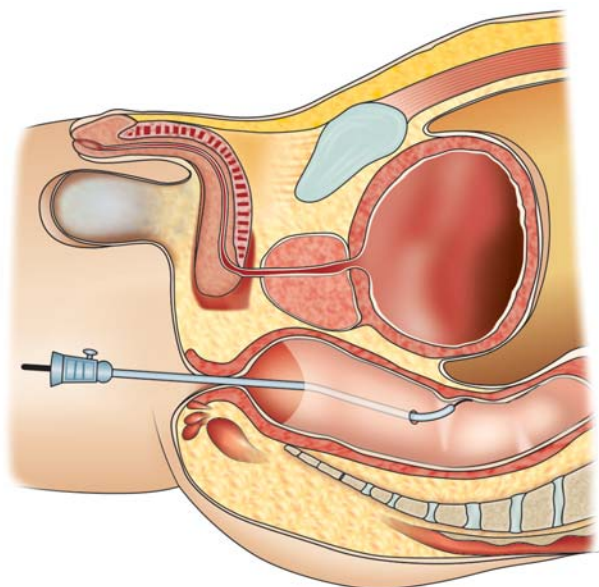


Fig. 5: Transvaginal NOTES

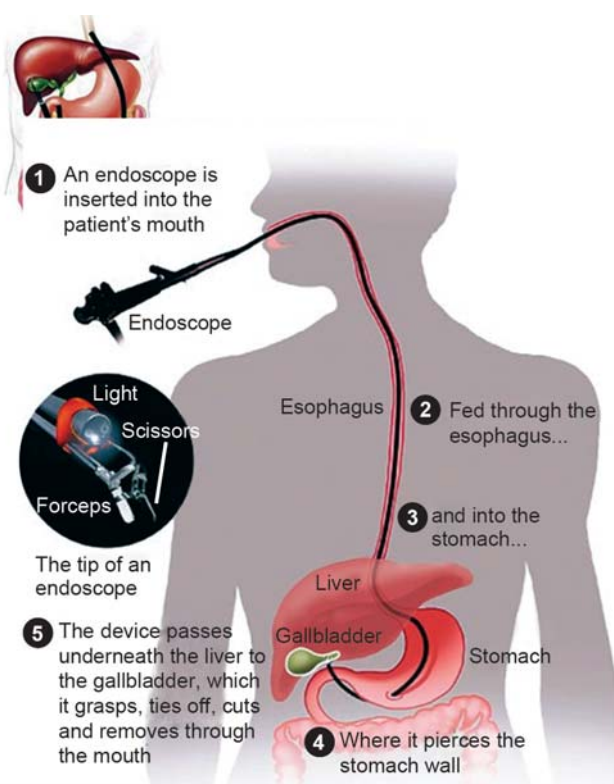


Fig. 6: Gallbladder removal through the mouth

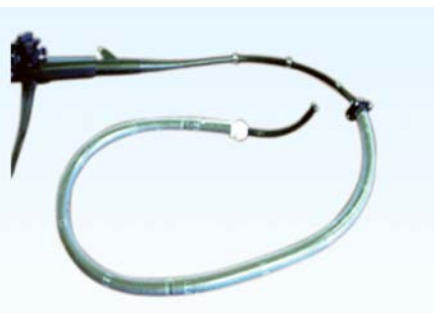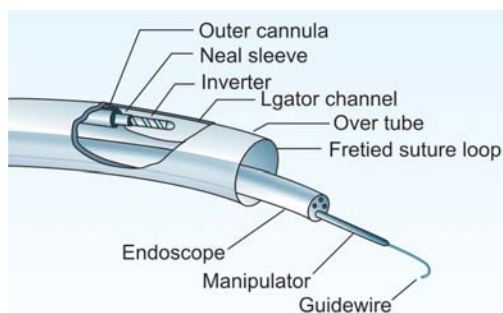


Fig. 7: NOTES instrument

used by Romanelle for SILS.<sup>20</sup> Merchant et al have used GelPort multichannel system, which allows four working instruments including the telescope.<sup>9</sup>

### TECHNIQUE OF NOTES CHOLECYSTECTOMY

Transvaginal laparoscopically-assisted cholecystectomy using a single 5 mm and two 3 mm trocars through the anterior abdominal wall has been described by Bessler. A 5 mm trocar was used for clip applicator and 3 mm trocars were used for gallbladder retraction and pneumoperitonium. A double channel flexible endoscope, which accommodates a grasper and hook knife was introduced transvaginally. The procedure took three and half hours. Marescaux et al used a similar technique with a 2 mm transumbilical needle for pneumoperitonium and laparoscopic-guided colpotomy.<sup>1</sup> Rest of the procedure was performed transvaginally over three hours.

A different technique by Zorning in which the umbilical scope was replaced by a dissector and a 10 mm 30 degrees scope was introduced transvaginally. With this technique, 20 cases were conducted with an average operating time of 62 minutes.

Forgione et al<sup>18</sup> described another technique in which a single incision is made in left upper quadrant for pneumoperitonium, colpotomy, retraction of gallbladder and clip application. The mean operating time was 136 minutes.

### DISCUSSIONS

After analysis of different literature about SILS and NOTES, it is presumed that there is probably better acceptance of SILS, although high cost and technical expertise are two important drawbacks. But for NOTES, patient acceptance and concerns about safety and complications are major drawbacks. Older and uneducated patients and those undergone upper GI endoscopy or colonoscopy in past are more likely to refuse for the procedure. It is still unproven whether NOTES has a real advantage over traditional laparoscopy and SILS or not. SILS offers better cosmetics by reducing the multiple incisions used in conventional laparoscopy to a single umbilical incision. Multiple laparoscopic procedures can be simultaneously performed

**Table 1:** Published reports of NOTES and SILS cholecystectomies through the years 1997–2009

Authors	Approach to peritoneal cavity	Number of skin incision(s)	Number of skin trocar(s)	Number of attempted cases	Diagnosis	Success rate (%)	Complication(s) Reasons for conversion to standard LC	Average operating time (minutes)
NOTES cholecystectomy								
Bessler et al <sup>21</sup>	Transabdominal, transvaginal	1	3	1	Cholelithiasis	100	None	210
Marescaux et al <sup>8</sup>	Transabdominal, transvaginal	1	1	1	Cholelithiasis	100	None	180
Zornig et al	Transabdominal, transvaginal	1	1	14	Cholelithiasis	100	None	62
Forgione et al	Transabdominal, transvaginal	1	1	3	Acute cholecystitis	100	None	136
				3	Chronic cholecystitis	67	Hepatic injury	
				3	Cholelithiasis	100	None	
SILS cholecystectomy								
Tacchino et al <sup>5</sup>	Transabdominal	1	3	10 2	Cholelithiasis Cholecystitis	83	None Subcutaneous – hematomas (I) – Hepatic injury (I)	55 ± 7
Cuesta et al	Transabdominal	1	2	10	Cholelithiasis	100	None	70
Rao et al	Transabdominal	1	1	18 2	Cholelithiasis Choledocholithiasis	94 0	Difficult dissection Choledochoscope for CBD exploration <sup>2</sup>	40
Merchant et al <sup>16</sup>	Transabdominal	1	1	19 2	Cholelithiasis Acute cholecystitis	100 50	None Difficult dissection	45-90
Zhu et al	Transabdominal	2	2	22 4	Cholelithiasis Gallbladder polyps	100 100	None None	30-150
Romanelli et al	Transabdominal	1	1	1	Cholelithiasis (history of pancreatitis)	100	None	68
Gumbs et al	Transabdominal	1	3	2	NR	100	None	< 60
Palanivelu et al	Transabdominal	2	2	10	Cholelithiasis	60	Hemorrhage from – Cystic artery <sup>2</sup> – Difficult dissection <sup>2</sup> – Bile leak <sup>1</sup>	148
Navarra et al <sup>10</sup>	Transabdominal	1	2	30	NR	100	None	123
Piskun et al	Transabdominal	1	2	7 3	Cholelithiasis Acute cholecystitis	100 100	None None	NR

by SILS because of a common entry point. At time of difficulty, it is easier to convert SILS to conventional laparoscopy without changing the patient's position. Short operating time, early recovery, early return to work, less blood loss, and better tissue retrieval are the positive aspects of SILS. The overall patient acceptance is better compared to NOTES and conventional laparoscopic surgery. A few drawbacks of SILS include high cost of access port and hand instruments, slightly extraoperative time, and highly skilled and experienced surgical team to overcome the technical difficulties. But as the learning curve gets over, all the negative factors except the cost are likely to be compensated.

The attractive part of NOTES is that it is totally incision less, for which its acceptance in young and educated patients is relatively higher than the older people. Today, NOTES can be used for both abdominal and mediastinal surgery. Elderly people with previous history of upper GI endoscopy or colonoscopy dislike NOTES because of their previous painful experience. Young females hesitate to accept surgical procedure through vaginal canal. Even in the educated mass with relatively high acceptance for

NOTES, explaining the safety and complication rate of the procedure is difficult. There is no clear data available till now regarding its after-effects on sexual life and infertility due to transvaginal surgery. The second negative aspect is the high cost of sophisticated instruments. The third obstacle is the necessity of a highly skilled multidisciplinary team. Conventional laparoscopy can be conducted with the help of inexperienced assistants (interns or nurses), whereas for NOTES a whole team of experienced surgeons and gynecologist is required. The fourth limiting factor is operation time. Conducting NOTES leads to consumption of more human hour in term of person and time. The fifth drawback is that it is not so easy like SILS for conversion to traditional laparoscopy. The sixth drawback is the lack of sterilization and secure closure of internal incision in stomach or colon. A gastrointestinal leak is the most unwanted catastrophic outcome of NOTES. The seventh drawback is learning curve and till now no clear data is available regarding its safety and complications. As per review of all the above literature, it is presumed that disadvantages of NOTES outweigh the no-incision benefit.

## CONCLUSION

SILS and NOTES are both promising. In the present scenario, SILS has a little edge over NOTES. According to literatures, SILS is more acceptable than NOTES because of the above described reasons.

## REFERENCES

1. Marescaux J, Dallemagne B, Perretta S, Wattiez A, Mutter D, Coumaros D. Surgery without scars: Report of transluminal cholecystectomy in a human being. *Arch Surg* 2007;142:823-26. doi:10.1001/archsurg.142.9.823.
2. Pelosi MA, Pelosi MA 3rd. Laparoscopic appendectomy using a single umbilical puncture (minilaparoscopy). *J Reprod Med* 1992;37:588-94.
3. Navarra G, Pozza E, Occhionorelli S, Carcoforo P, Donini I. One wound laparoscopic cholecystectomy. *Br J Surg* 1997;84:695. doi:10.1002/bjs.1800840536.
4. Esposito C. One-trocar appendectomy in pediatric surgery. *Surg Endosc* 1998;12:177-78. doi:10.1007/s004649900624.
5. Palanivelu C, Rajan PS, Rangarajan M, Parthasarathi R, Senthilnathan P, Prasad M. Transvaginal endoscopic appendectomy in humans: A unique approach to NOTES—worlds first report. *Surg Endosc* 2008;22:1343-47. doi:10.1007/s00464-008-9811-5.
6. Varshney S, Sewkani A, Vyas S, Sharma S, Kapoor S, Naik S, Purohit D. Single-port transumbilical laparoscopic-assisted appendectomy. *Indian J Gastroenterol*. 2007;26:192.
7. Ponsky TA, Lukish JR. Single site laparoscopic gastrostomy with a 4 mm bronchoscopic optical grasper. *J Pediatr Surg* 2008;43:412-14. doi:10.1016/j.jpedsurg.2007.11.009.
8. Karpelowsky J, Numanoglu A, Rode H. Single-port laparoscopic gastrostomy. *Eur J Pediatr Surg* 2008;18:285-86. doi:10.1055/s-2007-989325.
9. Merchant AM, Cook MW, White BC, Davis SS, Sweeney JF, Lin E. Transumbilical gelport access technique for performing single incision laparoscopic surgery (SILS). *J Gastrointest Surg* 2009;13:159-62. doi:10.1007/s11605-008-0737-y.
10. Saber AA, Elgamal MH, Itawi EA, Rao AJ. Single incision laparoscopic sleeve gastrectomy (SILS): A novel technique. *Obes Surg* 2008;18:1338-42. doi:10.1007/s11695-008-9646-0.
11. Hirano D, Minei S, Yamaguchi K, Yoshikawa T, Hachiya T, Yoshida T, Ishida H, Takimoto Y, Saitoh T, Kiyotaki S, Okada K. Retroperitoneoscopic adrenalectomy for adrenal tumors via a single large port. *J Endourol* 2005;19:788-92. doi:10.1089/end.2005.19.788.
12. Hellinger MD, Martinez SA, Parra-Davila E, Yeguez J, Sands LR. Gasless laparoscopic assisted intestinal stoma creation through a single incision. *Dis Colon Rectum* 1999;42:1228-31. doi:10.1007/BF02238581.
13. Remzi FH, Kirat HT, Kaouk JH, Geisler DP. Single-port laparoscopy in colorectal surgery. *Colorectal Dis* 2008;10:823-26. doi:10.1111/j.1463-1318.2008.01660.x.
14. Bucher P, Pugin F, Morel P. Single port access laparoscopic right hemicolectomy. *Int J Colorectal Dis* 2008;23:1013-16. doi:10.1007/s00384-008-0519-8.
15. Leroy J, Cahill RA, Peretta S, Marescaux J. Single port sigmoidectomy in an experimental model with survival. *Surg Innov* 2008;15:260-65. doi:10.1177/1553350608324509.
16. Kaouk JH, Palmer JS. Single-port laparoscopic surgery: Initial experience in children for varicocele. *BJU Int* 2008;102:97-99. doi:10.1111/j.1464-410X.2008.07584.x.
17. Desai MM, Aron M, Canes D, Fareed K, Carmona O, Haber GP, Crouzet S, Astigueta JC, Lopez R, de Andrade R, Stein RJ, Ulchaker J, Sotelo R, Gill IS. Single-port transvesical simple prostatectomy: Initial clinical report. *Urology* 2008; 72:960-65.
18. Zornig C, Emmermann A, von Waldenfels HA, Mofid H. Laparoscopic cholecystectomy without visible scar: Combined transvaginal and transumbilical approach. *Endoscopy* 2007;39:913-515. doi:10.1055/s-2007-966911.
19. Zornig C, Mofid H, Emmermann A, Alm M, von Waldenfels HA, Felixmüller C. Scarless cholecystectomy with combined transvaginal and transumbilical approach in a series of 20 patients. *Surg Endosc*. 2008;22:1427-29. doi:10.1007/s00464-008-9891-92.
20. Cuesta MA, Berends F, Veenhof AA. The “invisible cholecystectomy”: A transumbilical laparoscopic operation without a scar. *Surg Endosc* 2008;22:1211-13. doi:10.1007/s00464-007-9588-y.
21. Palanivelu C, Rajan PS, Rangarajan M, Parthasarathi R, Senthilnathan P, Praveenraj. Transumbilical flexible endoscopic cholecystectomy in humans: First feasibility study using a hybrid technique. *Endoscopy* 2008;40:428-31. doi:10.1055/s-2007-995742.